

# Treatment of LAD CTO by Retrograde Technique



北京大学第一医院  
PEKING UNIVERSITY FIRST HOSPITAL

**Jianping Li MD, Yanjun Gong MD**

**Peking University First Hospital**

**Beijing, China**

# Disclosure

➤ **Nothing to disclose.**



北京大学第一医院  
PEKING UNIVERSITY FIRST HOSPITAL



# Medical History

- **47 yrs/Chinese/male**
- **Paroxysmal chest pain for 5 yrs first during exercise and then at rest. Symptoms deteriorate for 3d.**
- **Risk factors:**
  - **T2 DM 10yrs, poorly controlled**
  - **Smoking 30yrs, 40 cigarettes a day**
  - **Mother: T2DM and myocardial infarction**



# Lab Results

- **Glu 9.46mmol/L, GHbA1c 8.4%**
- **TG1.71mmol/L, TC6.07mmol/L, HDL-C0.94mmol/L, LDL-C4.31mmol/L**
- **e-GFR133ml/min**
- **Troponin I (—)**
- **hsCRP25.47mg/L (0-3)**

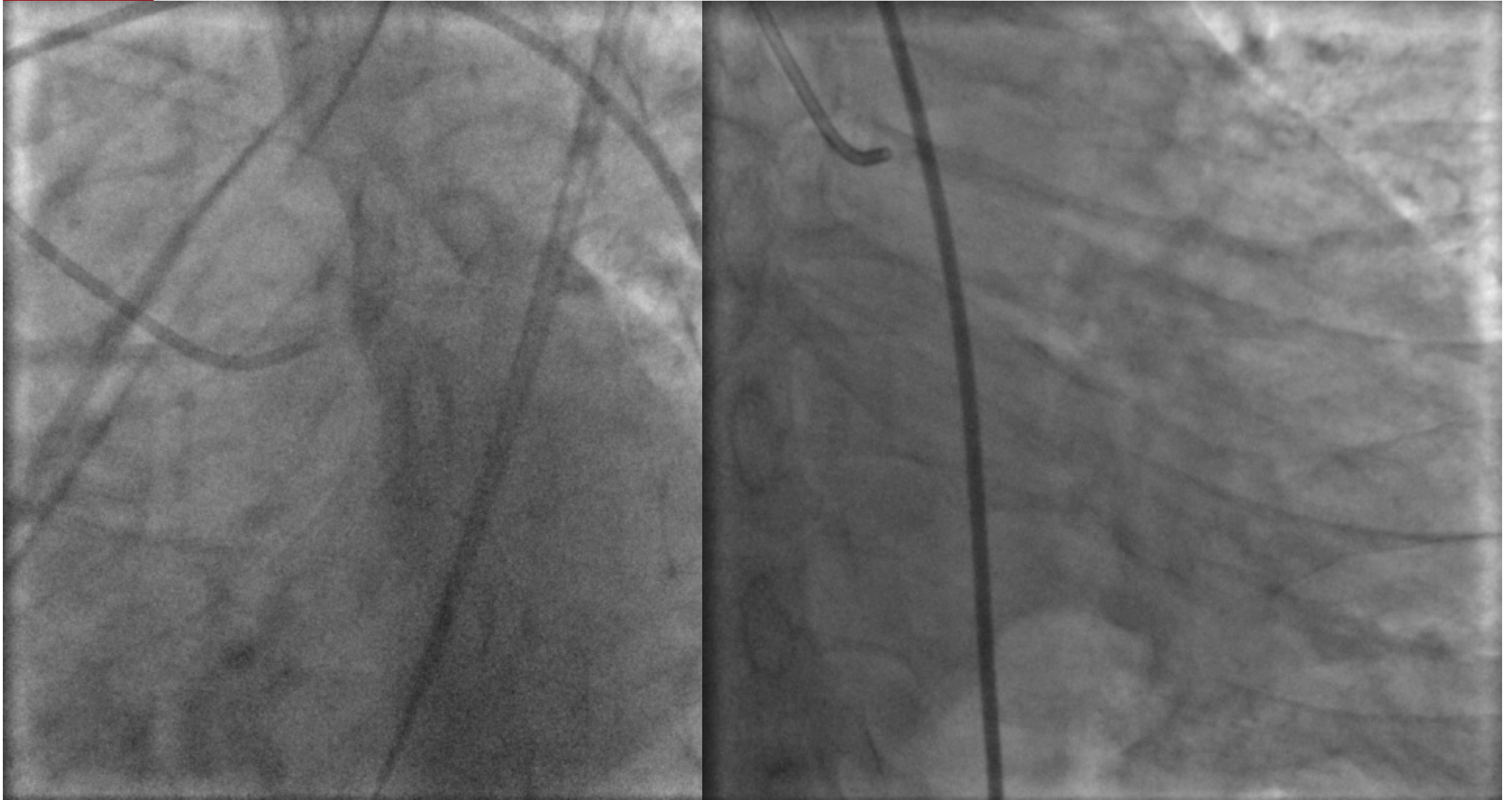

# Lab Results

- ▶ **X-ray, ECG was normal (without symptom)**
- ▶ **UCG : Chamber size is normal and wall motion is normal, LVEF70%**



**CAG**

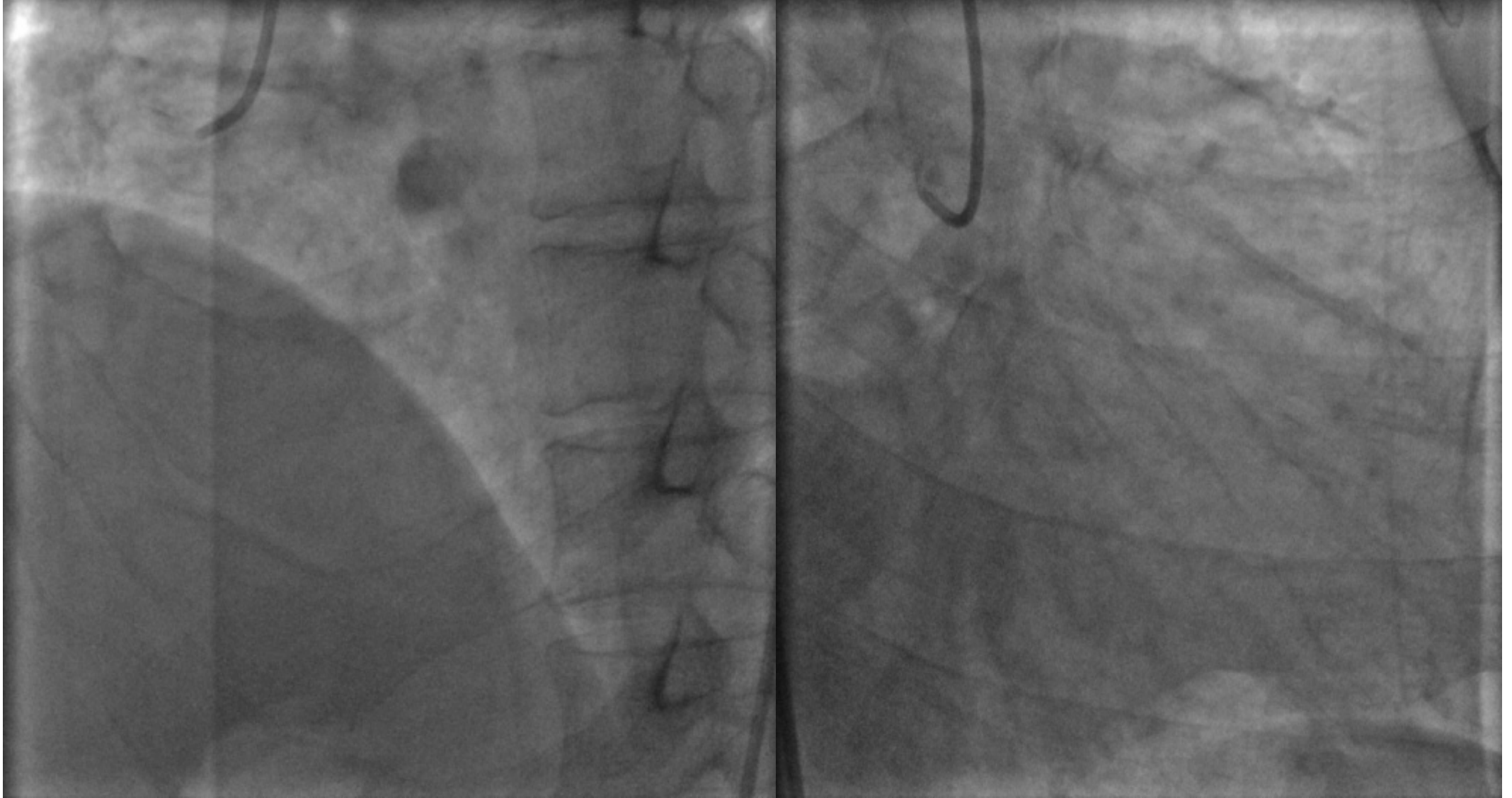

**LCA**





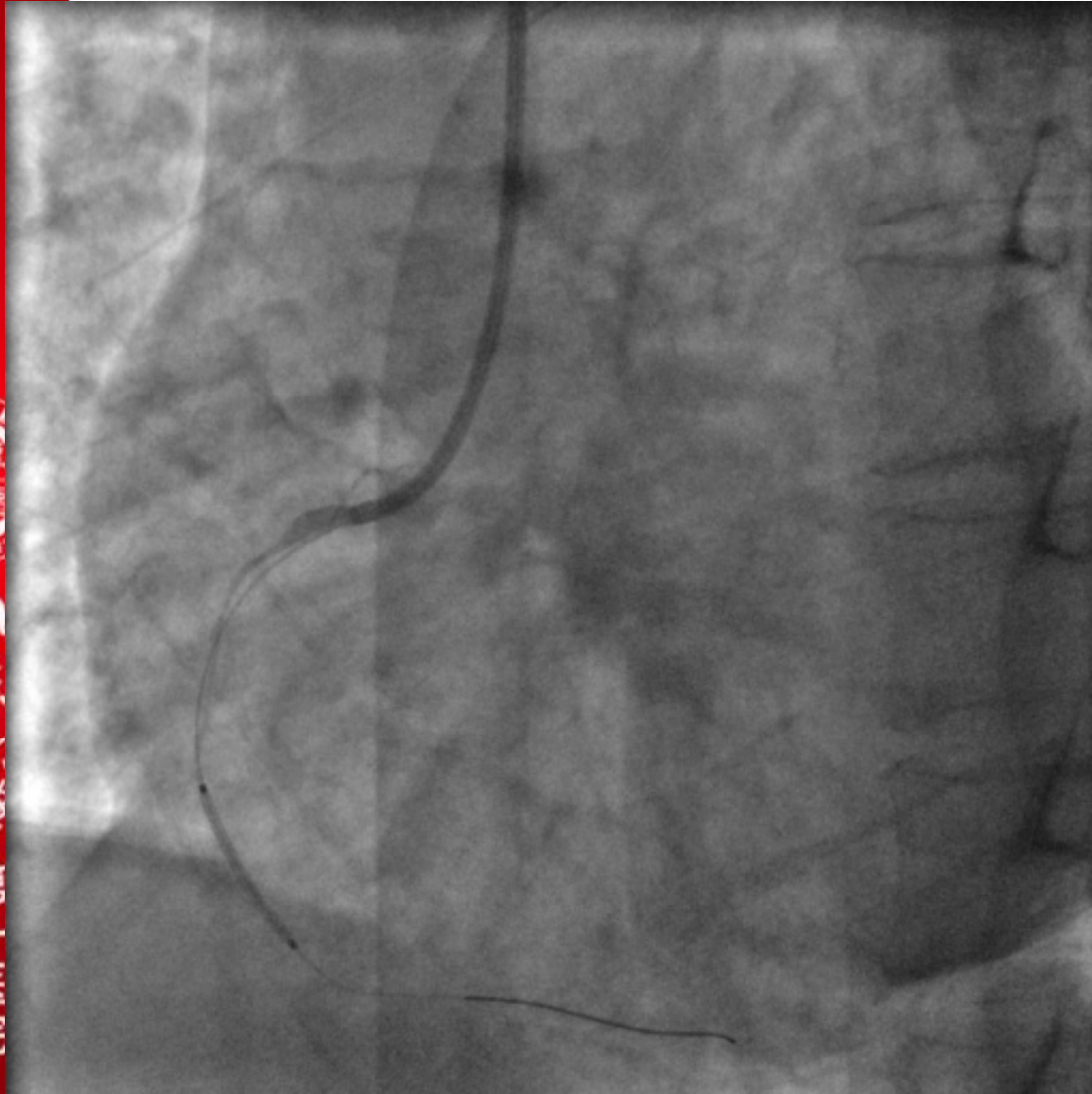
**CAG**



**RCA**



# PCI-RCA



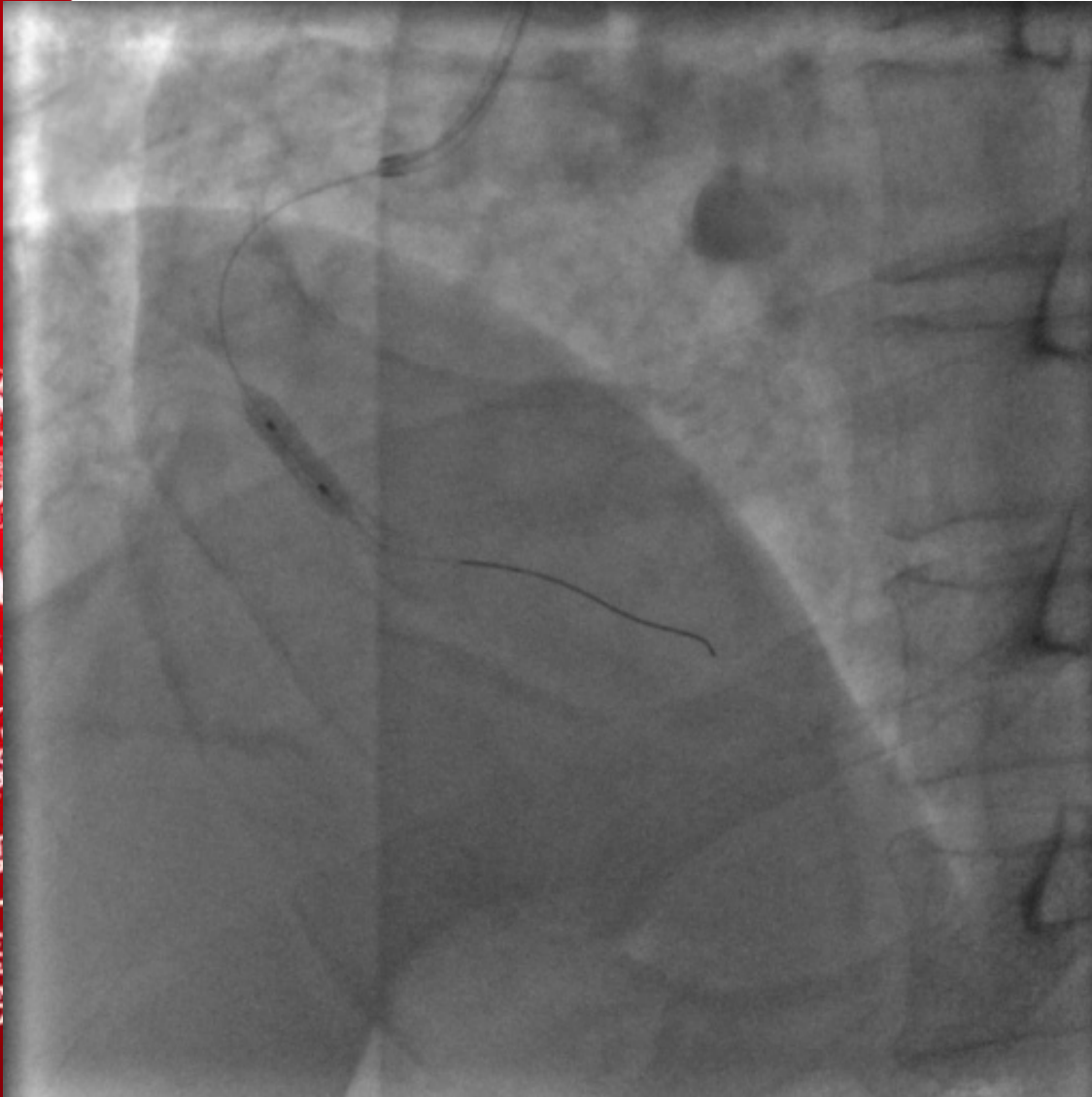
**GC: 6F JR4**  
**GW: Rinato**  
**Direct stenting:**  
**Endeavor Sprinter 3.5\*18mm**



北京大学第一医院  
PEKING UNIVERSITY FIRST HOSPITAL



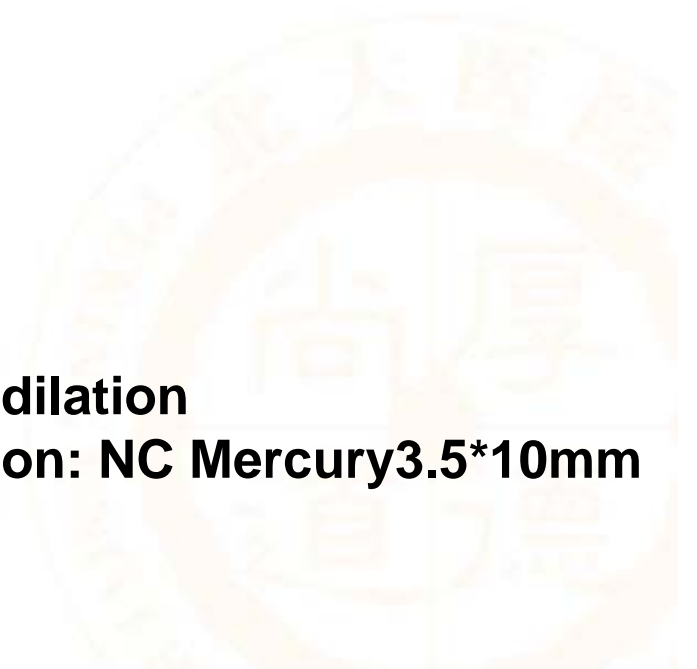# PCI-RCA



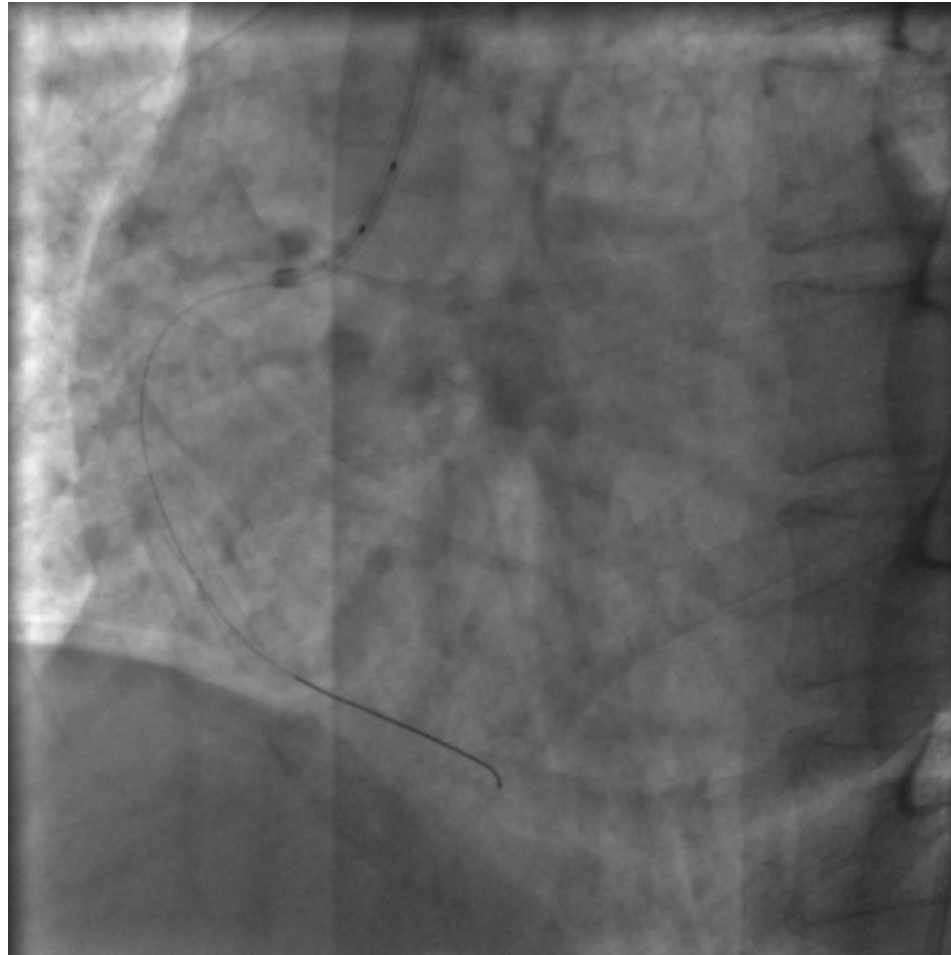
**Post dilation**  
**Balloon: NC Mercury 3.5\*10mm**



北京大学第一医院  
PEKING UNIVERSITY FIRST HOSPITAL



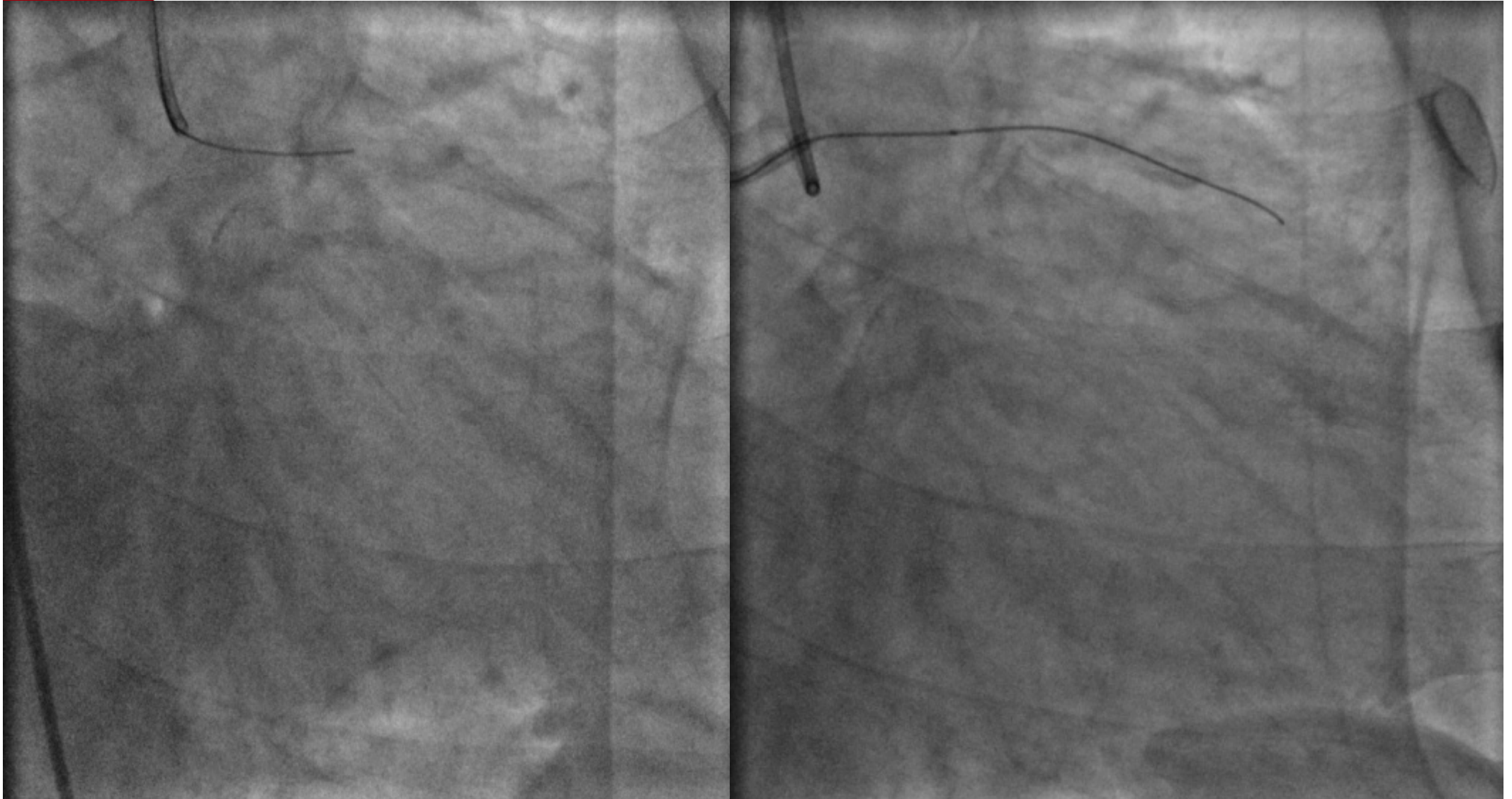
# PCI-RCA



北京大学第一医院  
PEKING UNIVERSITY FIRST HOSPITAL

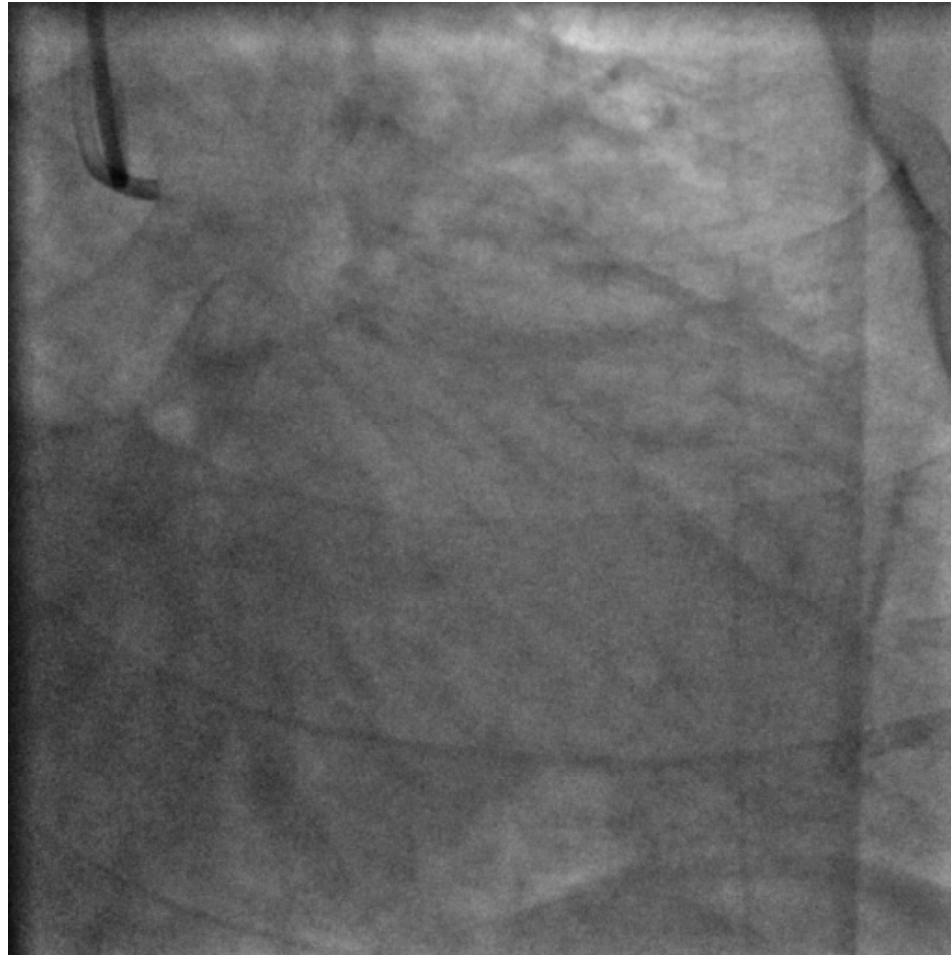

# PCI-LAD



GC 6F EBU3.75; GW Miracle4.5  
Balloon Sprinter1.5\*15mm

# PCI-LAD

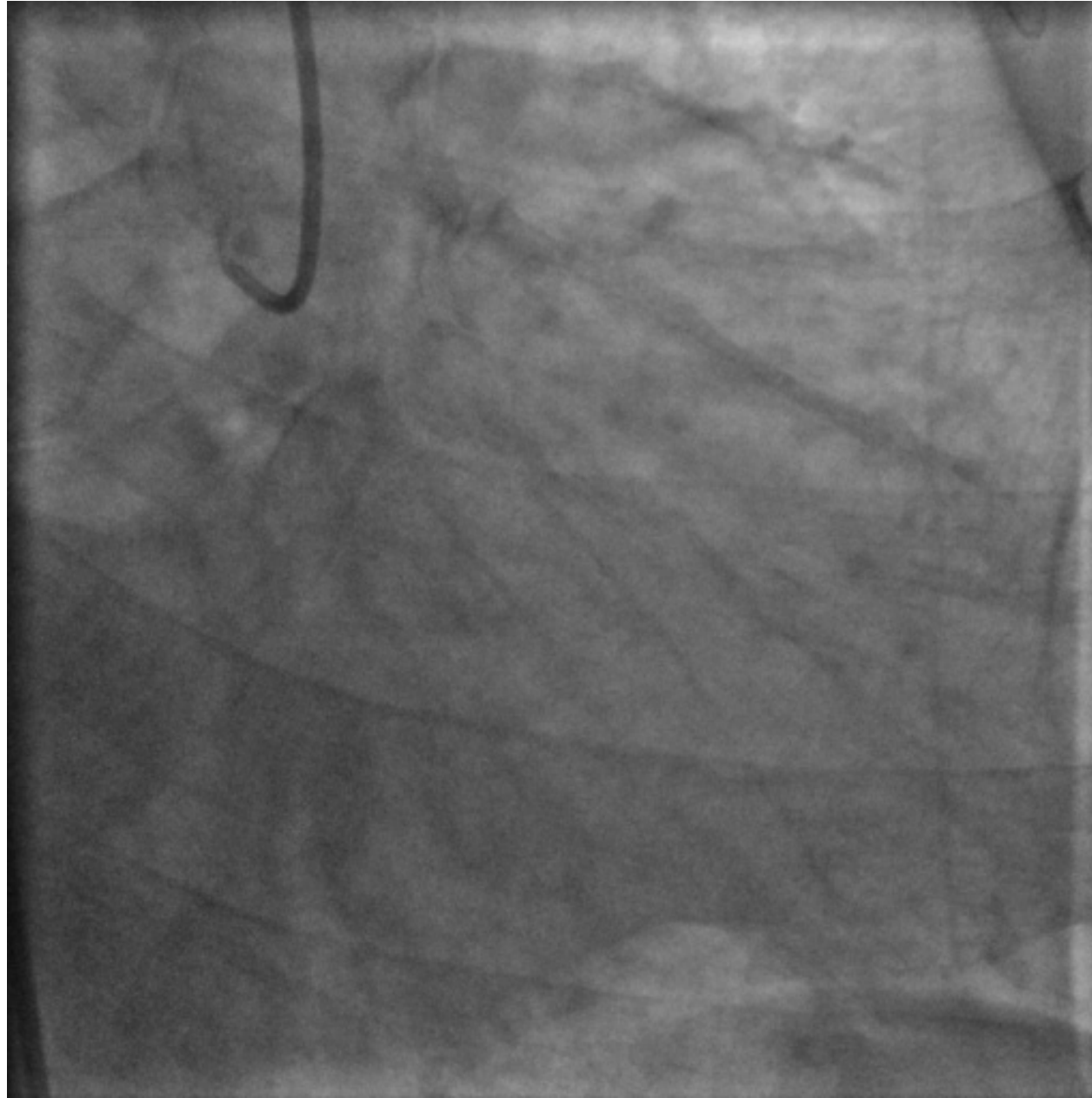

北京大学第一医院  
PEKING UNIVERSITY FIRST HOSPITAL



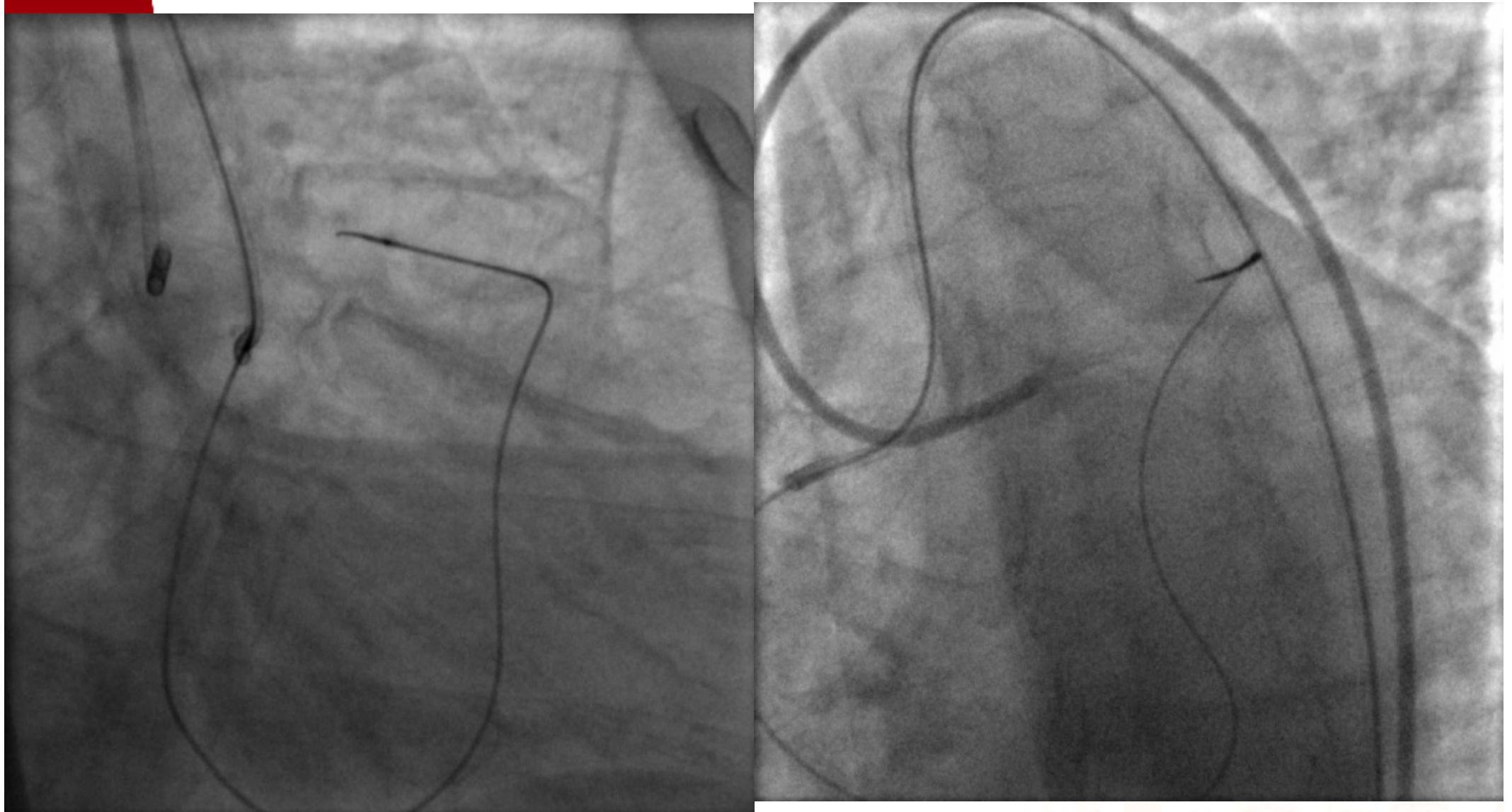


# PCI 2 weeks later



北京大学第一医院  
PEKING UNIVERSITY FIRST HOSPITAL

# PCI 2 weeks later

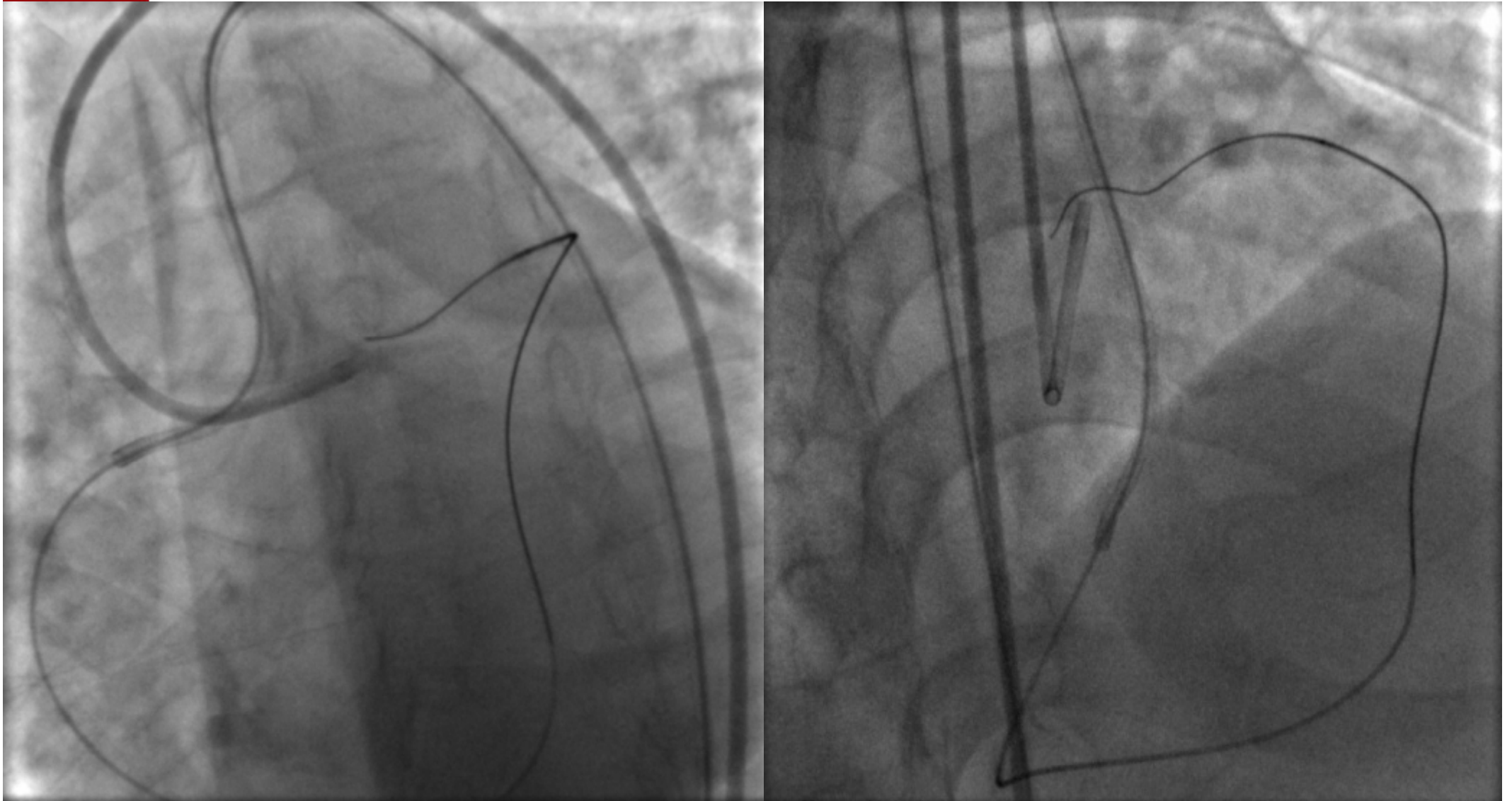


**GC: LCA--7FEBU3.75**

**RCA--7FAL1**

**Fielder FC on FINECROSS**

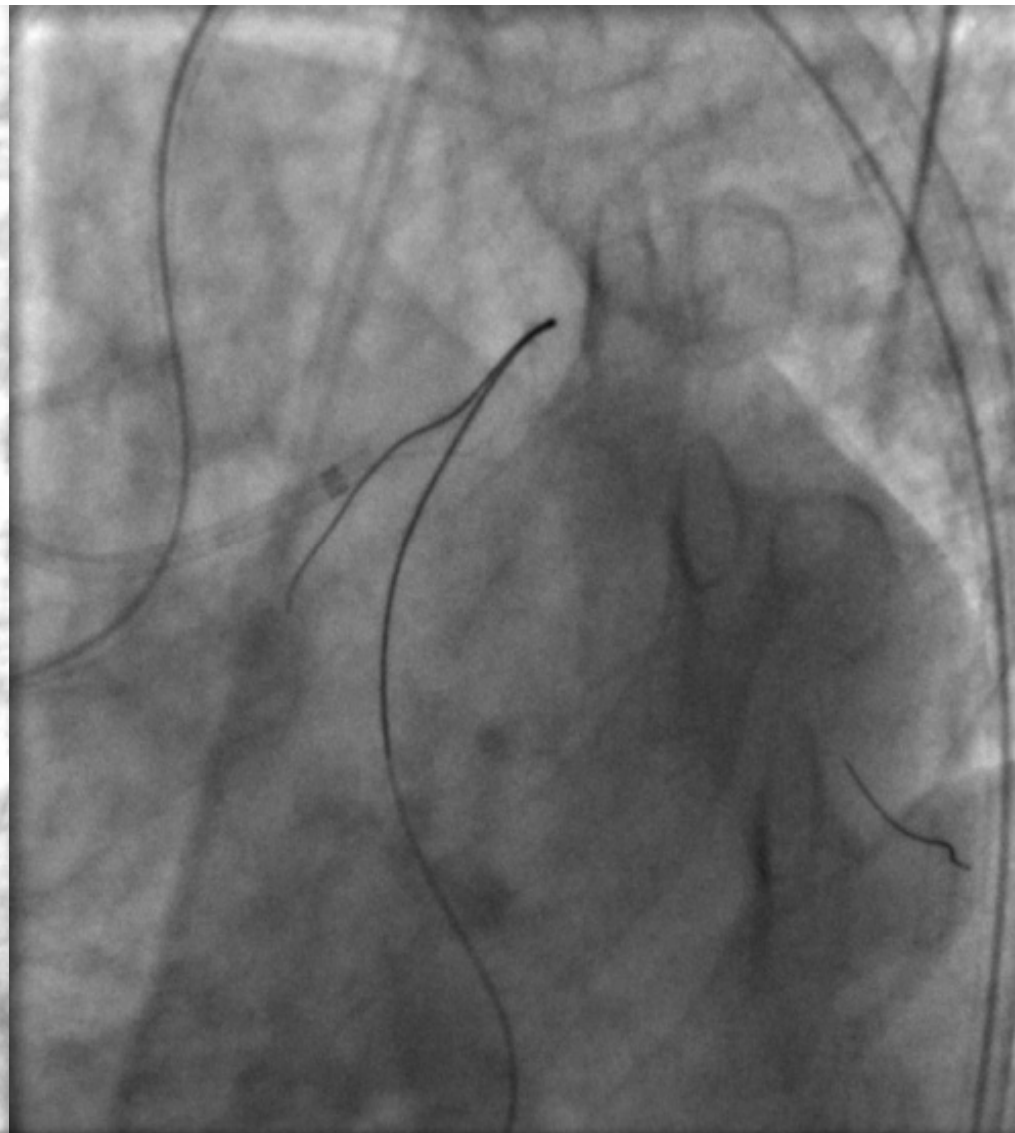
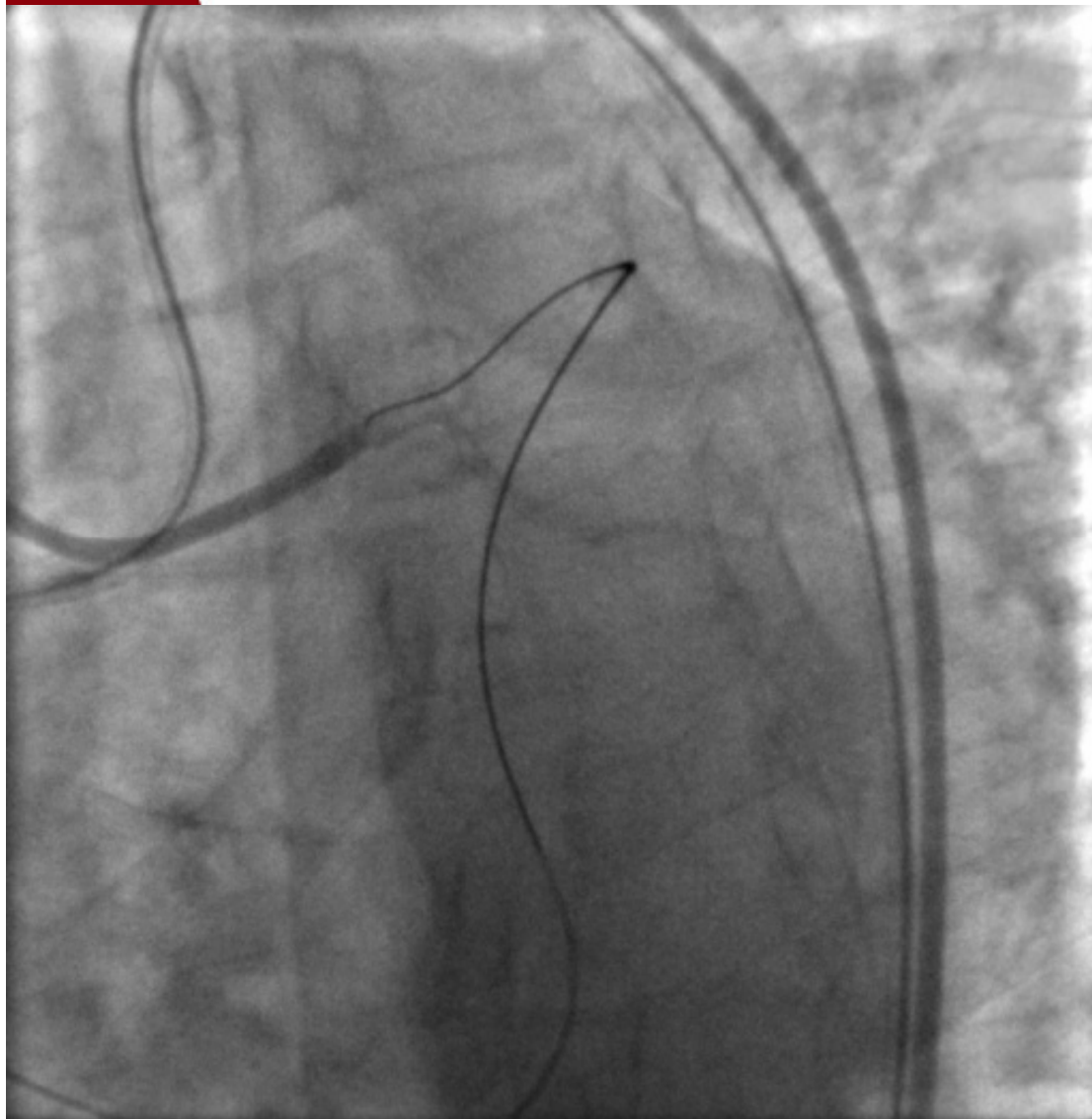




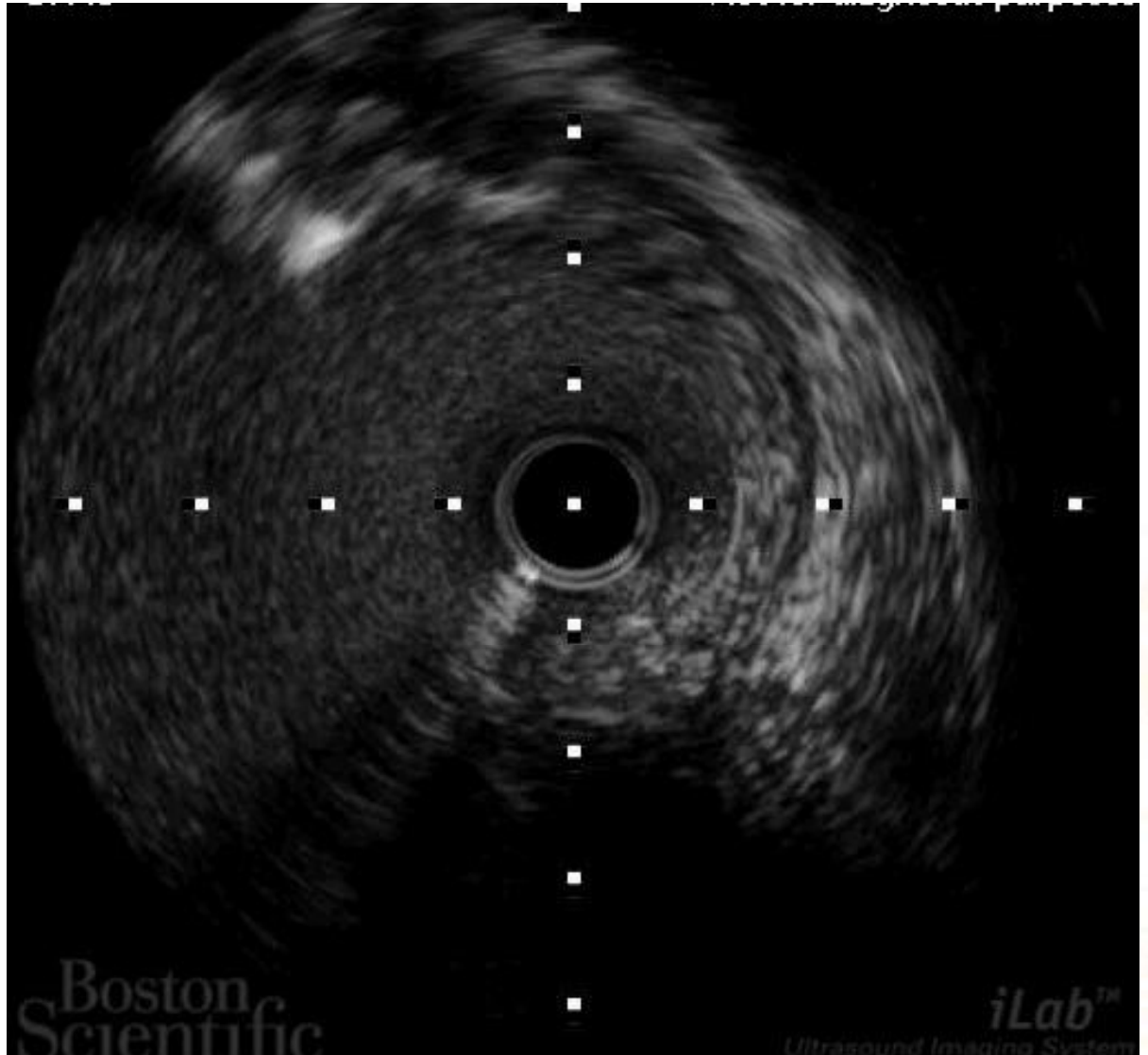
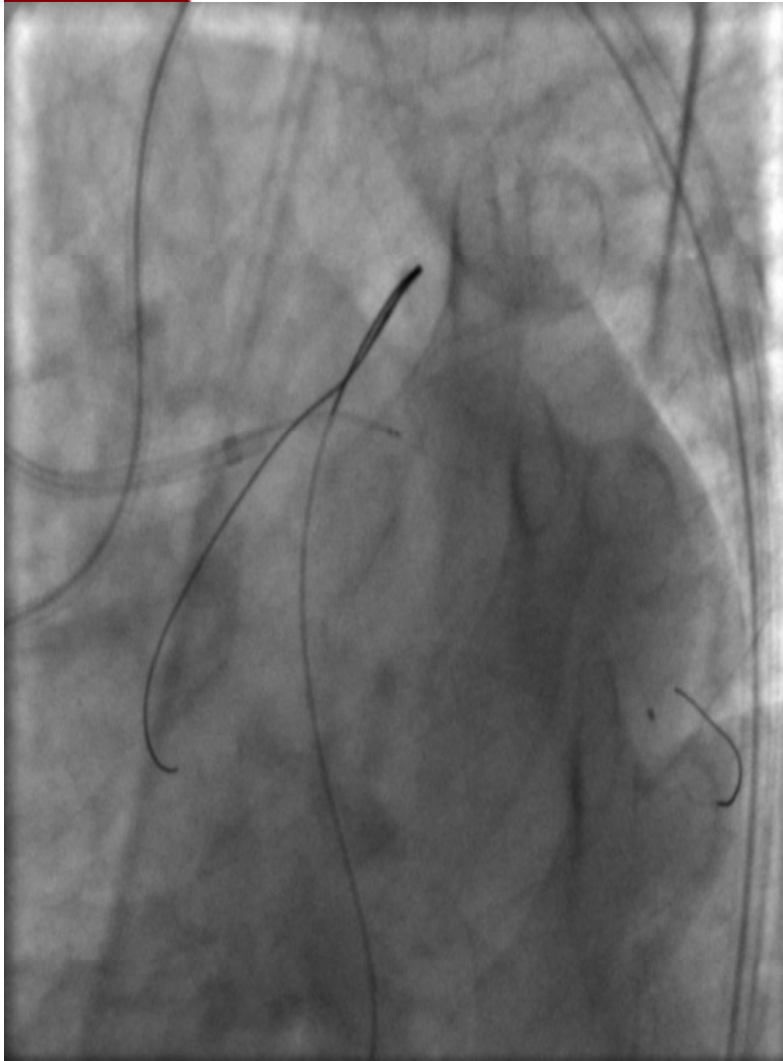
1925

## Miracle 3 on FINECROSS



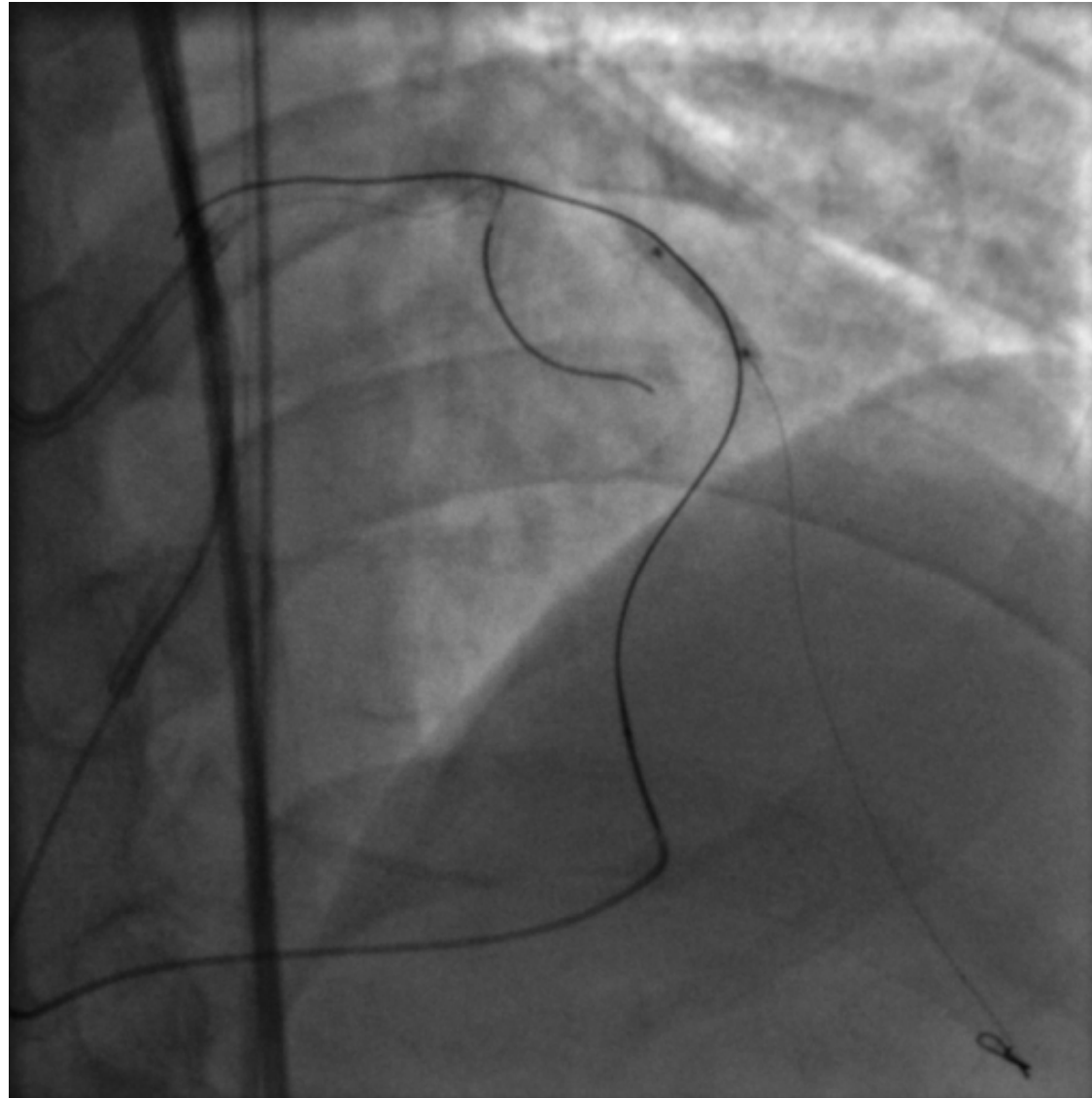


# IVUS





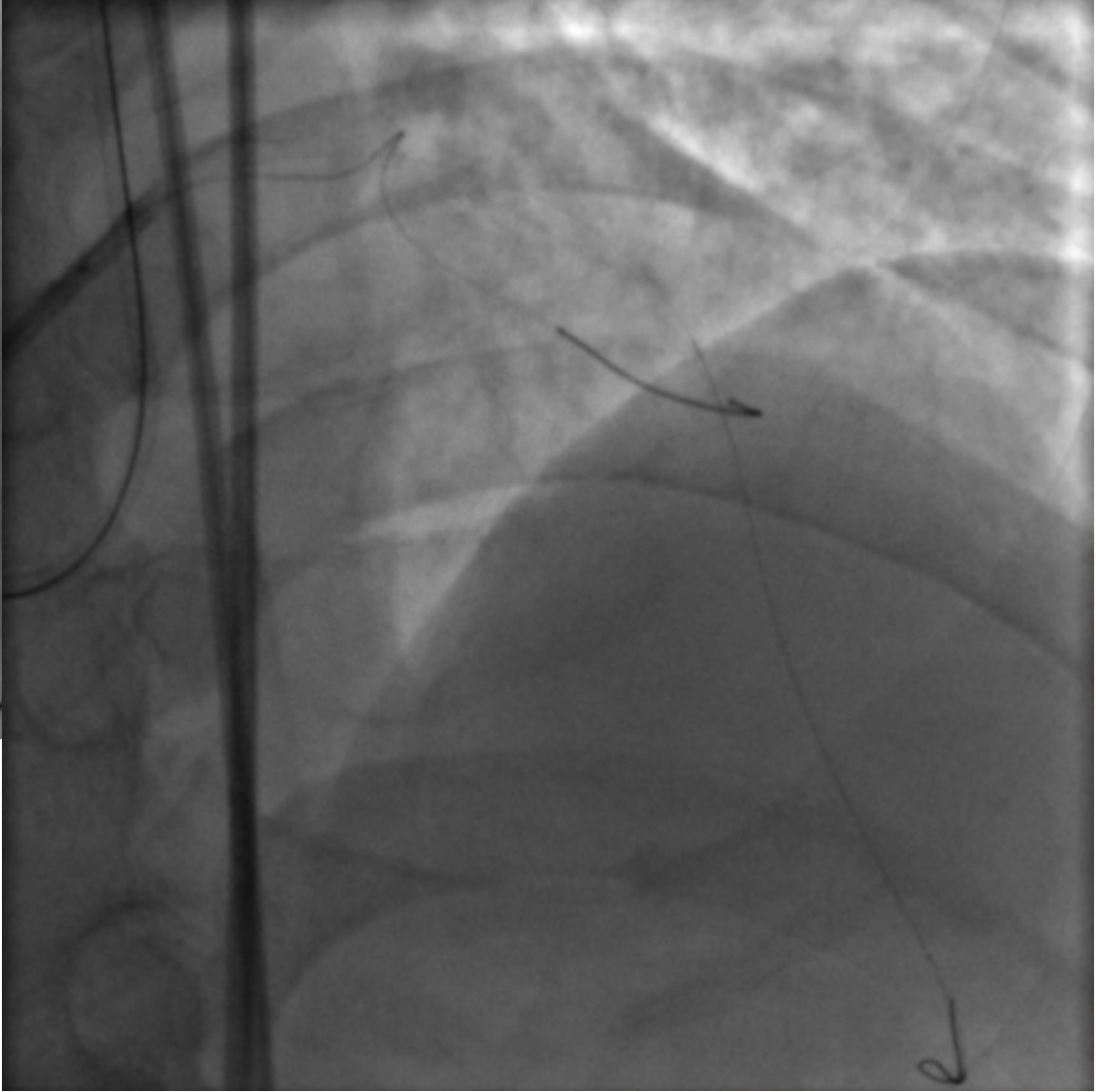
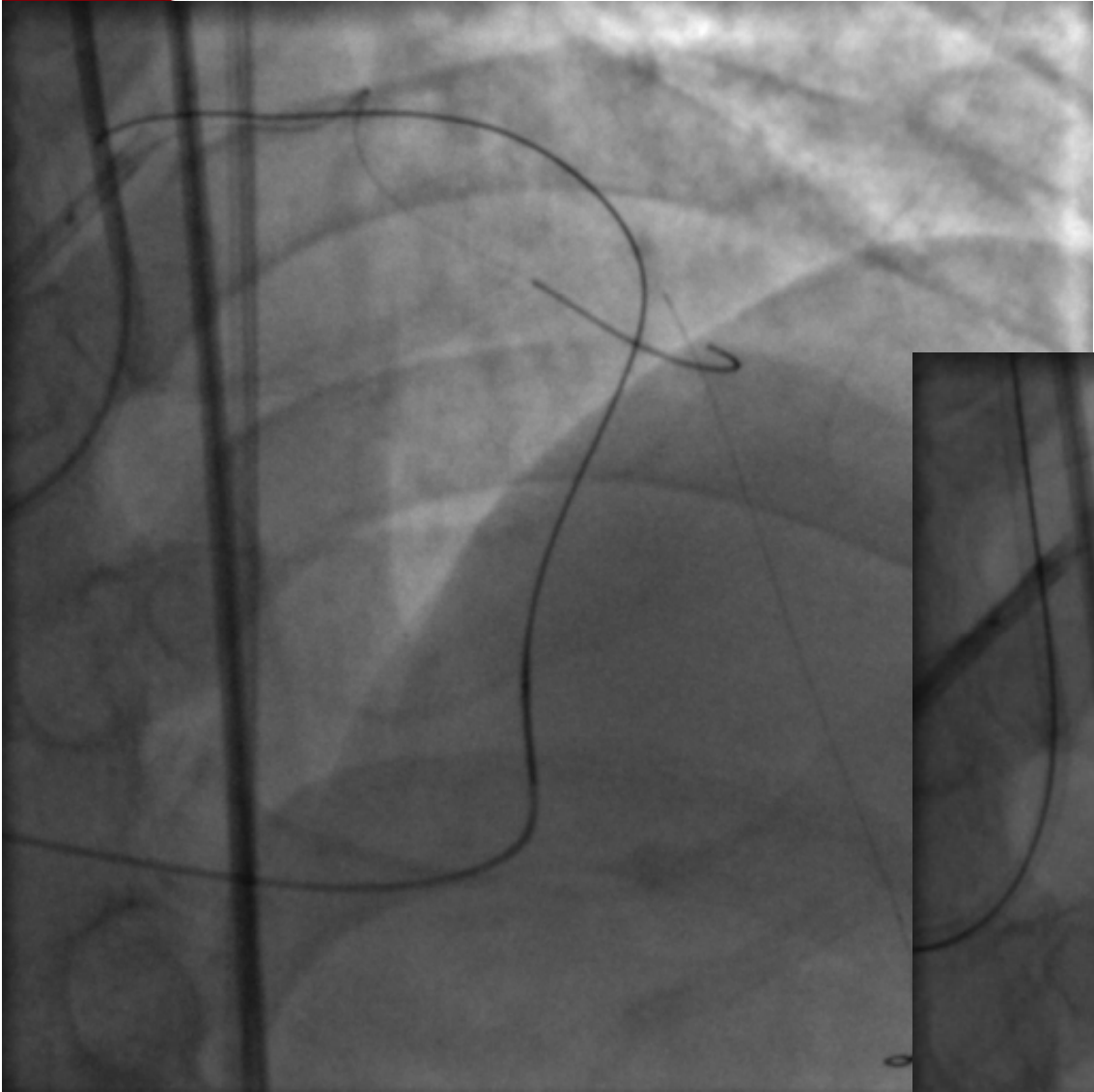
北京大学第一医院  
PEKING UNIVERSITY FIRST HOSPITAL



Fielder FC in LAD  
Balloon Ryujin 2.5\*15mm 12atm

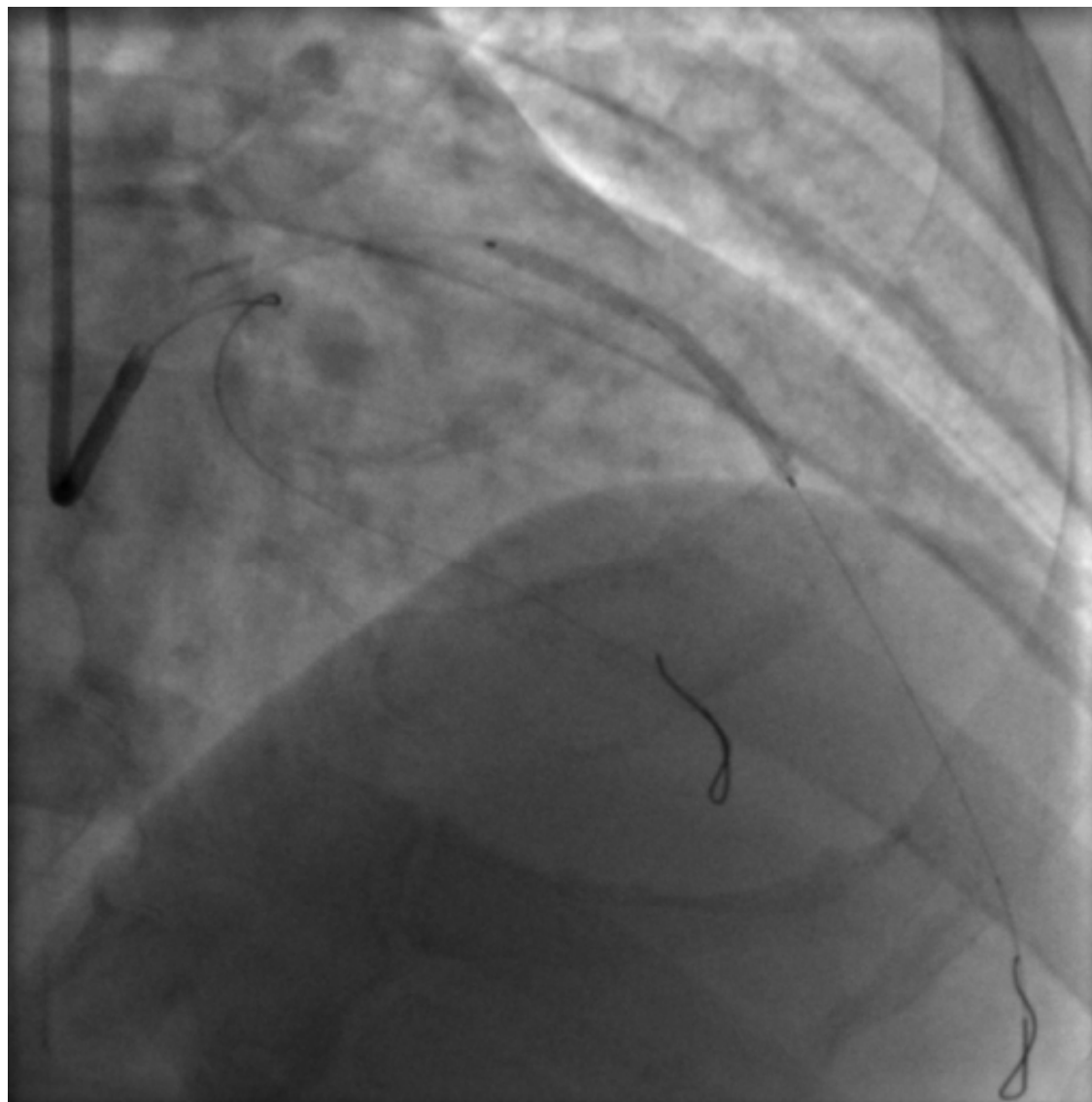




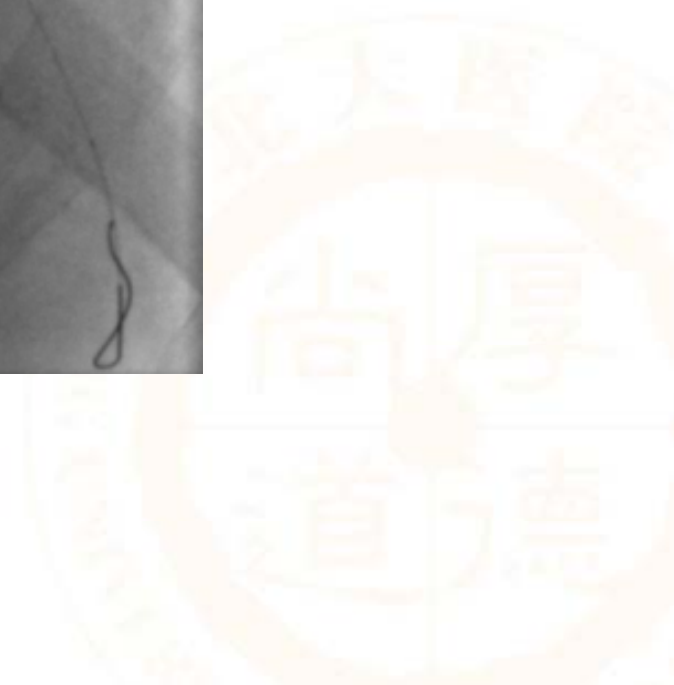




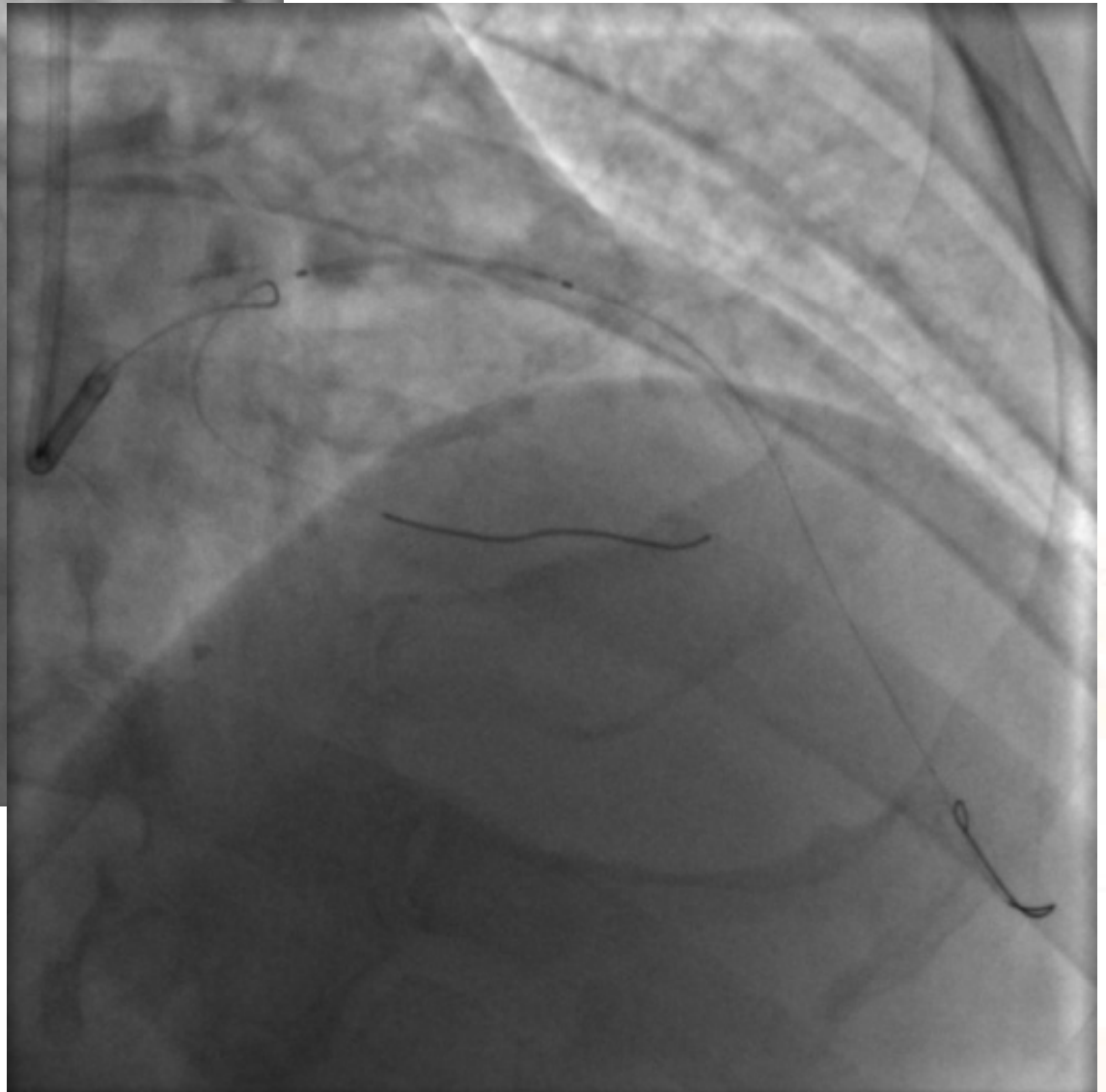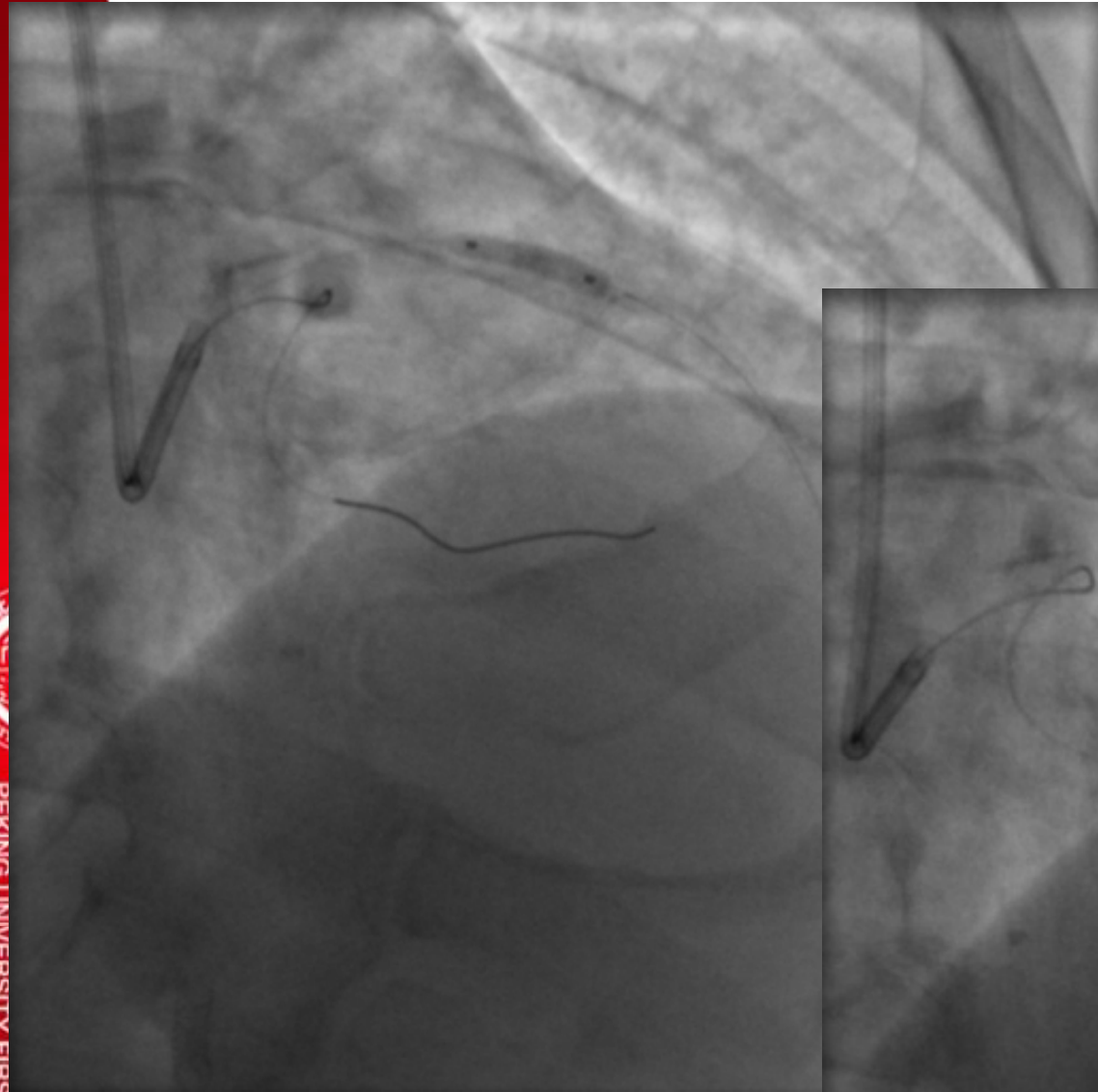
北京大学第一医院  
PEKING UNIVERSITY FIRST HOSPITAL



Stent1 Partner 2.5\*36mm





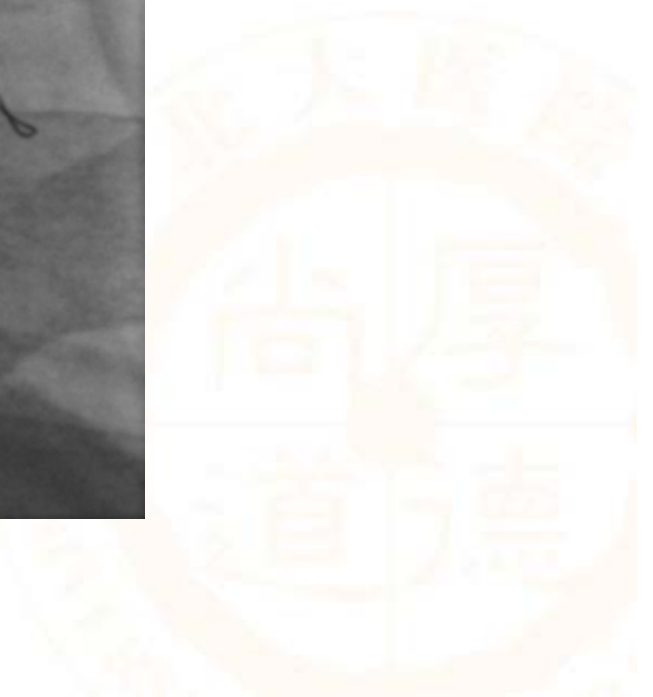
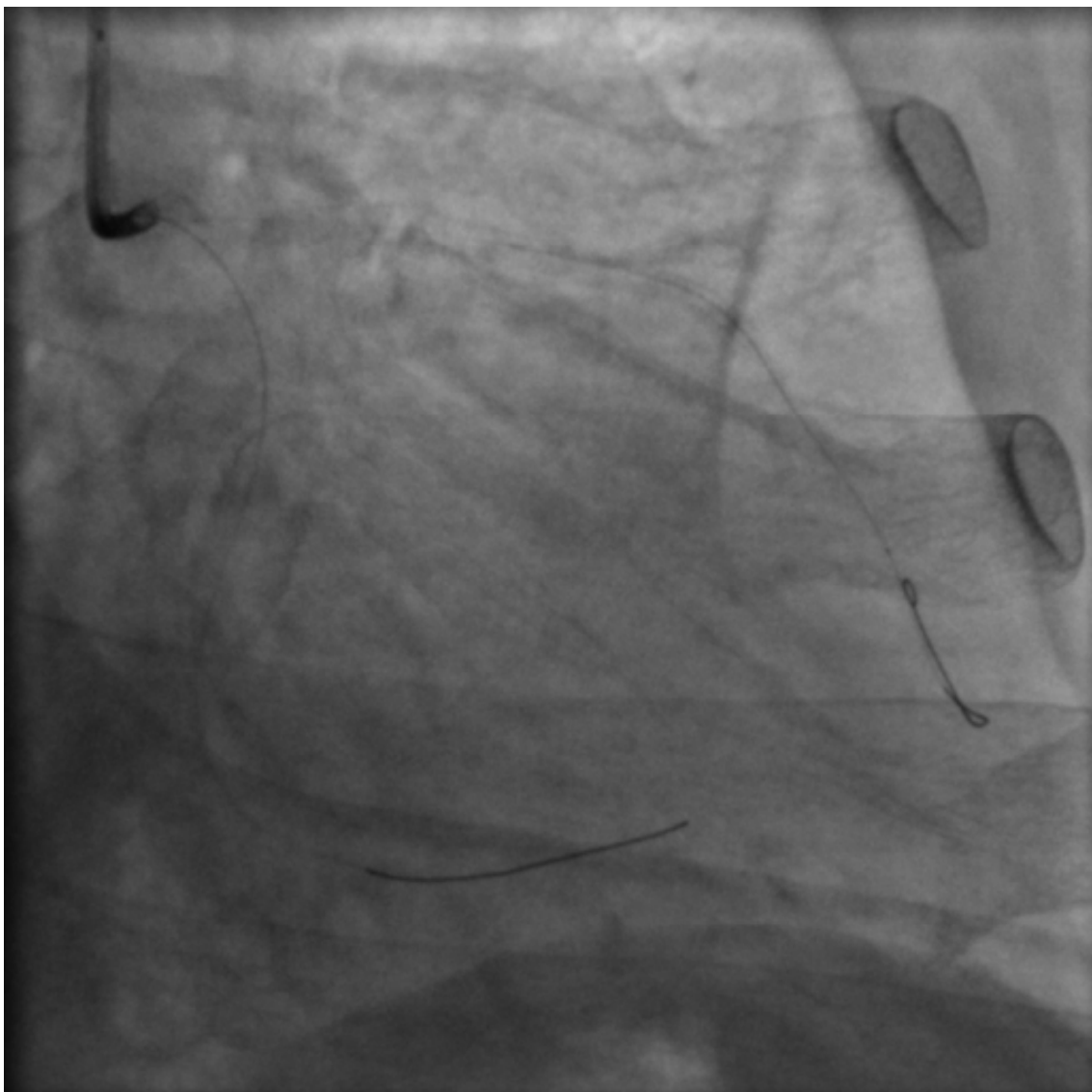


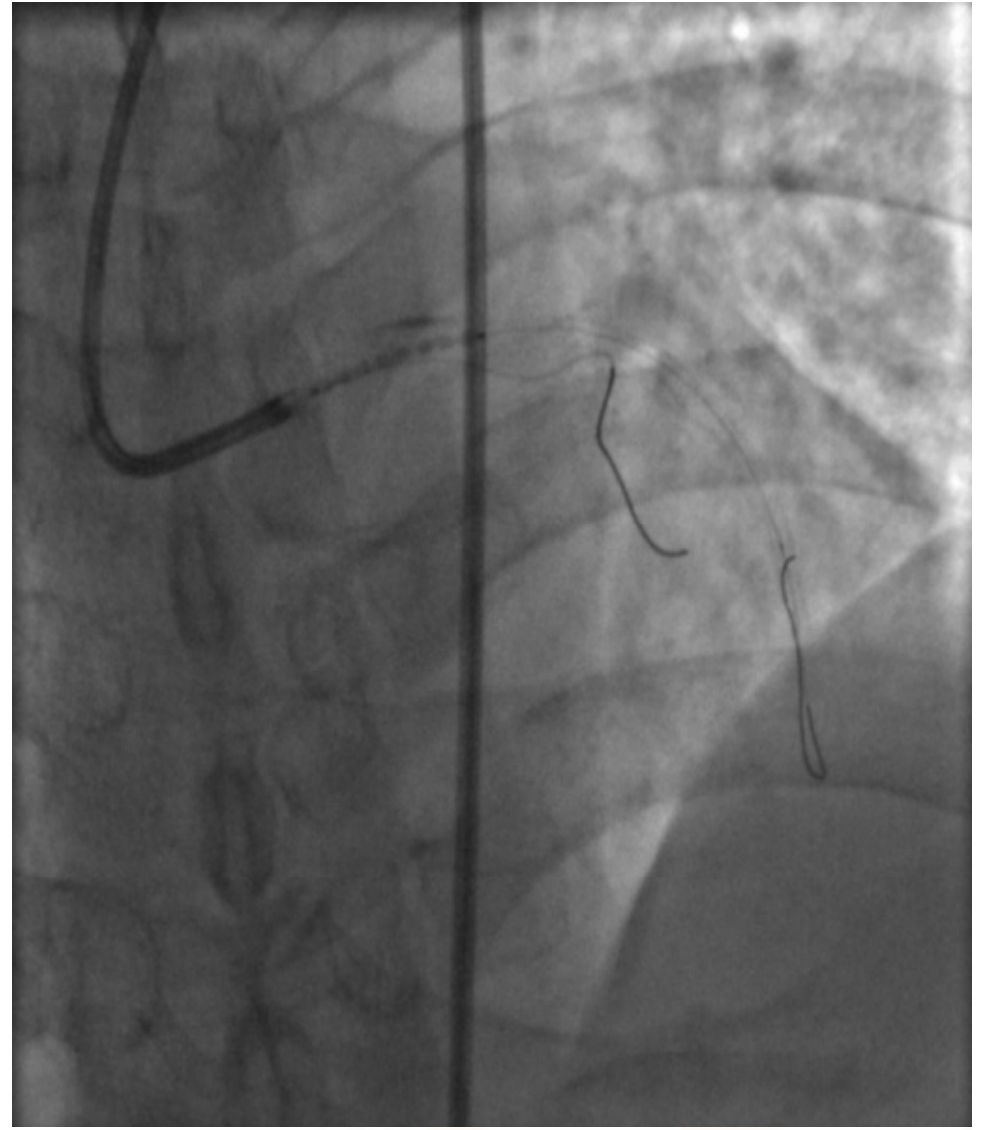
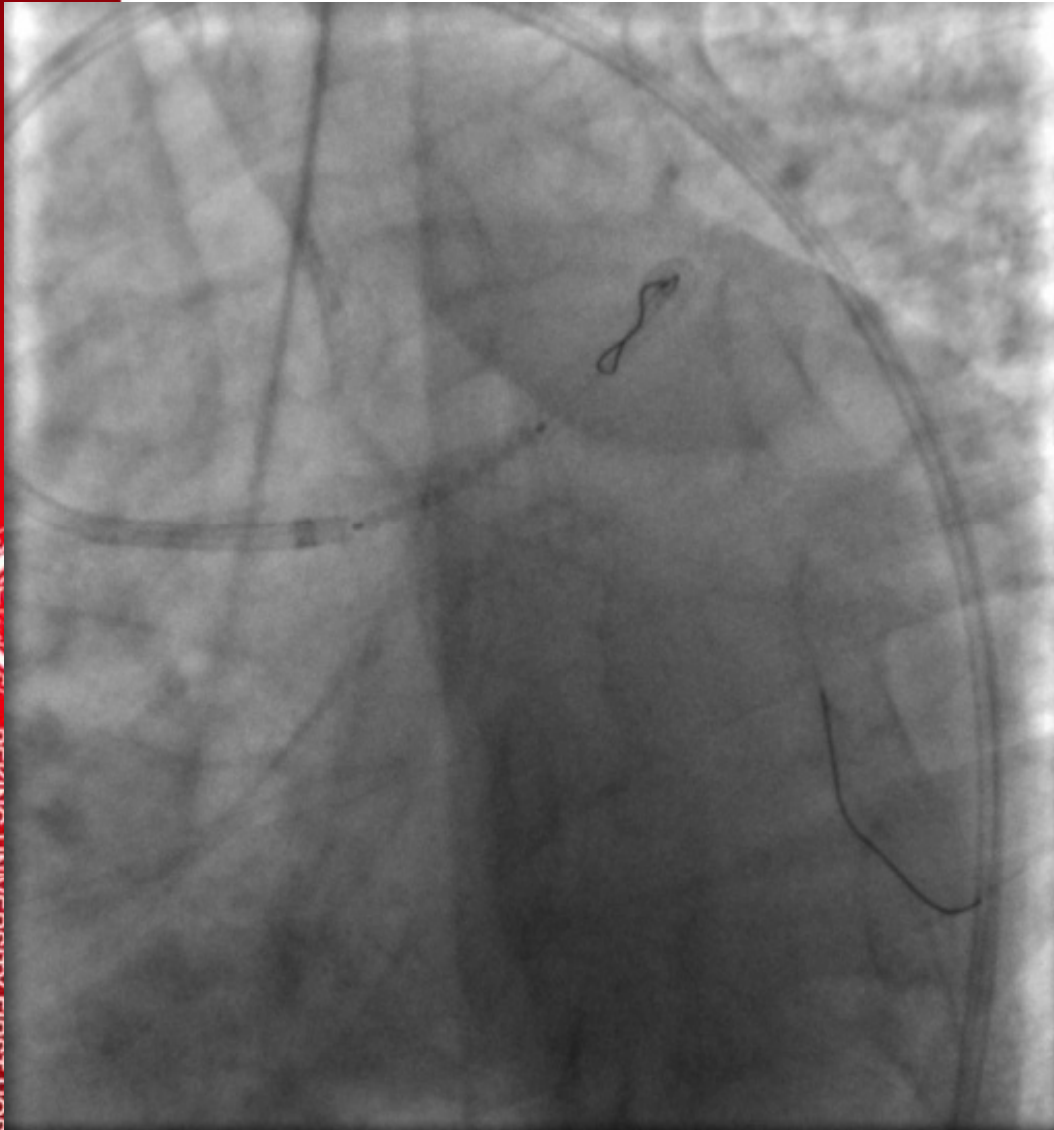NC Sprinter 3.0\*12mm  
Stent2 Partner 3.0\*24mm





北京大学第一医院  
PEKING UNIVERSITY FIRST HOSPITAL

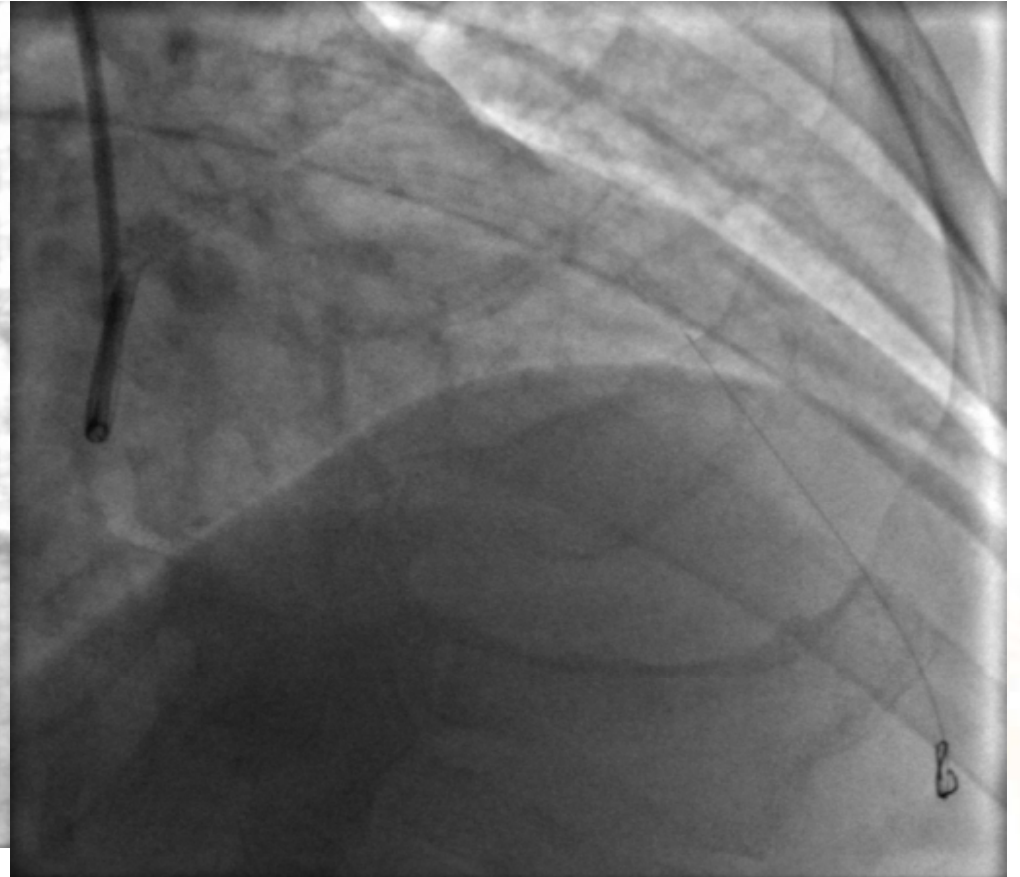
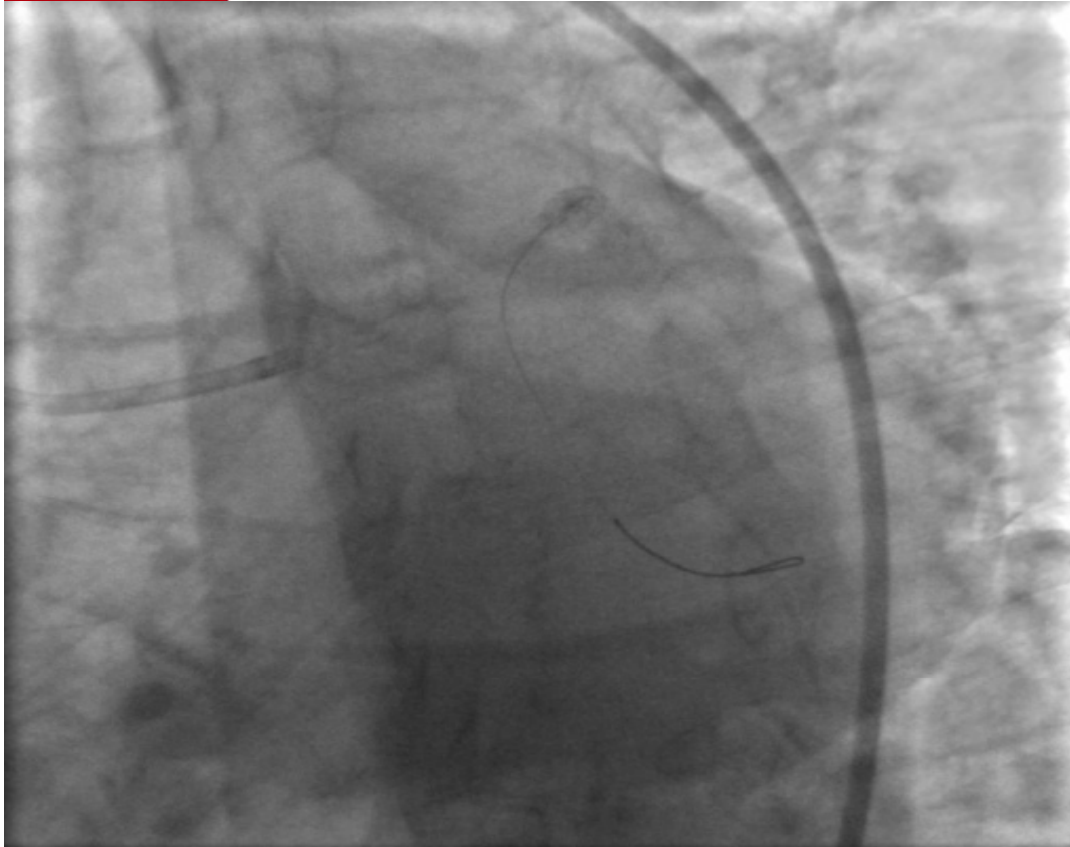



**Stent3 Cypher select 3.5\*18mm  
16atm**



# Final Result





# Medical treatment

- Anti-DM therapy
- DAP
- Statin
- B-blocker



# F/U

- LDL-C < 2 mmol/L
- GHBA1c < 7%
- 3 years, no angina.

