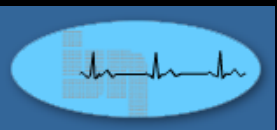


INSTITUT JANTUNG NEGARA
National Heart Institute

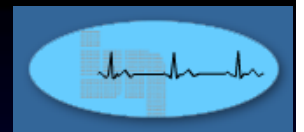


PCI in A Young Lady



National Heart Institute, Kuala Lumpur





55 yr old lady (nursing staff)

Chest pain on exertion for 1 month CCS II

Relieved with rest

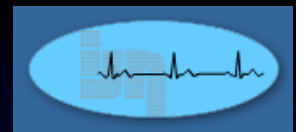
In denial

Came back to KL for holidays

Same day of arrival, severe chest pains at 11:30 pm after dinner

Family history of premature CAD

Mother, younger brother



O/E

Was in severe pain

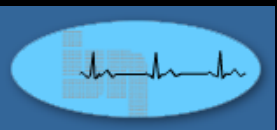
Not tachypnoeic

BP 170/100

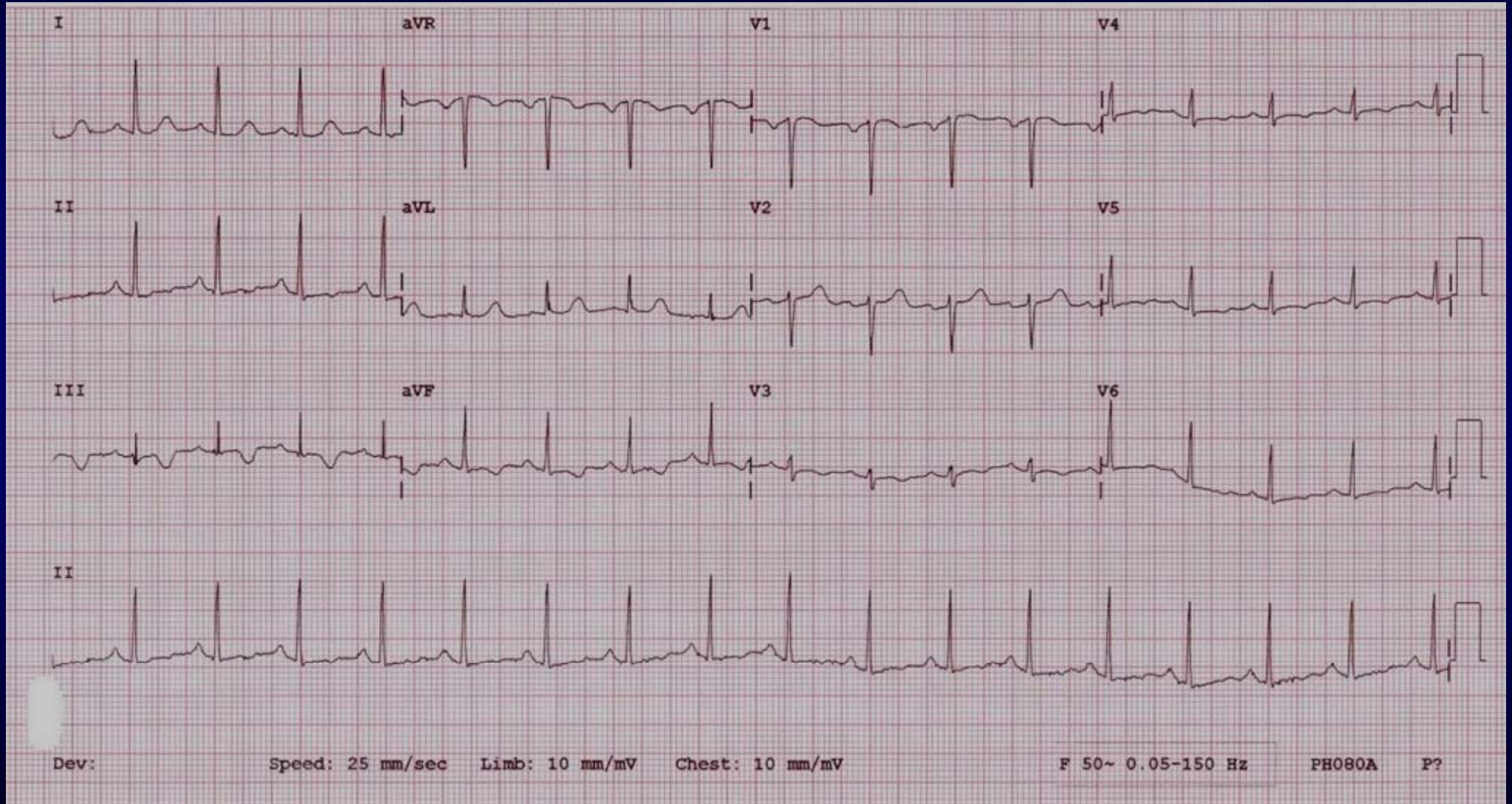
HR 100/min regular

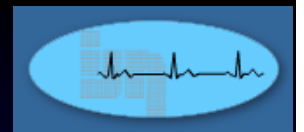
CVS – normal heart sounds

Lungs – normal breath sounds



ECG 12:10 am 30th March 2013





2D Echo

No regional wall motion abnormality

LVEF 67%

No LVH

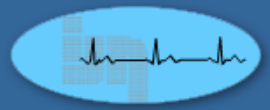
12:48 am 30/3/13

CK 90

CKMB 22

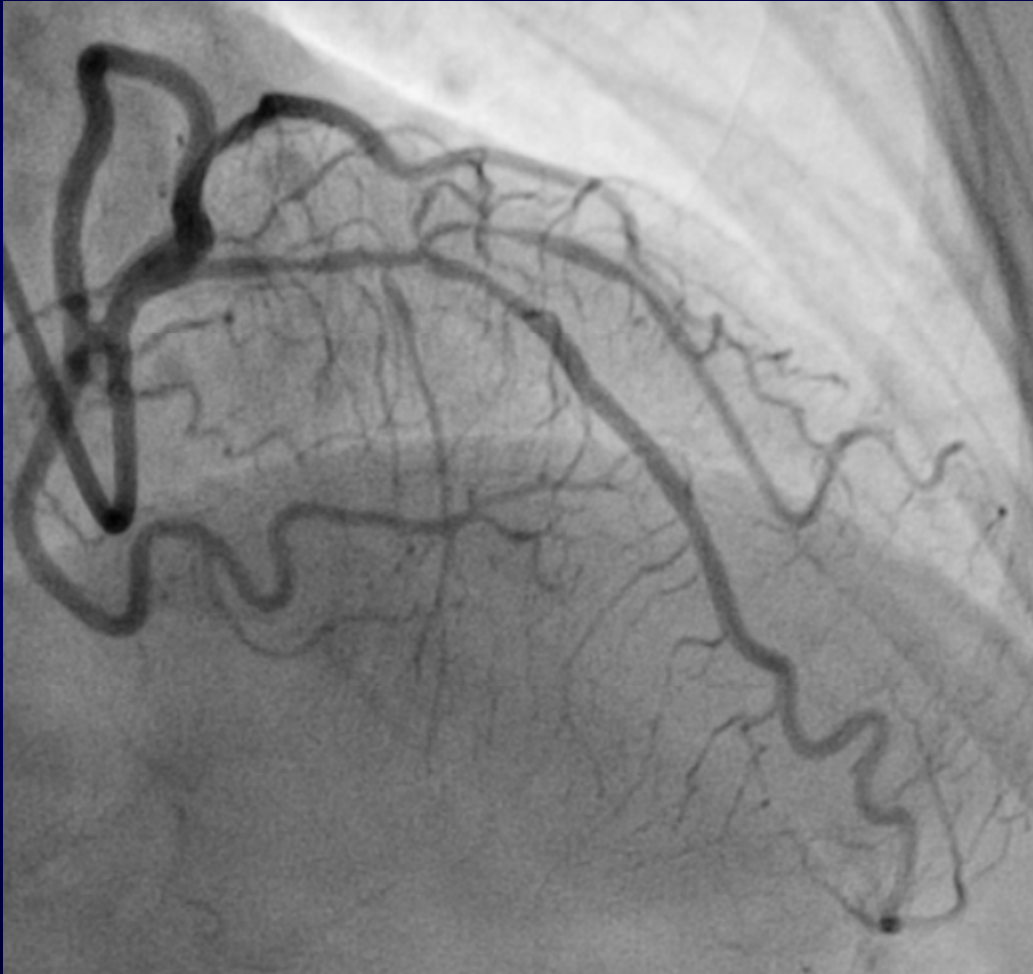
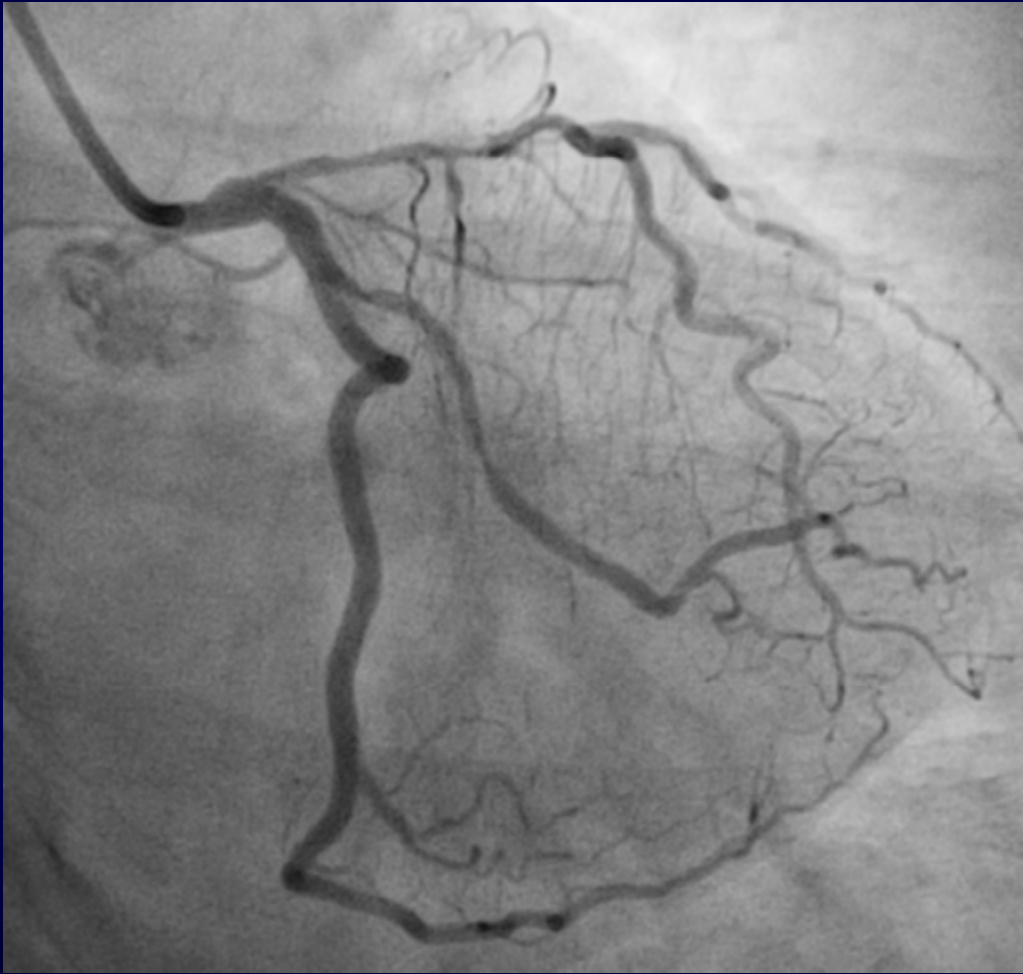Trop. T 0.005 ug/L

How would You Treat?

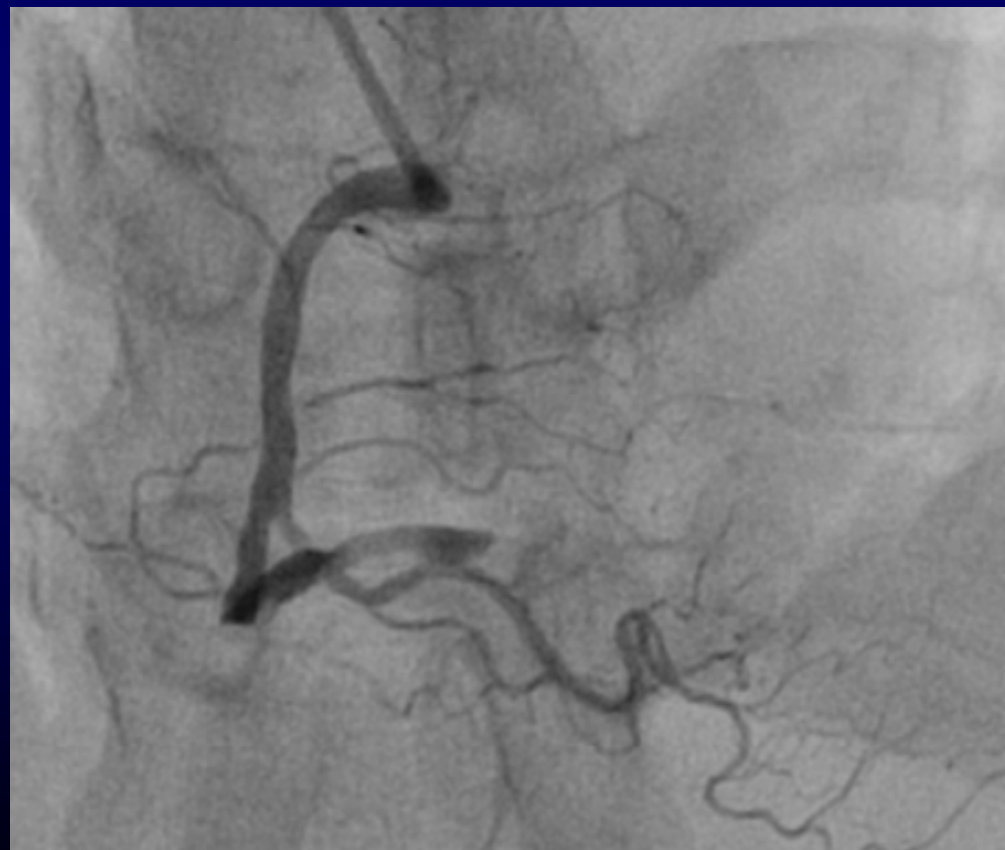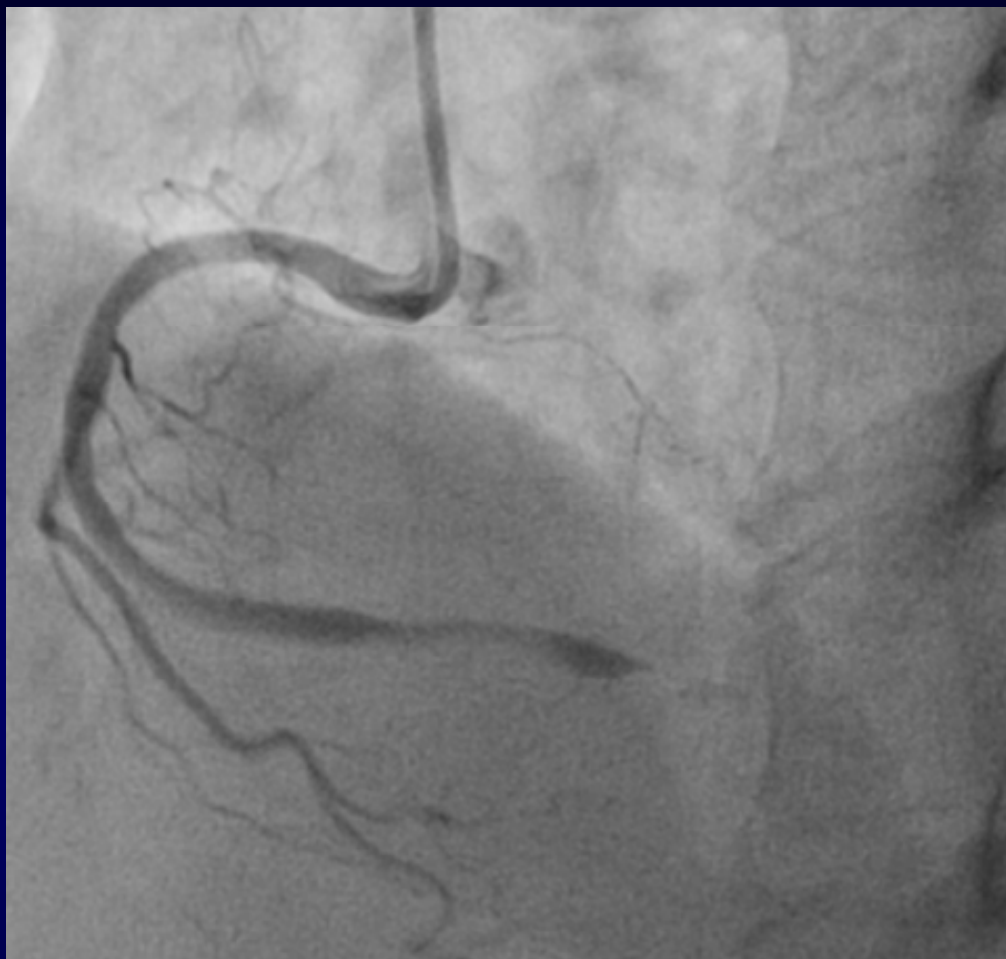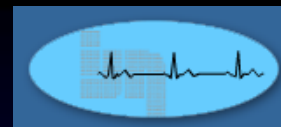


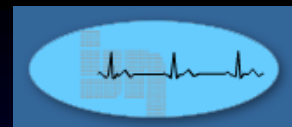30 March 2013

Rt. TRI

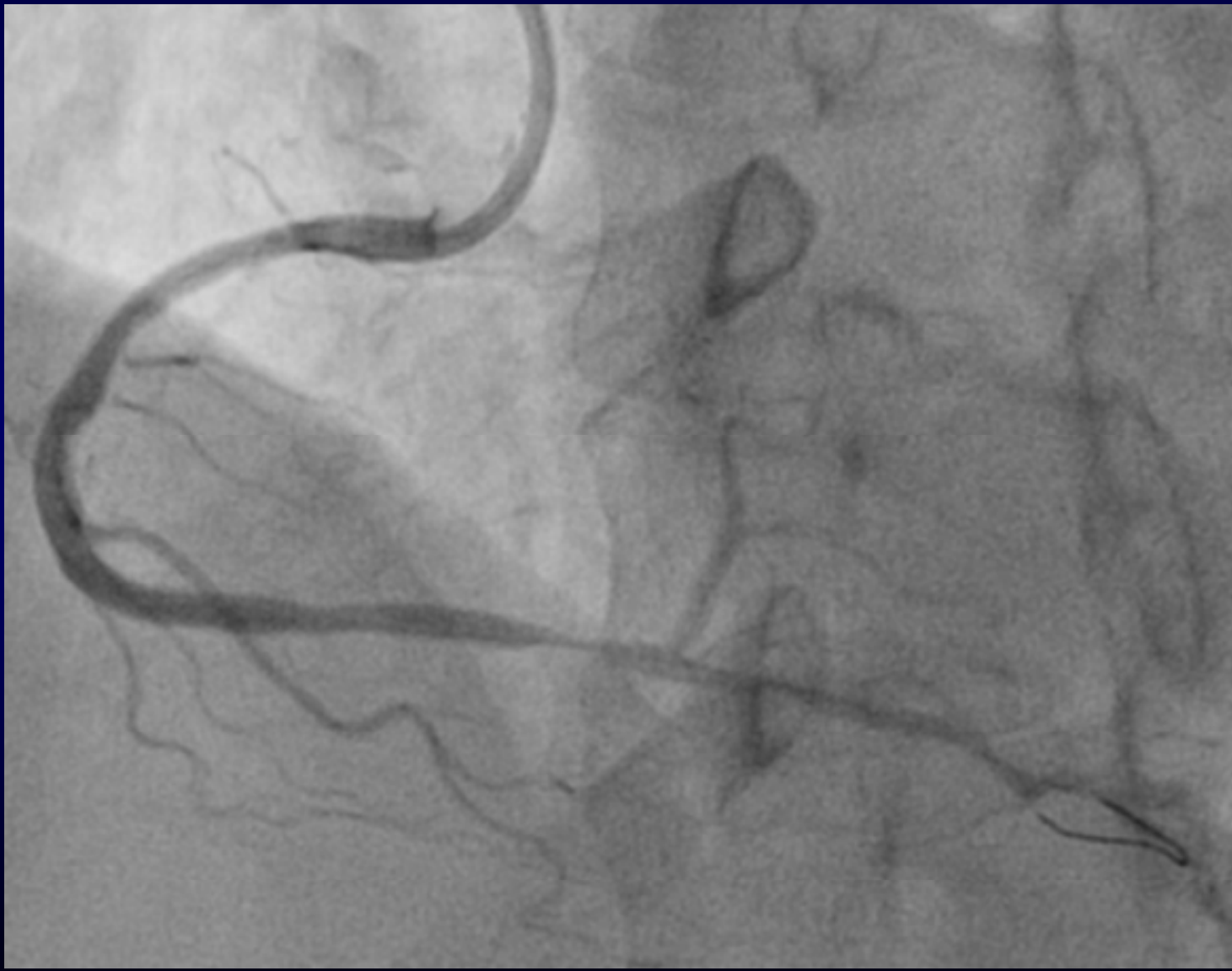

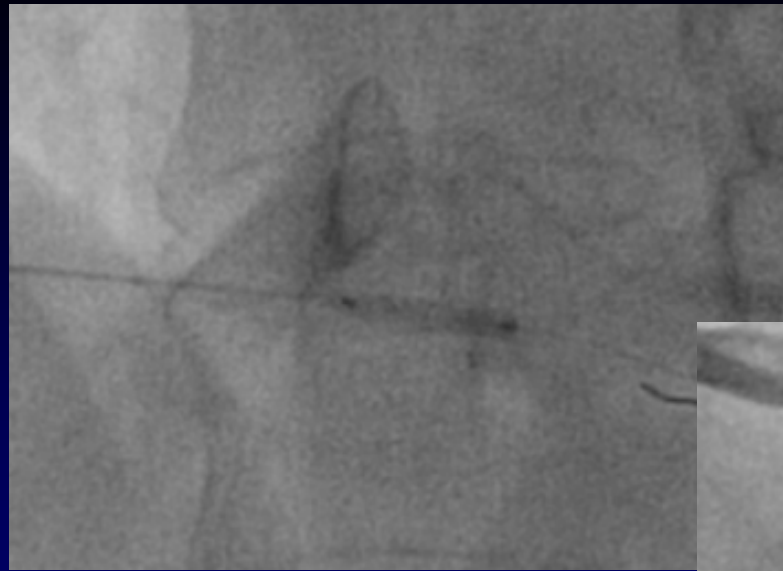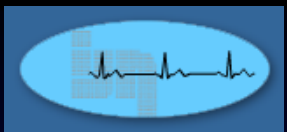
Occluded Distal RCA



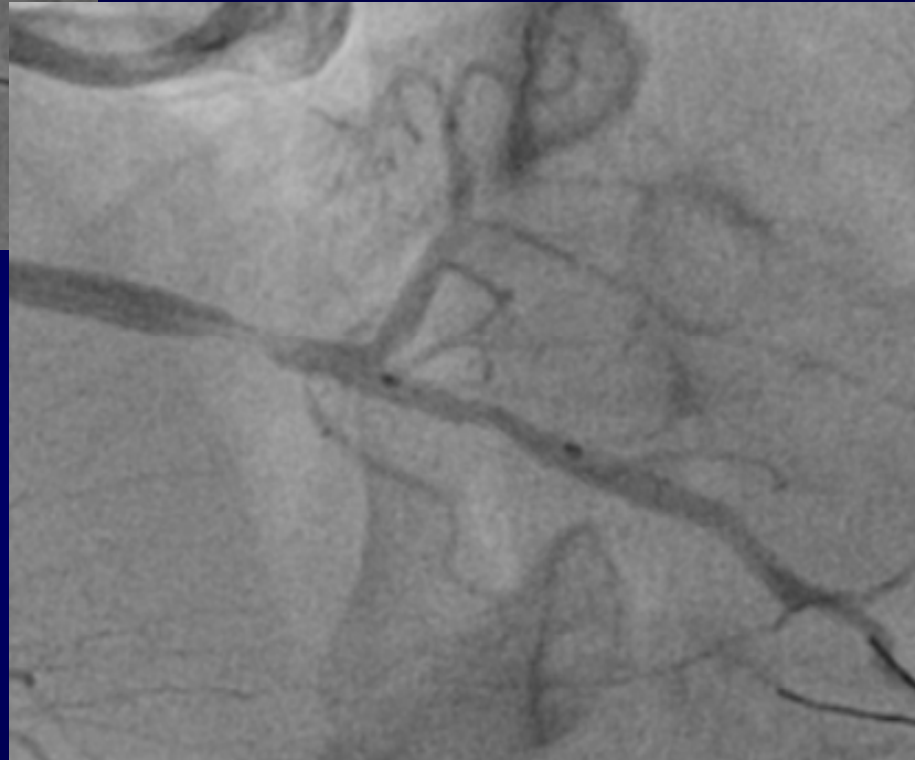


Guide SAL 1 6 Fr
Runthrough Floppy wire
Thrombuster 6 Fr – 1 aspiration

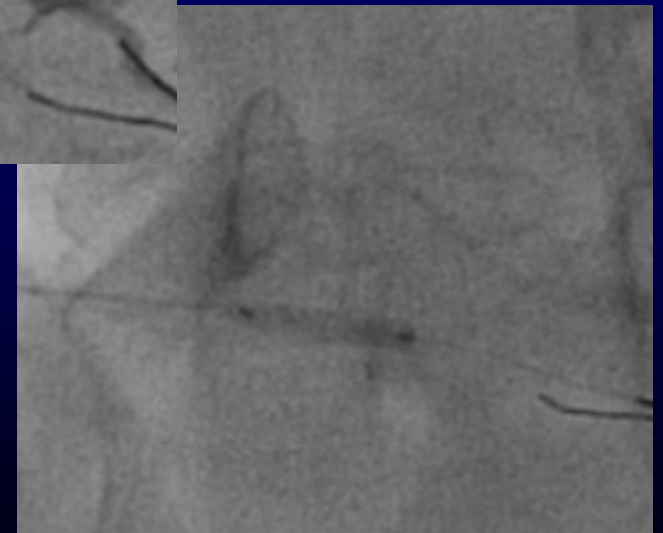


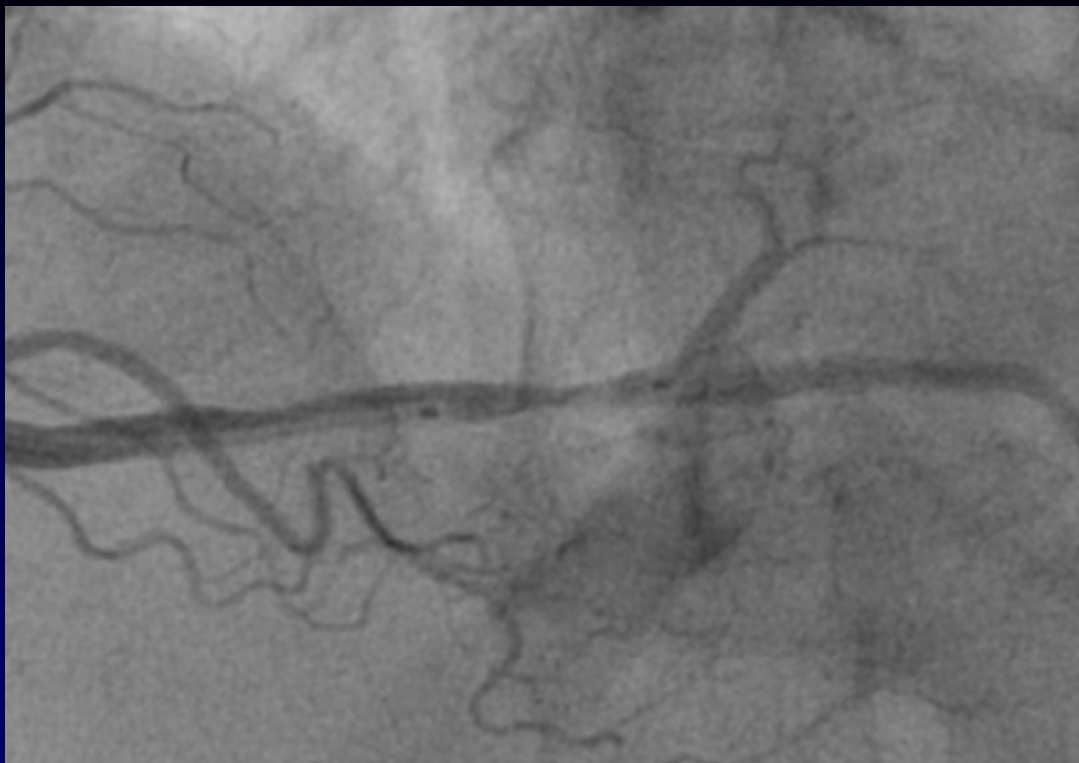

Predilate Sapphire II 2.0 x 12 mm

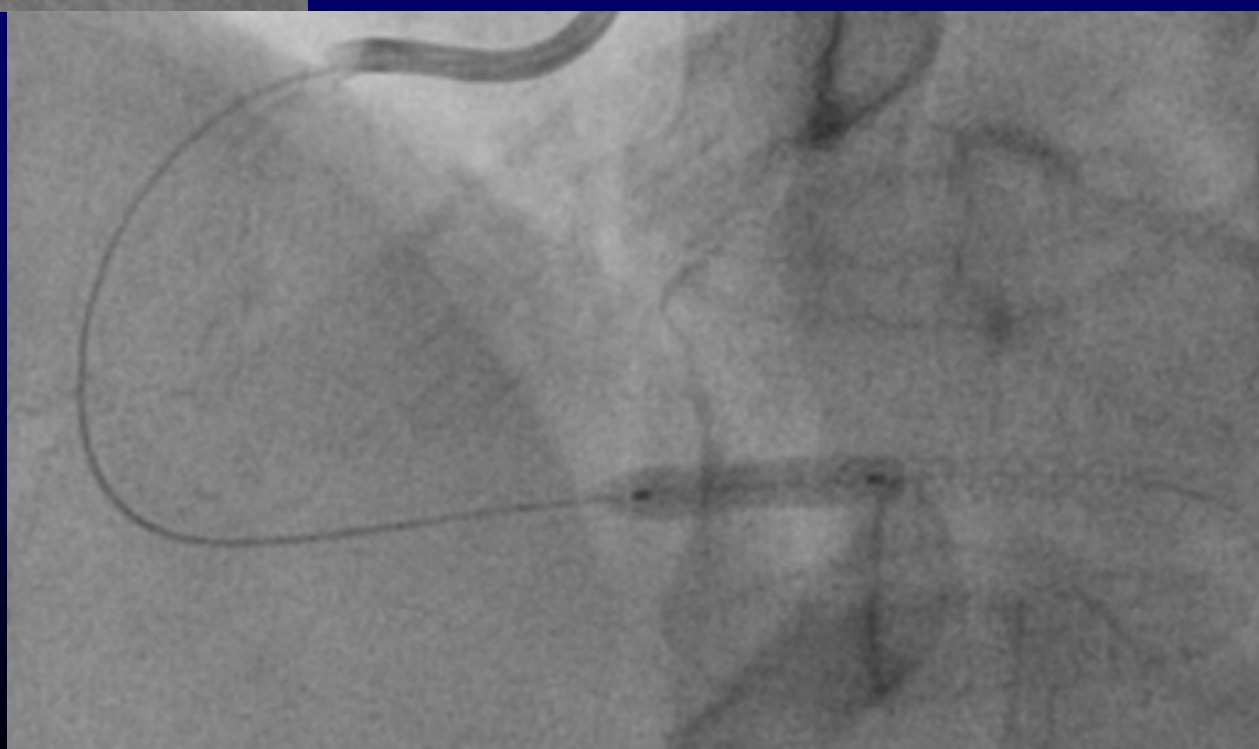


Biomatrix flex 2.5 x 8 mm at 16 Atm



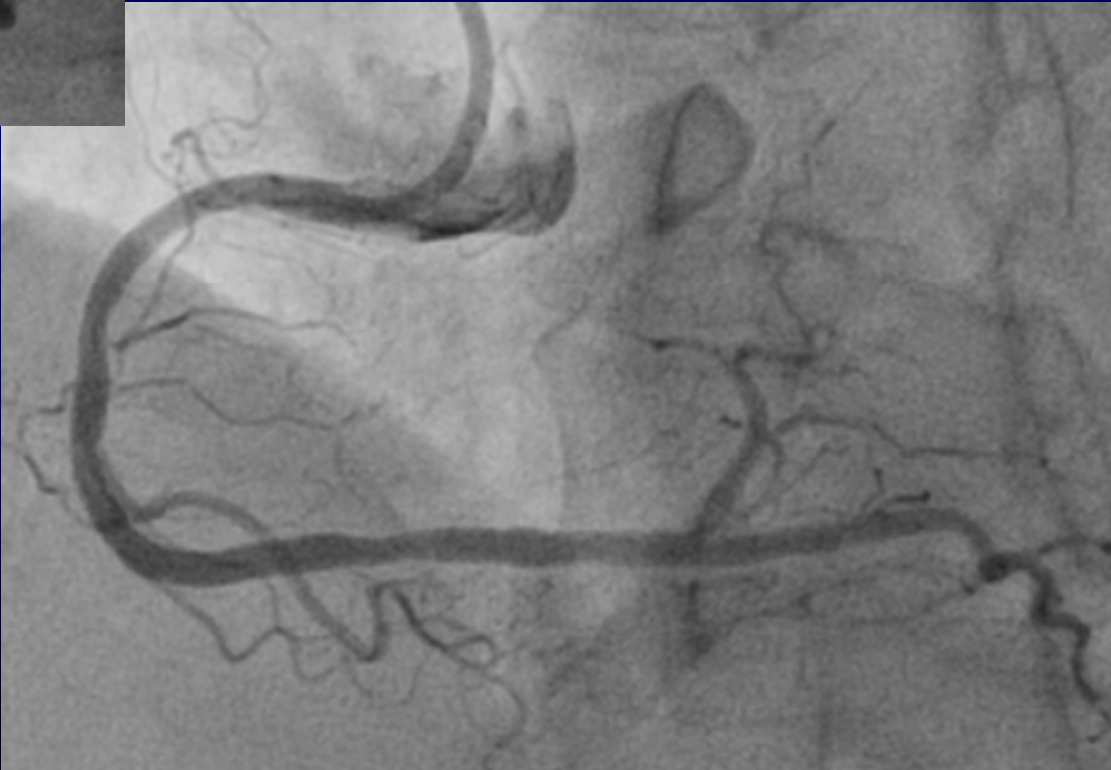
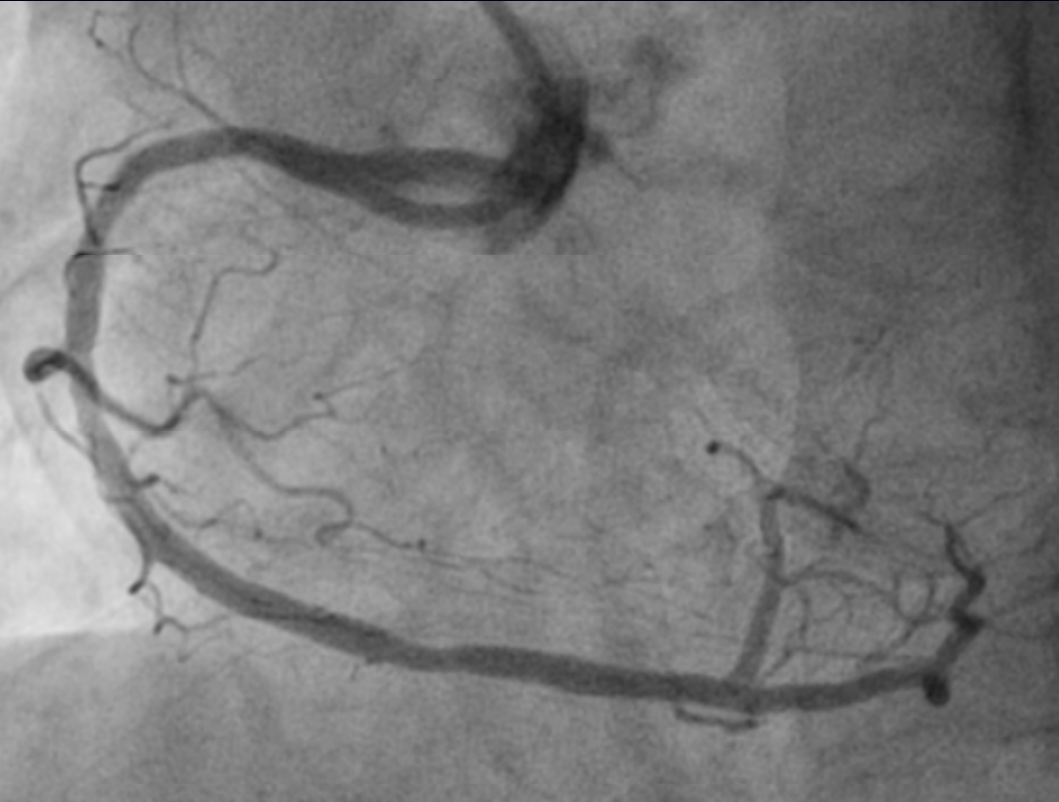
Resolute Integrity
3.0 x 12 mm at 16 Atm



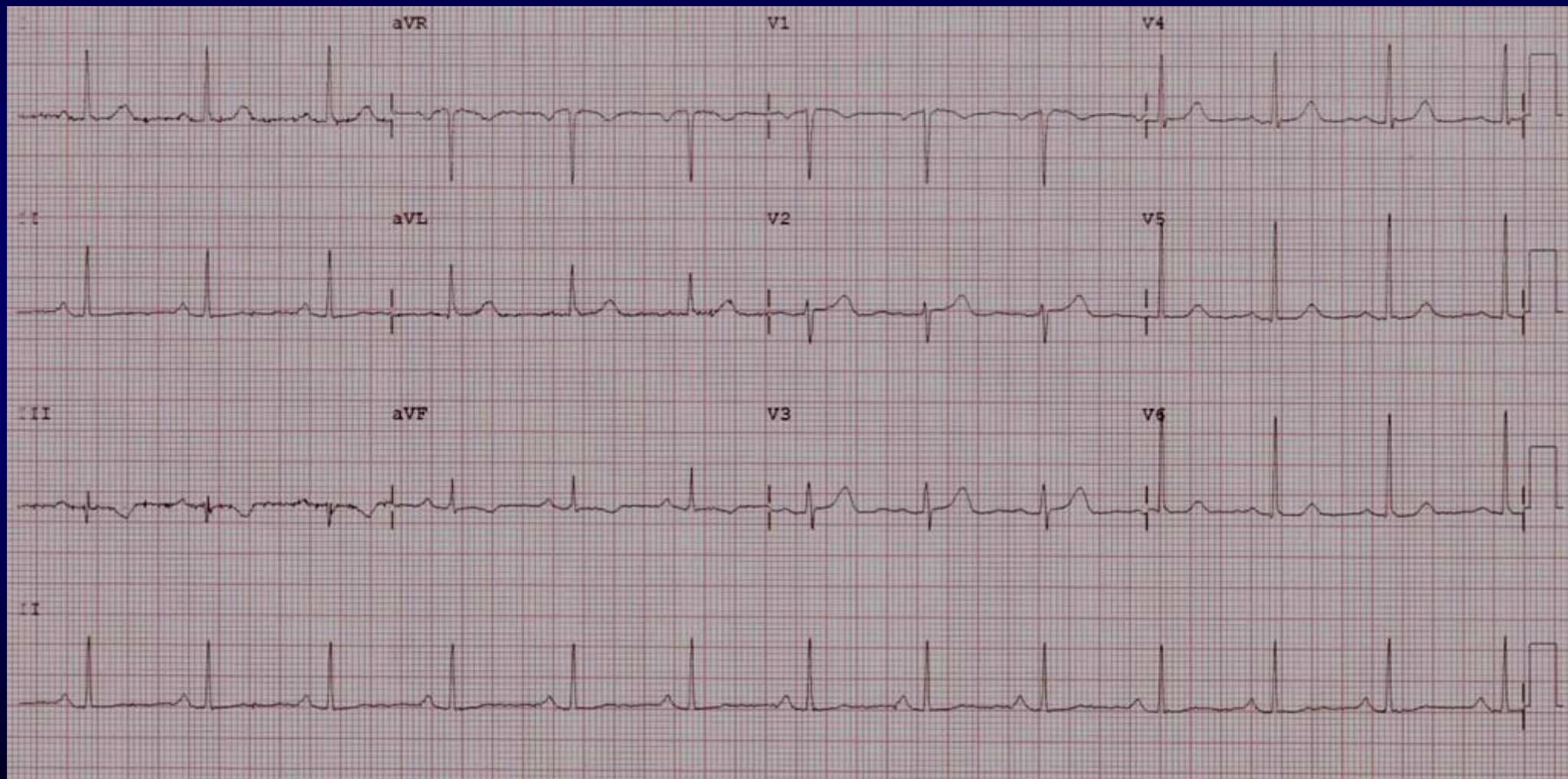


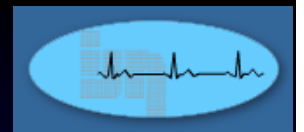
Post PCI





ECG 1:37 am 30th March 2013 – Post PCI





30th March 2013

TC 4.8 mmol/L

TG 1.0 mmol/L

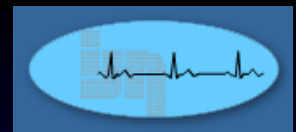
HDL-c 1.9 mmol/L

LDL-c 2.4 mmol/L

FBS 6.1 mmol/L (N 3.1 – 5.5)

Creatinine 52 umol/L (N < 103)

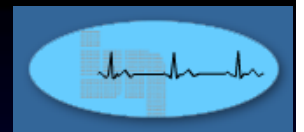
TSH 1.29 mU/L (N 0.27 – 4.2)



No further angina following the PCI

Discharged well 31st March 2012

	12:48 am 30/3/13	9:46 am 30/3/13
CK	90	86
CKMB	22	26
Trop. T	< 0.005 ug/L	0.0014 ug/L

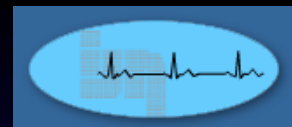


Readmitted on 2nd April 2013

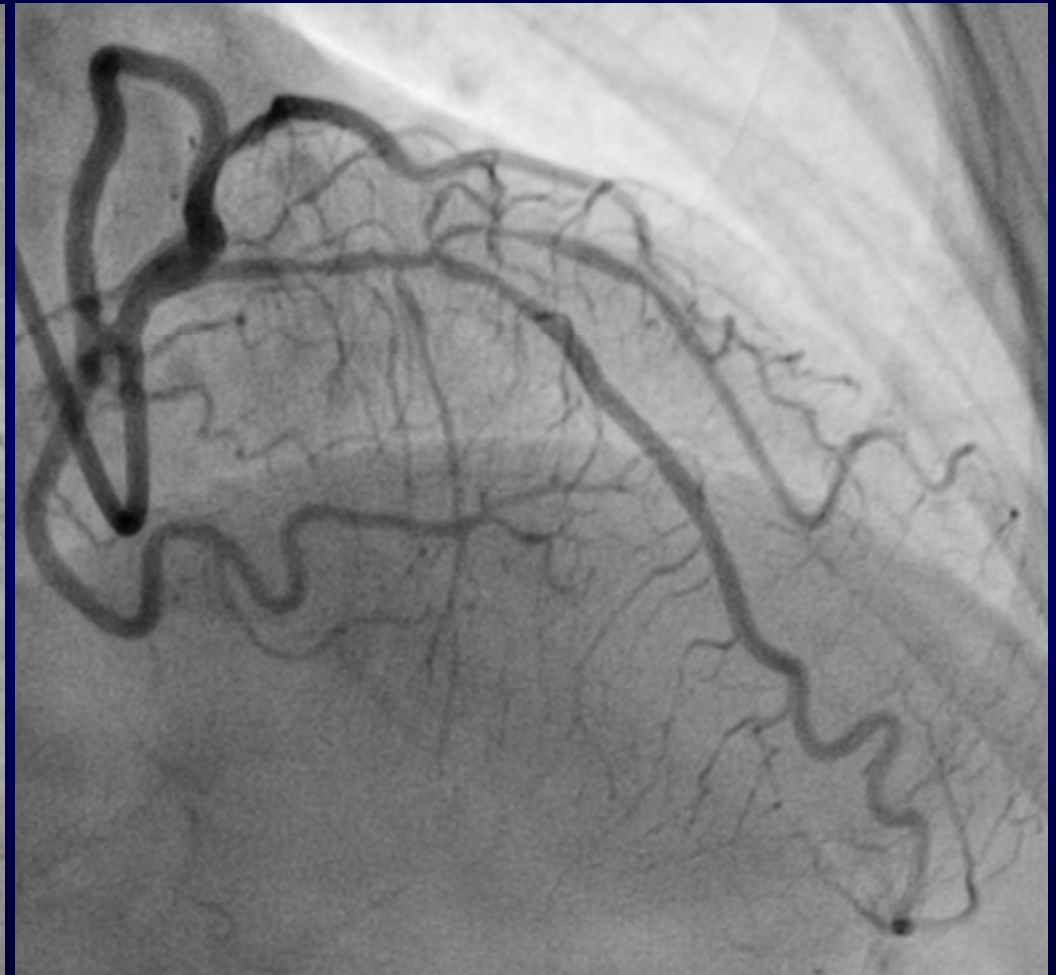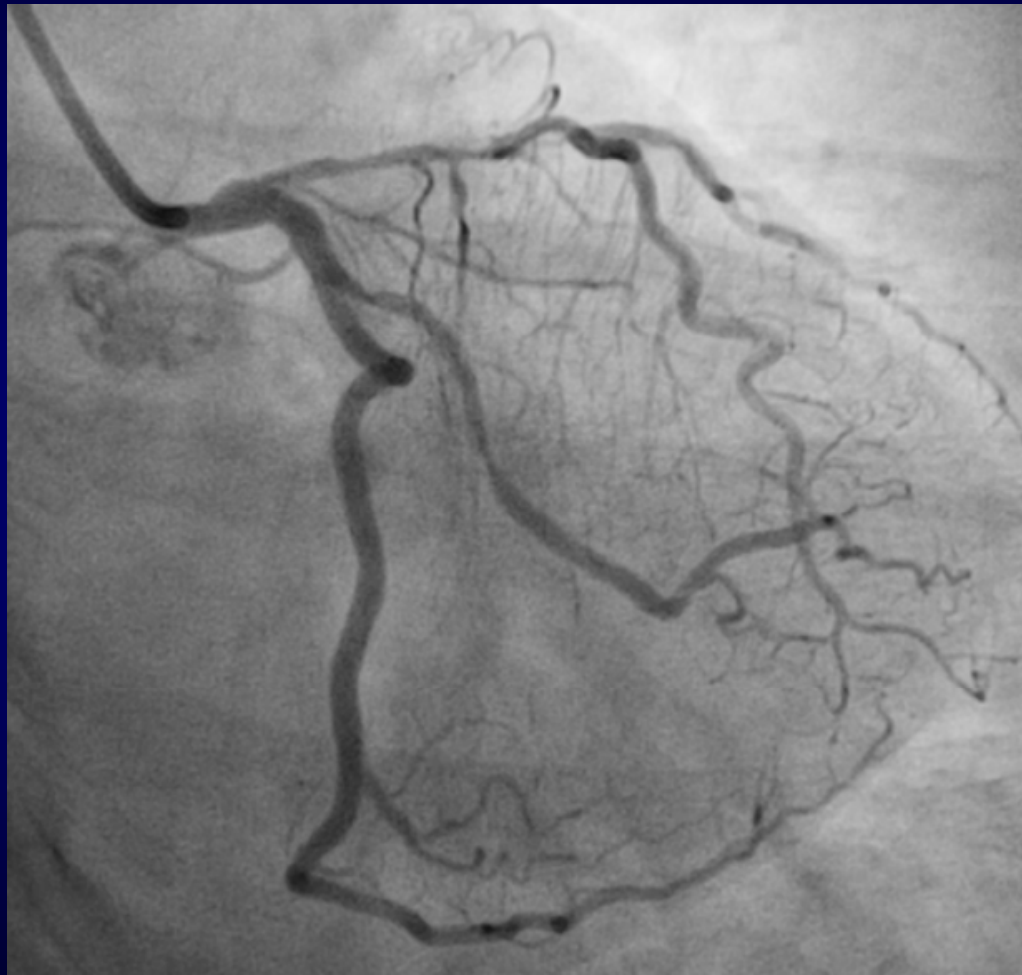Angina free

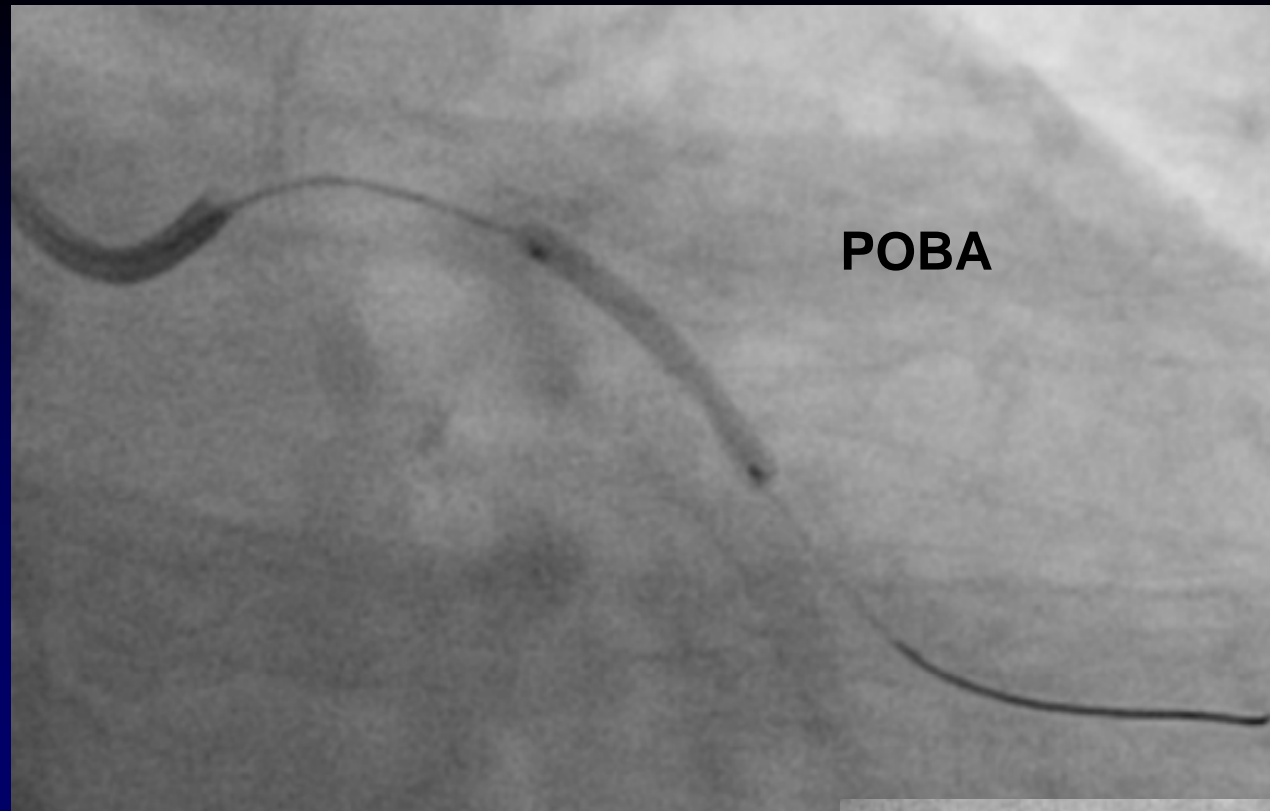
BP 142/96

PR 88/min regular



2nd PCI to LCA 2nd April 2013
Rt. TRI





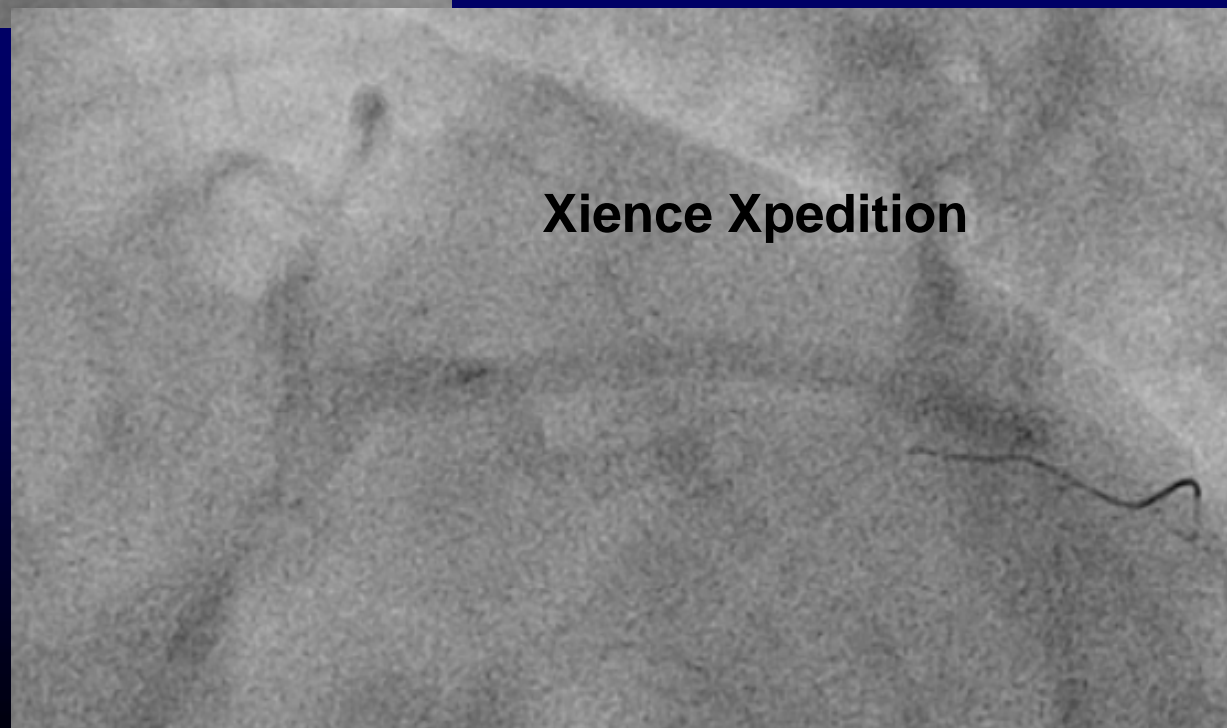
POBA

Guide Cath. EBU 3.0 6 Fr

Wire: Sion Blue

**Predilate Sapphire II
2.0 x 20 mm at 14 Atm**

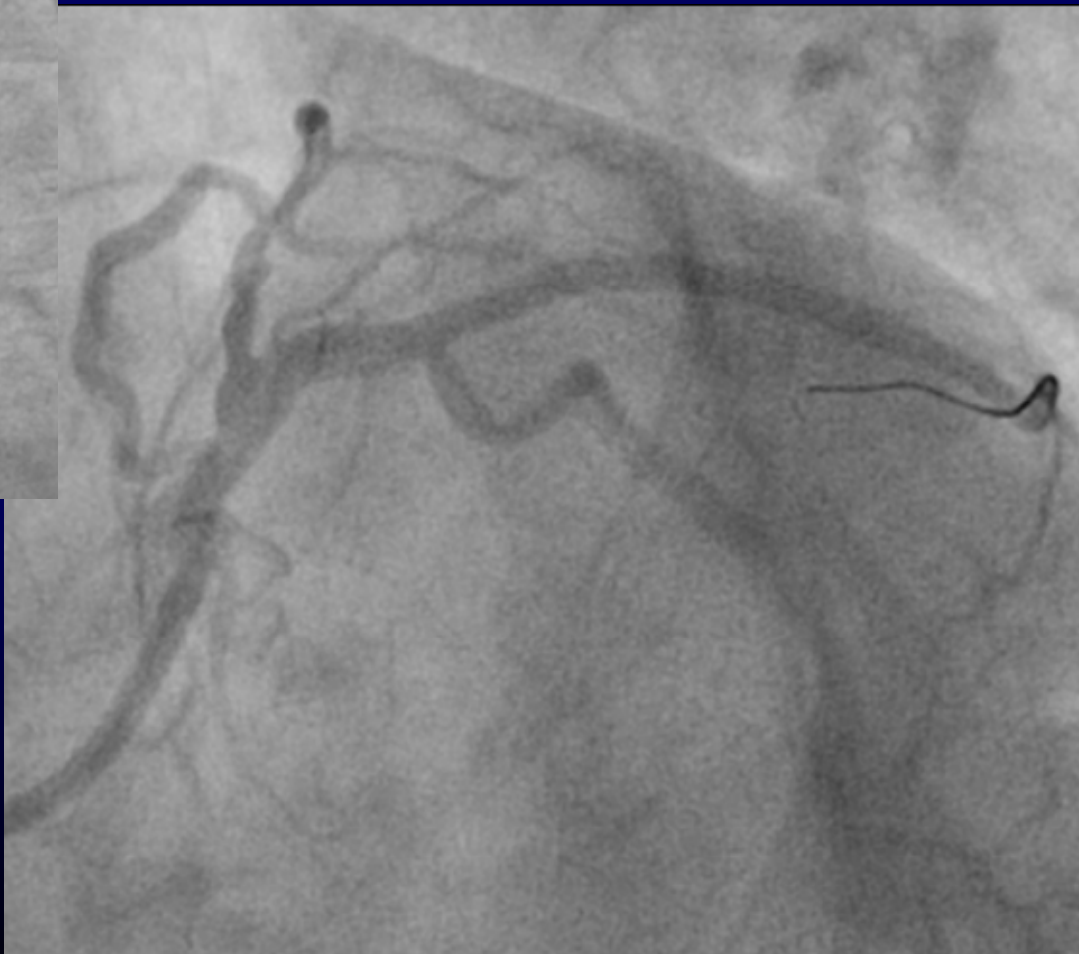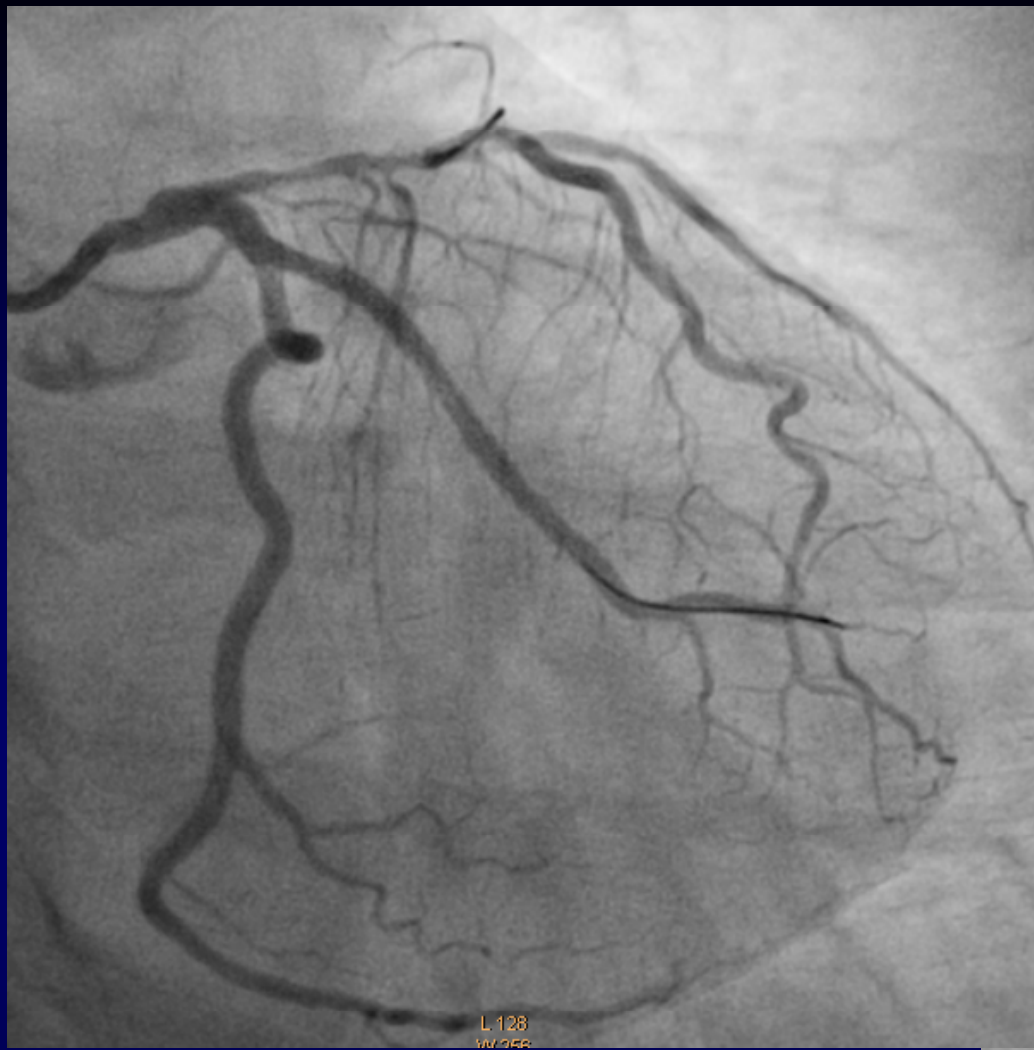
**Stent: Xience Xpedition
2.5 x 33 mm at 16 Atm**



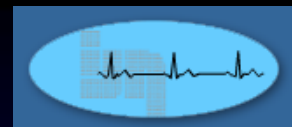
Xience Xpedition



Post-stenting



POBA

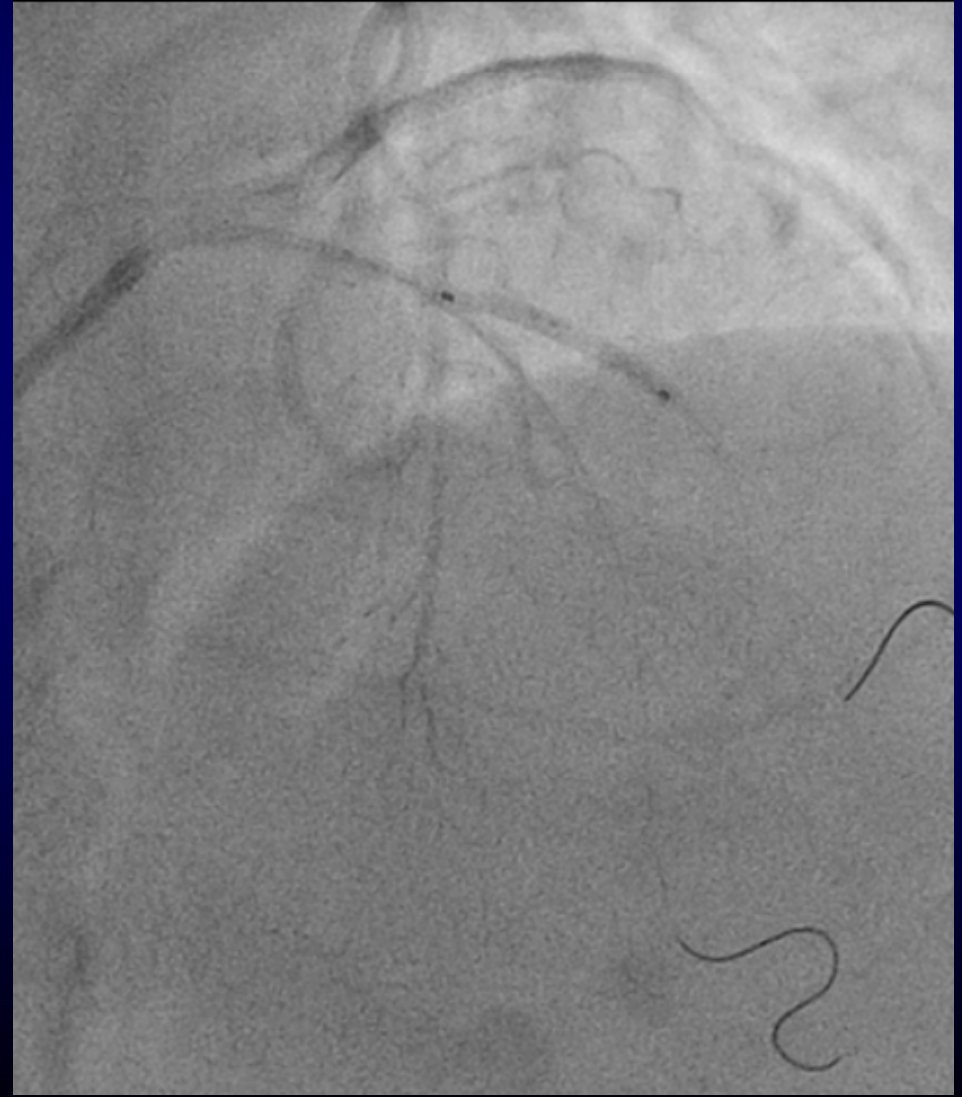
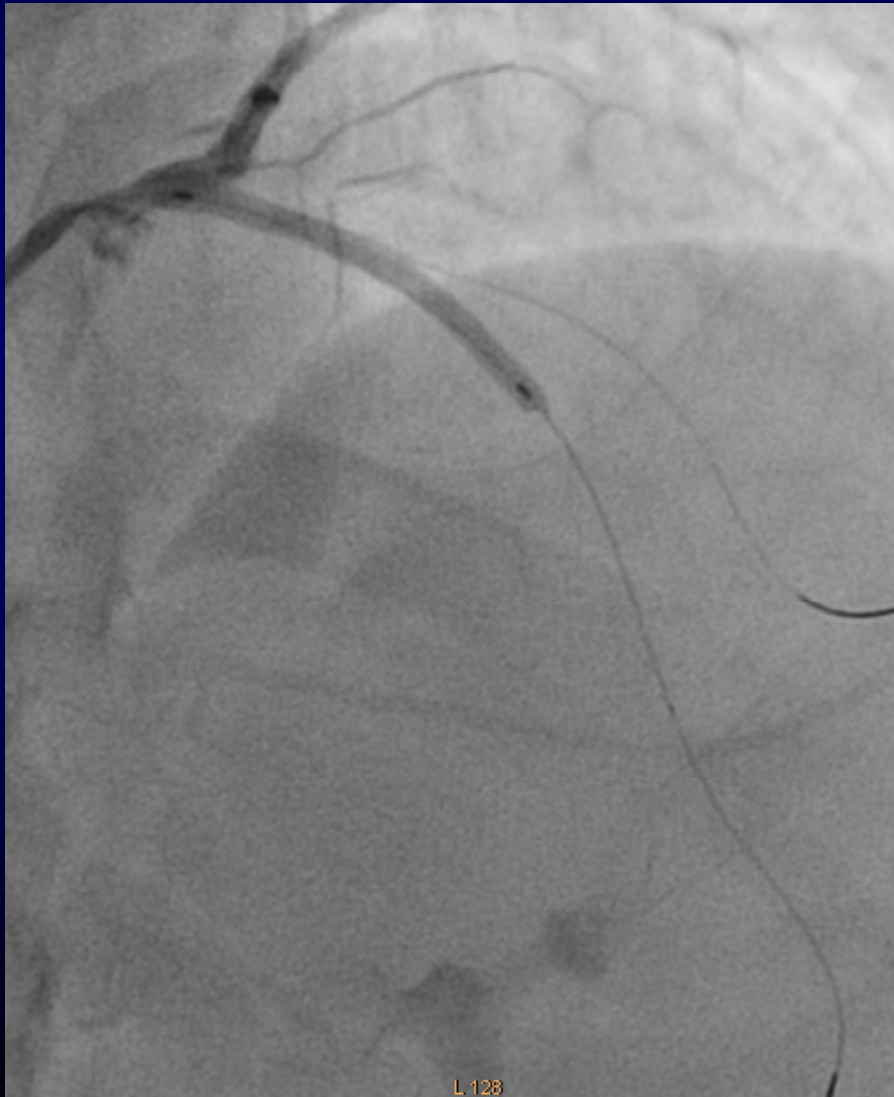

LAD - Sapphire II 2.5 x 20 mm at 12 Atm for 10 sec

D1 – Predilated with Sapphire II, 2.0 x 12

Primus (DEB) 2.0 x 25 mm at 8 Atm for 60 sec

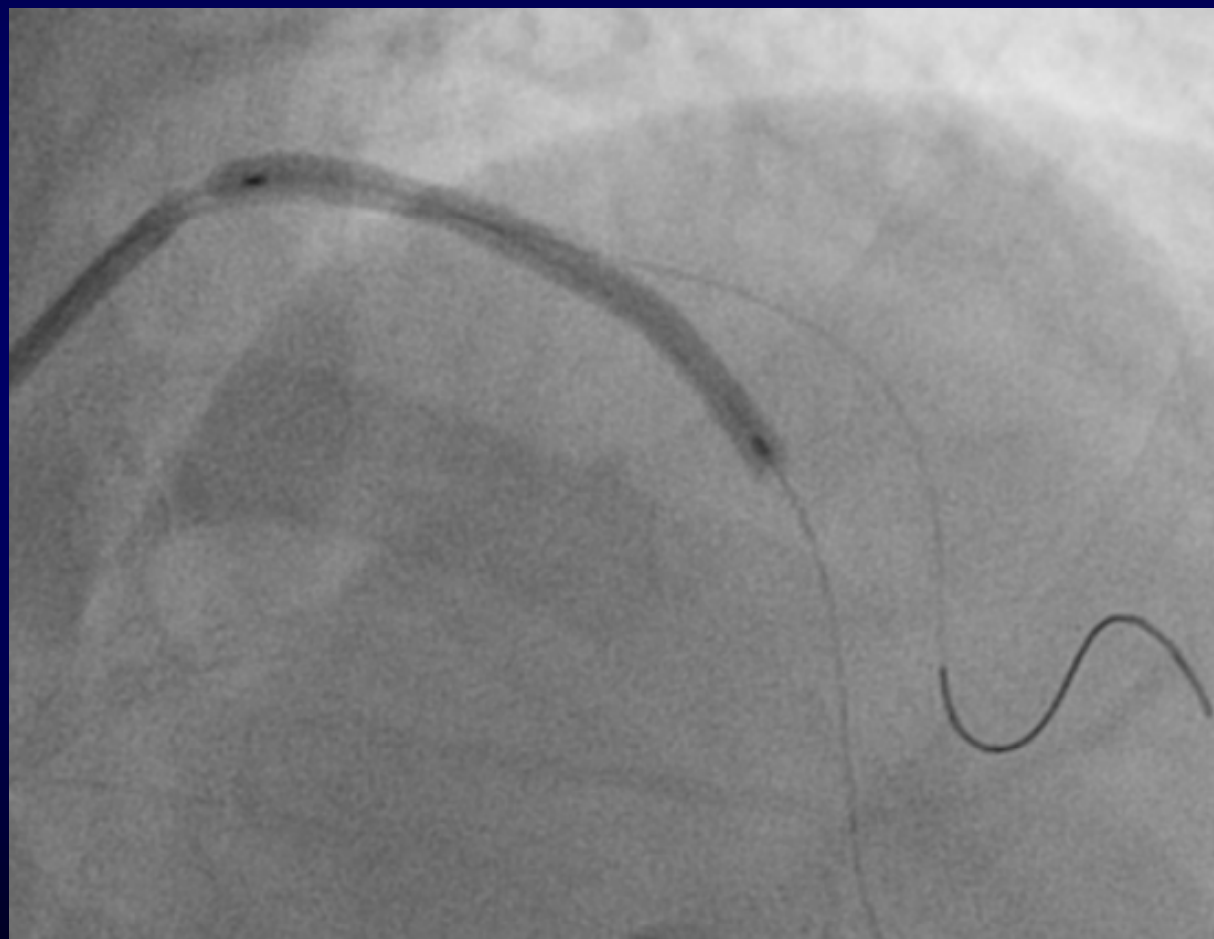
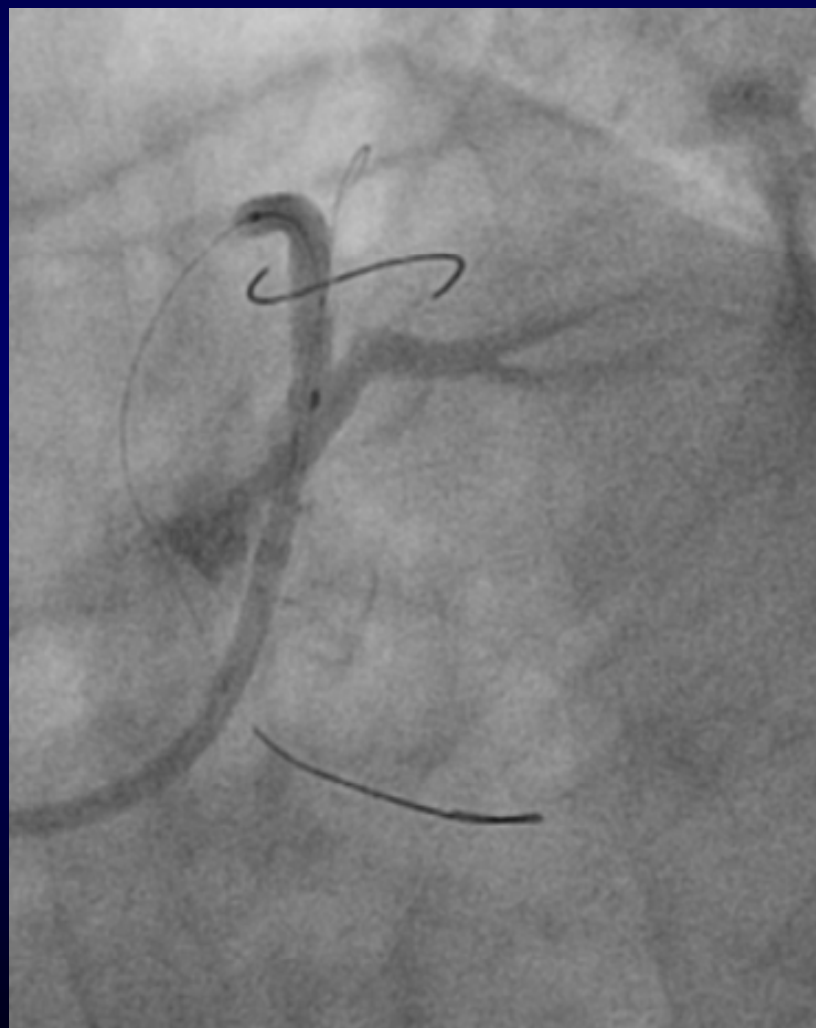
Had severe angina with dilatation of D1

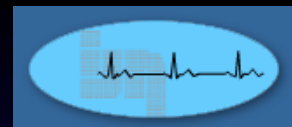




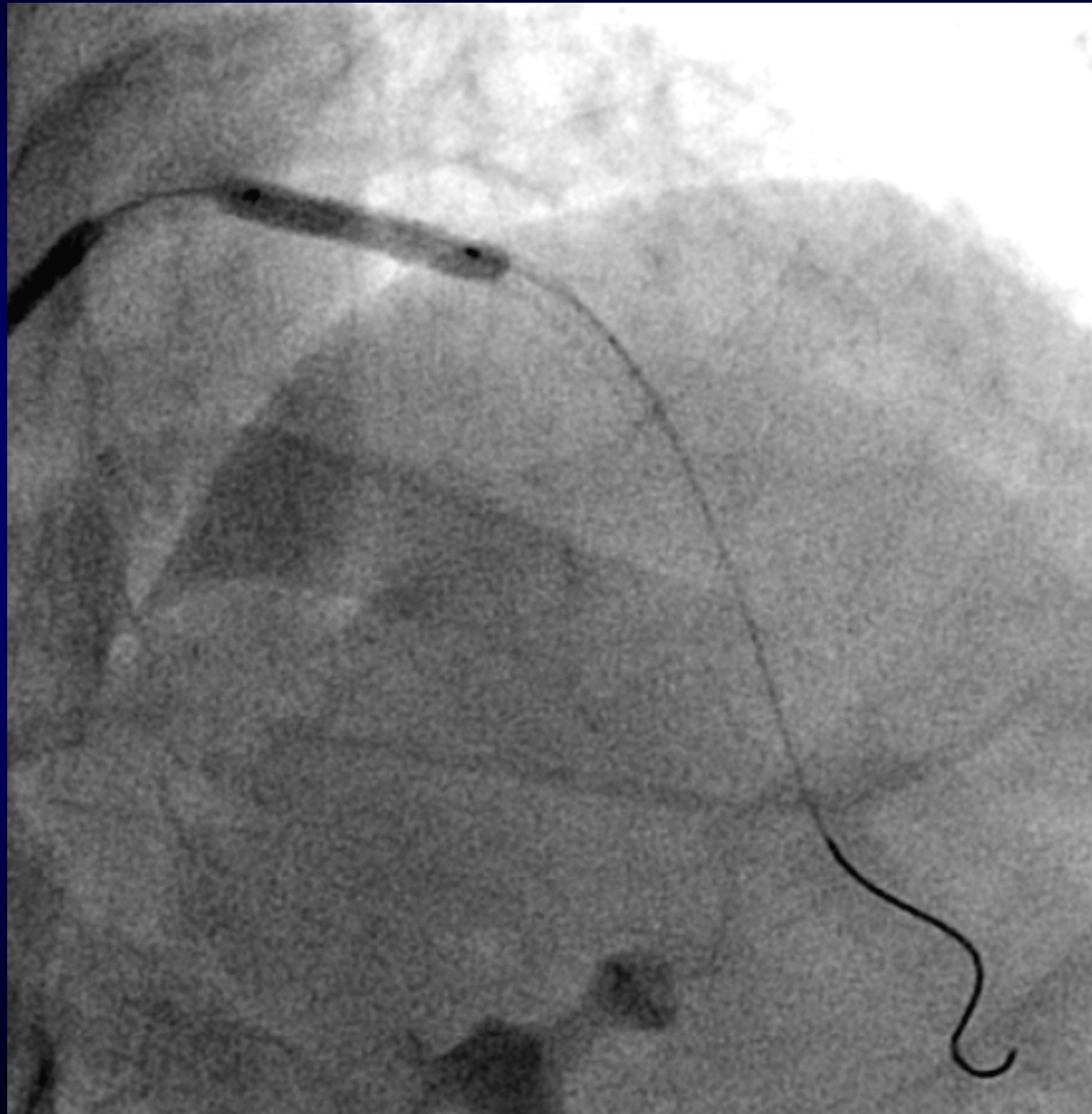
Stent LAD from ostium

Xiience Xpedition 2.75 x 38 mm at 18 Atm
(wire was not trapped)



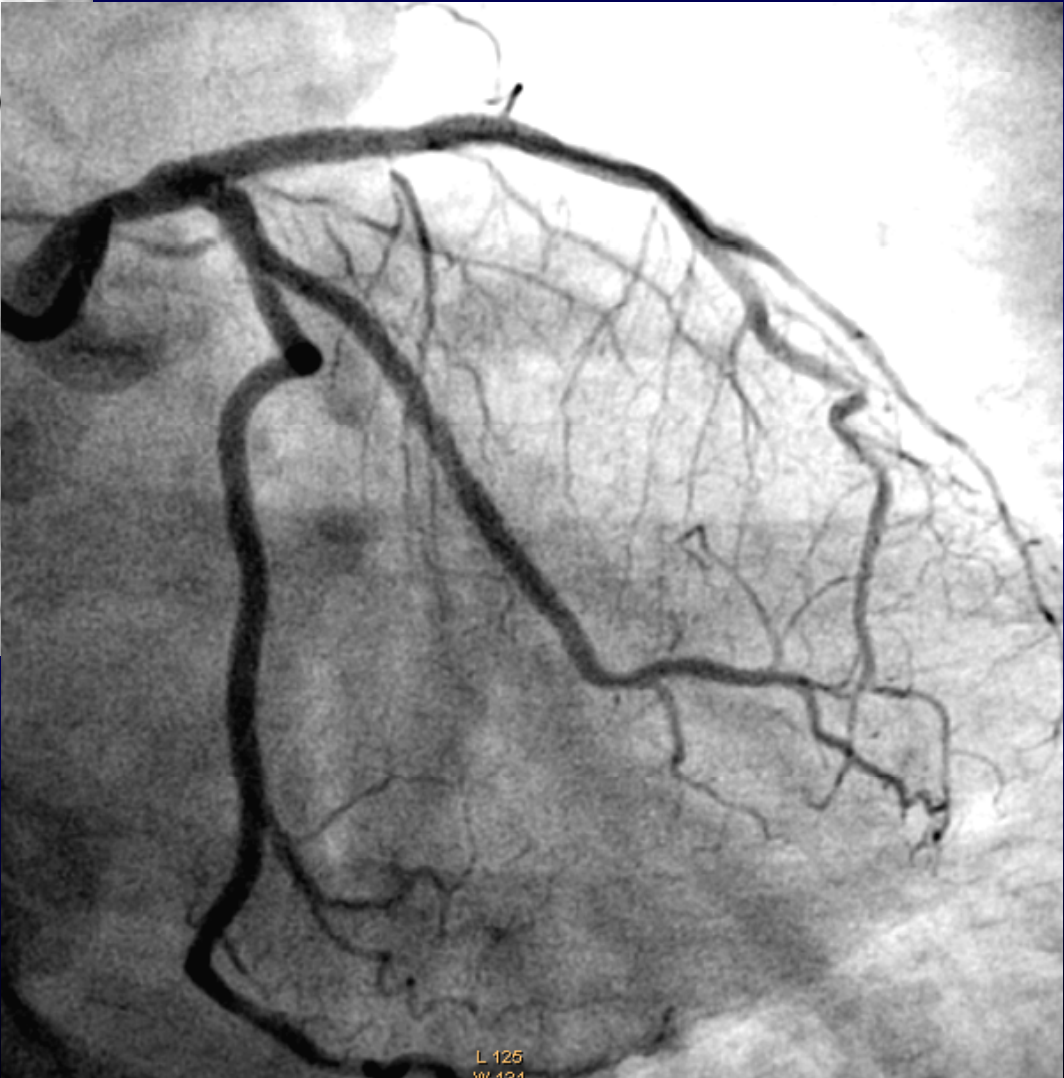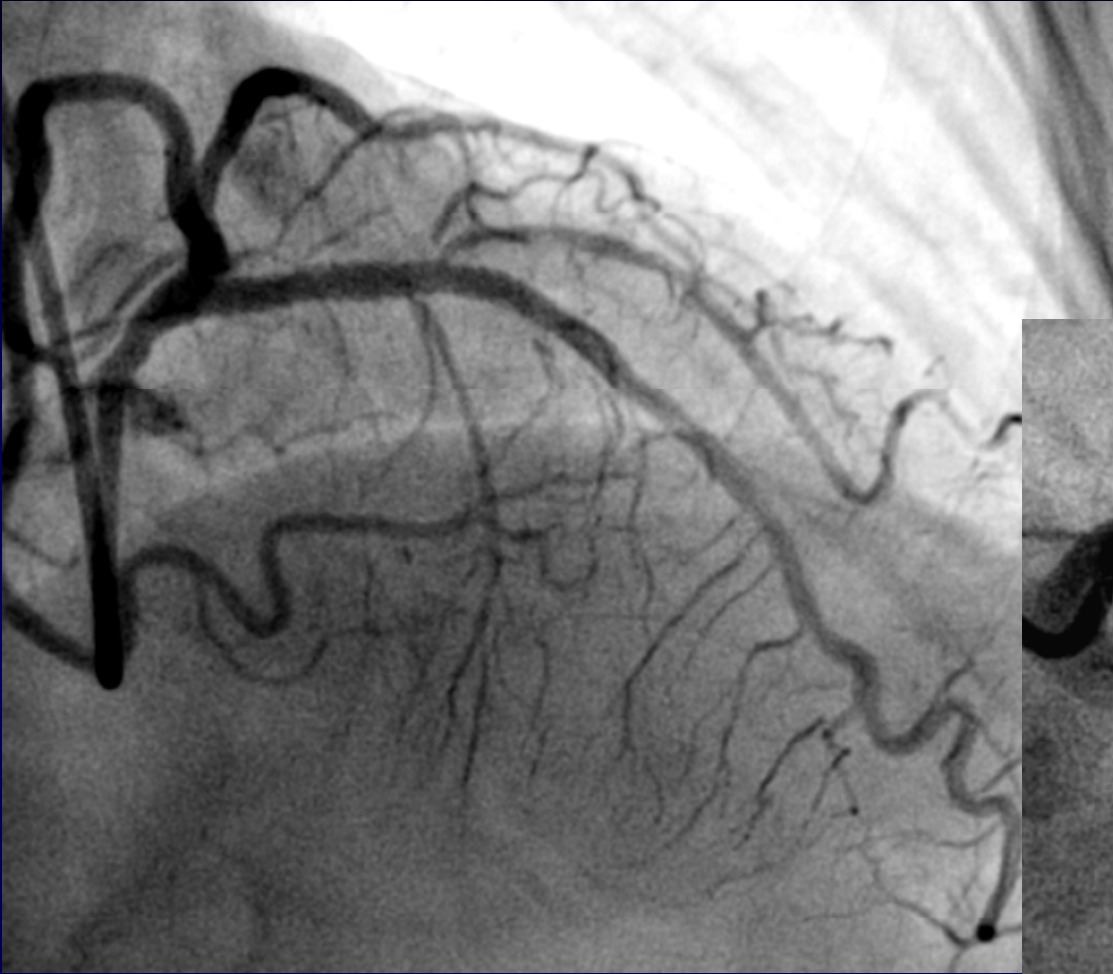


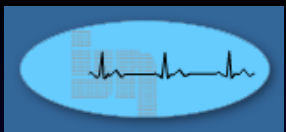
Post-dilate Sapphire NC 3.25 x 18 mm at 16 to 20 Atm



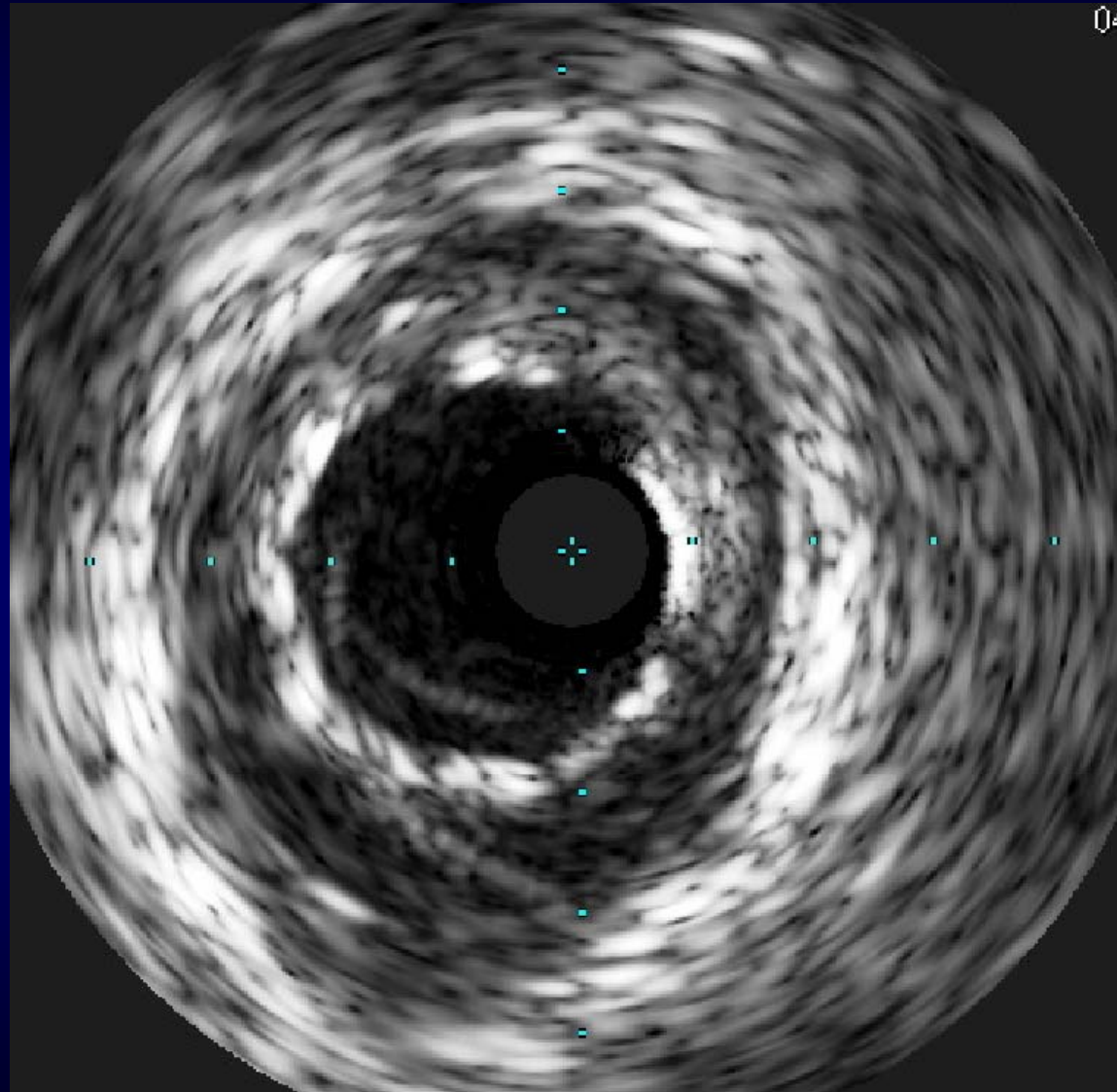


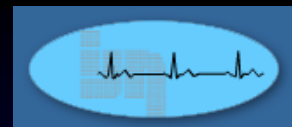
Post-PCI



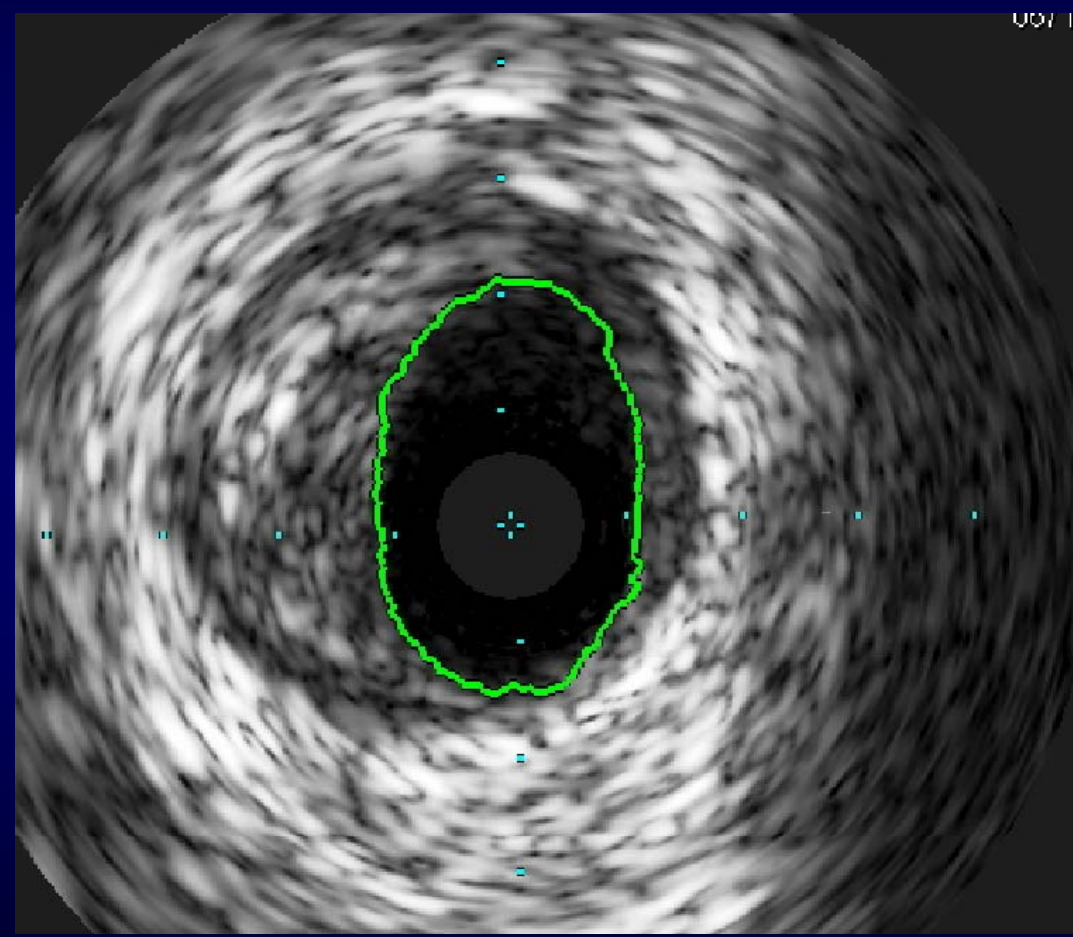
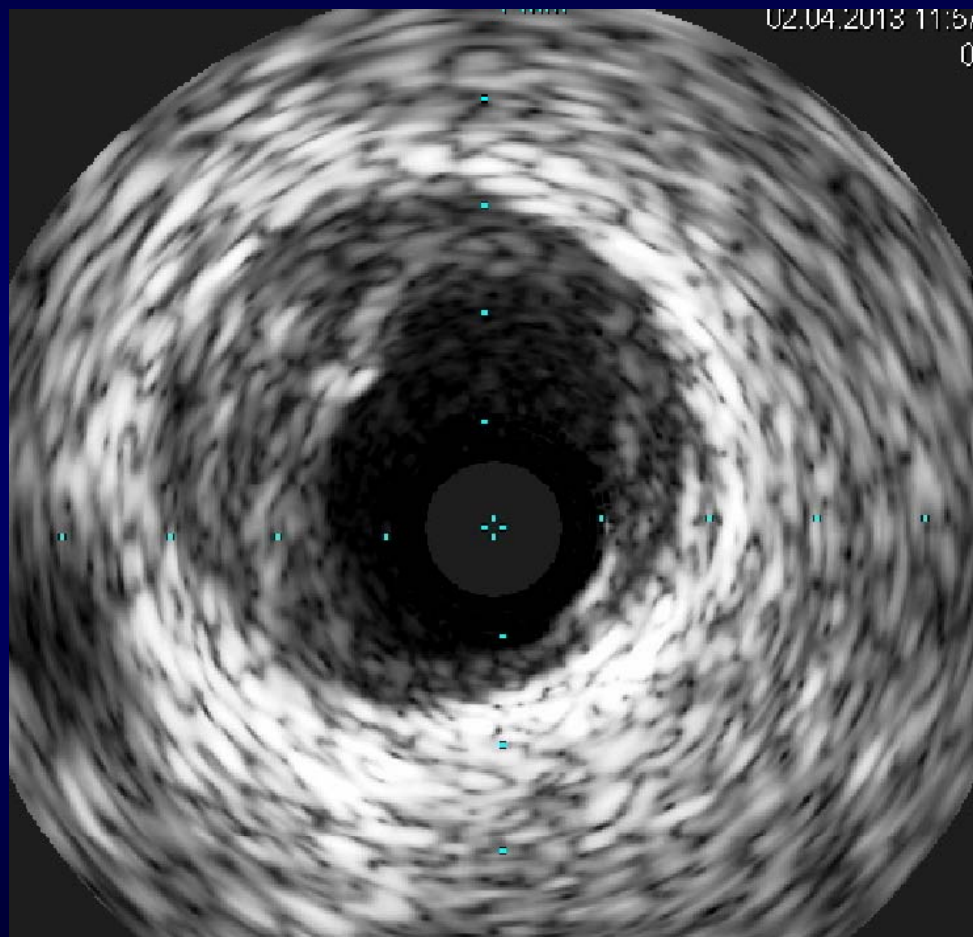


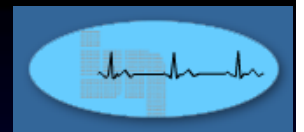
CSA Prox. LAD 7.8 mm²





CSA Distal LMS 6.4 mm²





Immediate Post PCI Pain Score 7/10

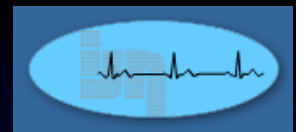
No pain the following morning

ECG – no new changes

Trop. T – 0.12 mcg/L (normal < 0.1)

Discharged well on 3rd April 2013

Already back to work overseas



Medications upon discharged:

1. Aspirin 75 mg om
2. Ticagrelor 90 mg bd
3. Bisoprolol 2.5 mg om
4. Perindopril 4 mg om
5. Atorvastatin 80 mg pm

Aim:

1. DAPT for one year
2. BP < 140/90
3. LDL-C < 2.0 mmol/L
4. Optimise ACE inhibitor & beta-blocker
5. Myocardial perfusion imaging TRO ischaemia for LMS lesion