OCT in the Evaluation of Vascular Healing Following DES Implantation: Will It Be a Helpful Tool to Reduce Stent Thrombosis?

Juan F. Granada, MD

Medical Director, Skirball Center for Cardiovascular Research

The Cardiovascular Research Foundation

Columbia University Medical Center, New York, NY

Columbia University Medical Center

NewYork-Presbyterian
The University Hospital of Columbia and Cornell

Cardiovascular Research Foundation

Why Do We Need to Perform Advanced Endovascular Imaging in Contemporaneous PCI?

Issue #1: Clinical Evidence (OCT) of Delayed Healing in Humans

Normal Healing in a Human in a Bare Metal Stent at 13 Months Follow Up

Abnormal Healing in a Human in a Cypher™ Stent at 6 Months Follow Up

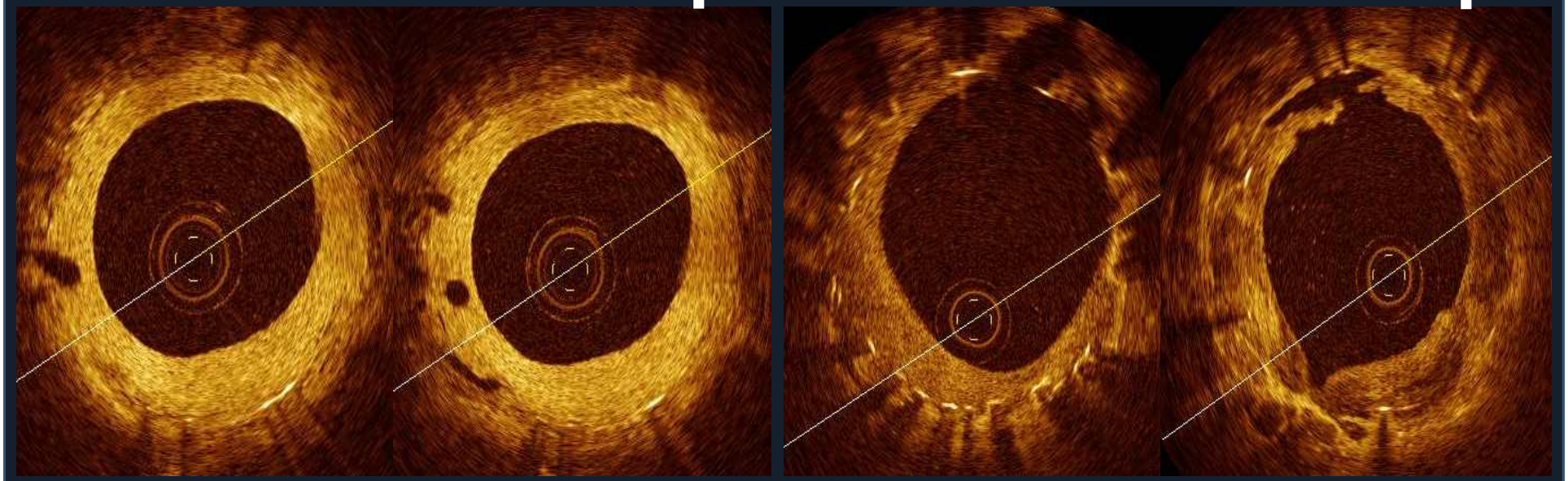

G. Guagliumi MD, Ospedali Riuniti di Bergamo

Issue #2: Pathological Correlates of Late DES Thrombosis

> 30 Days Implants

Uncovered

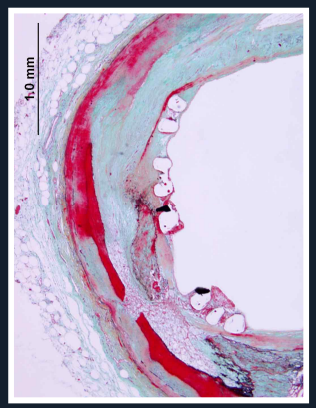

Covered

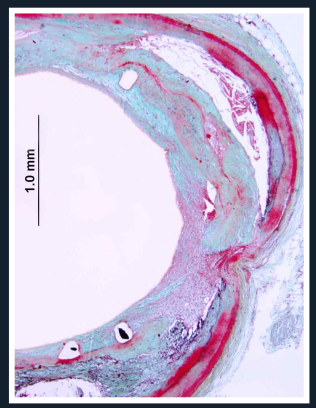

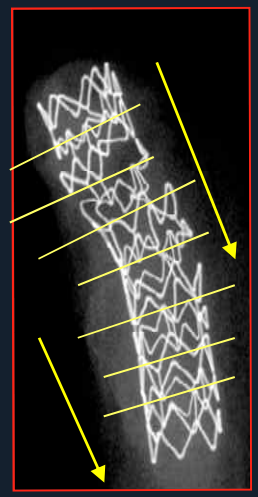

> 30 Days Implants

Uncovered

Covered

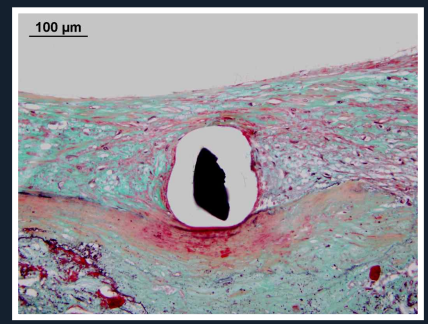

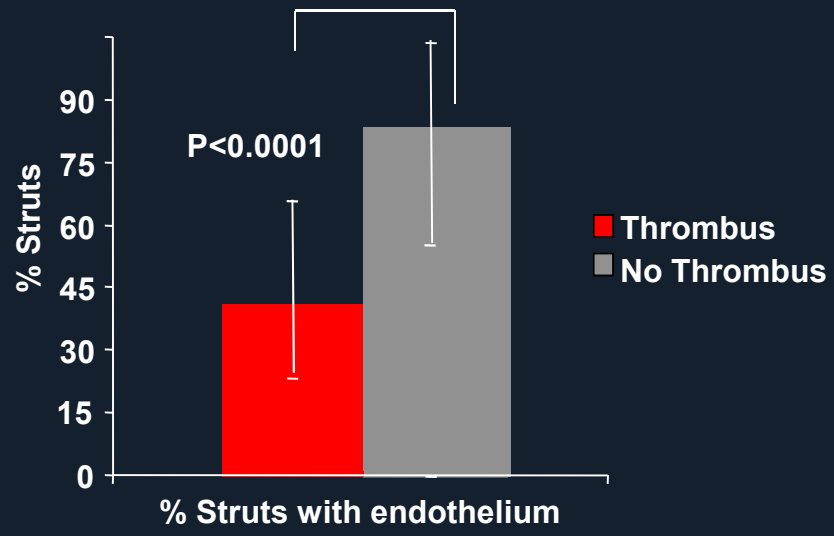

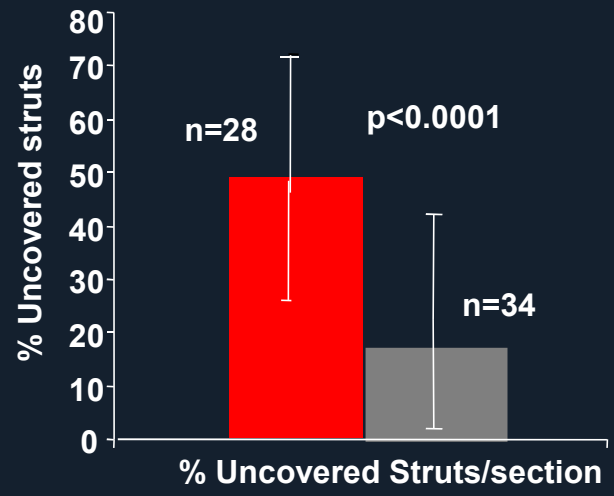

Columbia University Medical Center
NewYork-Presbyterian
The University Hospital of Columbia and Cornell

Cardiovascular Research Foundation

Finn AV, et al., Circulation 2007;115:2435-2441

Issue #3: Late Loss by QCA: Threshold for Detecting OCT-NT

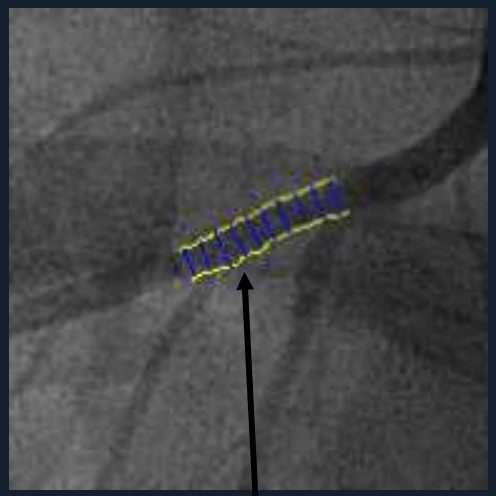

Segment 7

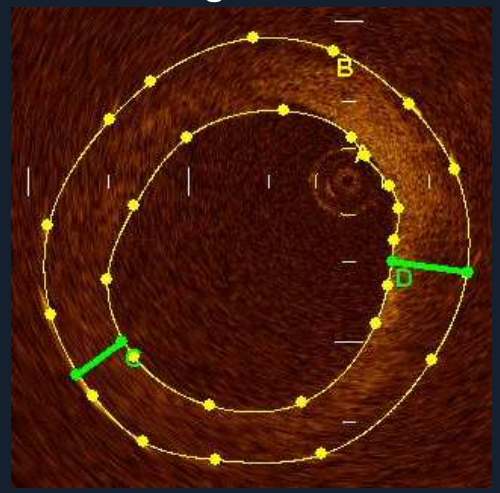

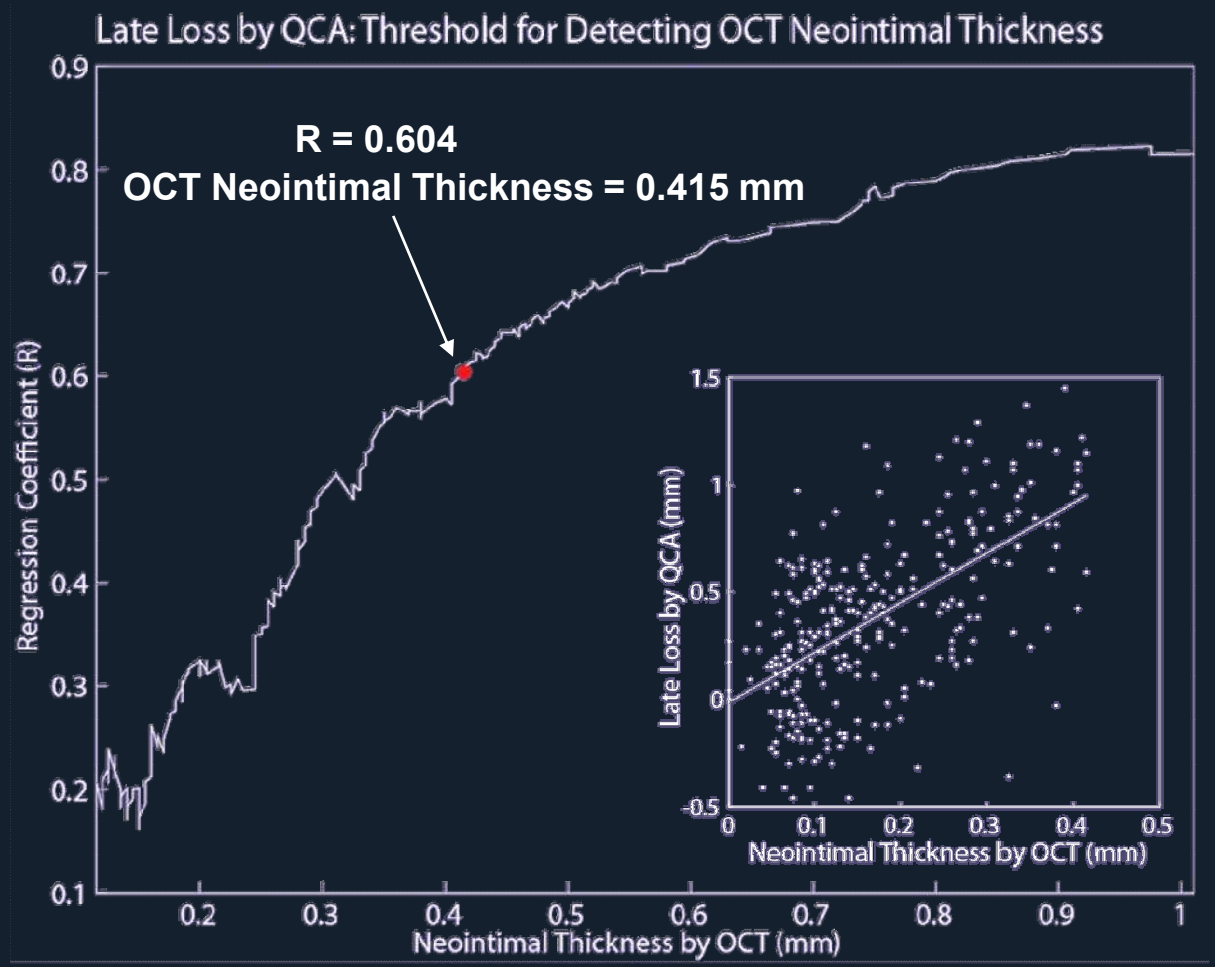

Wallace-Bradley D, Am J Card 2008, Vol 102 (8). TCT-54. 27i.

High Resolution Near Field Imaging of Stent and Peri-Stent Areas

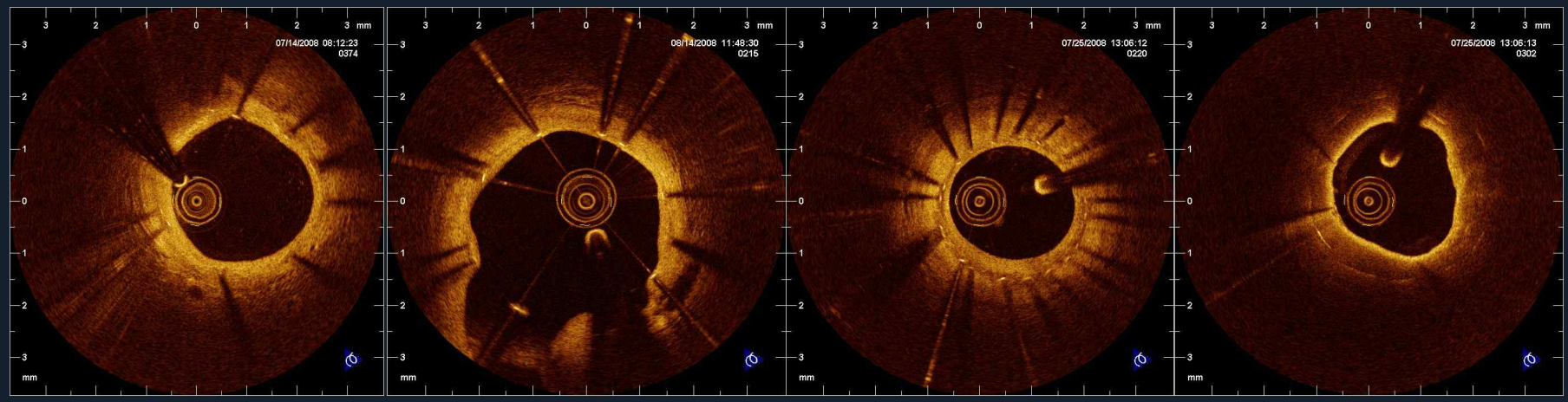

Homogeneous NI growth | Homogeneous NI growth | Inhomogeneous NI growth | Post balloon

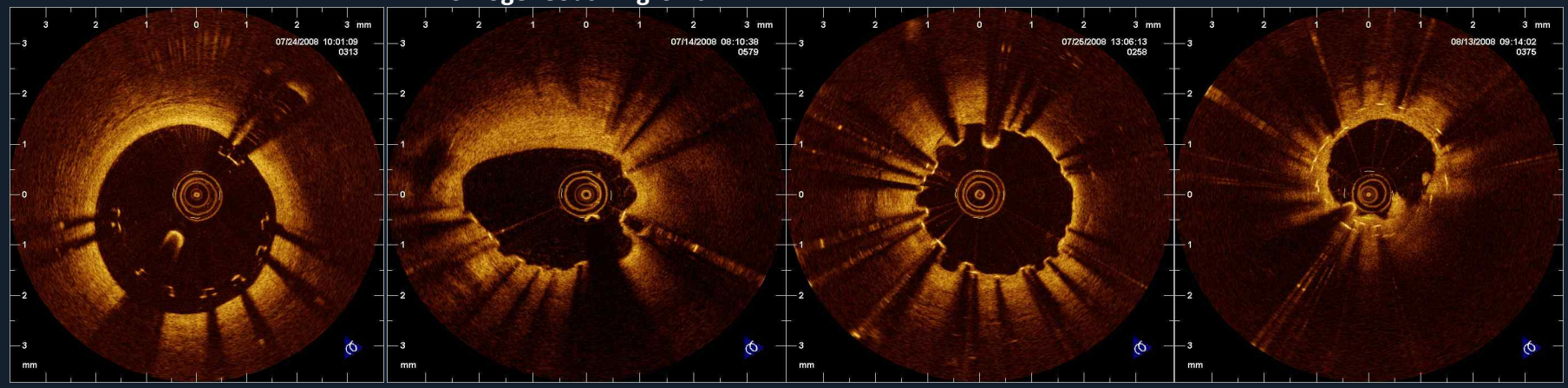

Malapposed uncovered struts | Malapposed covered struts | Malapposed covered struts | Malapposed struts w/ thrombus

Comparison of neointimal coverage of sirolimus-eluting stents and Paclitaxel eluting stents using optical coherence tomography at 9 months after implantation.

Kim JS, Kim JS, Kim TH, Fan C, Lee JM, Kim W, Ko YG, Choi D, Hong MK, Jang Y. Circ J. 2010 Feb;74(2):320-6.

Evaluation in 3 months duration of neointimal coverage after zotarolimus-eluting stent implantation by optical coherence tomography: the ENDEAVOR OCT trial.

Kim JS, Jang IK, Fan C, Kim TH, Kim JS, Park SM, Choi EY, Lee SH, Ko YG, Choi D, Hong MK, Jang Y. JACC Cardiovasc Interv. 2009 Dec;2(12):1240-7.

An optical coherence tomography study of a biodegradable vs. durable polymer-coated limus-eluting stent: a LEADERS trial sub-study.

Barlis P, Regar E, Serruys PW, Dimopoulos K, van der Giessen WJ, van Geuns RJ, Ferrante G, Wandel S, Windecker S, van Es GA, Eerdmans P, Jüni P, di Mario C. Eur Heart J. 2010 Jan;31(2):165-76.

Incomplete stent apposition and delayed tissue coverage are more frequent in drug-eluting stents implanted during primary percutaneous coronary intervention for ST-segment elevation myocardial infarction than in drug-eluting stents implanted for stable/unstable angina: insights from optical coherence tomography.

Gonzalo N, Barlis P, Serruys PW, Garcia-Garcia HM, Onuma Y, Ligthart J, Regar E. JACC Cardiovasc Interv. 2009 May;2(5):445-52.

How Could OCT Evaluate Vascular Healing Following DES Implantation?

1. Assessing the ***amount of neointimal tissue*** formed on the surface of the strut.
2. Quantifying the ***number of stent struts*** that are properly covered.
3. Assessing the degree of ***functional stent coverage***.
4. Characterizing the ***tissue type*** covering the struts (i.e., fibrin).

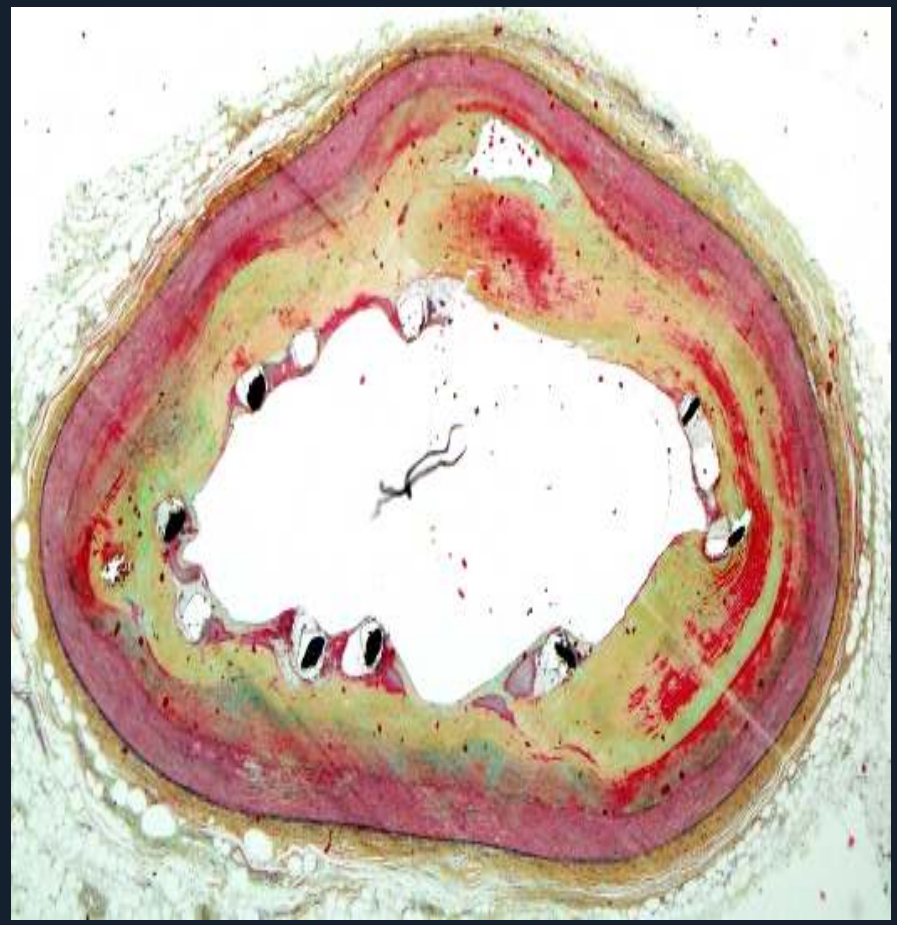

Picture courtesy of Renu Virmani

Evaluation of Vascular Healing Using OCT Following DES Implantation

A Histology Correlation Study in Swine

- 14 Swine, 42 Stents (11 Vision, 11 Xience, 10 Endeavor, 10 Taxus)
- OCT acquisition: LightLab Imaging, time domain OCT, 1300nm, reported resolution of 15 um, pullbacks obtained at 1mm/sec, 15.6Hz frame rate:
  - *396 total frames analyzed (143 matched with histology)*
  - Second observer for intra- and interobserver variability
  - Measured: NA, %AS, NT, uncovered and covered struts
- Histology analysis:
  - Sectioned to correspond with OCT, stained with H&E and van Gieson's
  - Histomorphometry: Neointimal area, %AS, NT, uncovered and covered struts
  - SEM: overall assessment of lumen coverage and endothelialization

Murata A. JACC Cardiovasc Imaging. 2010 Jan;3(1):76-84.

Analysis of Neointimal Area Using OCT in Different DES (28 Days)

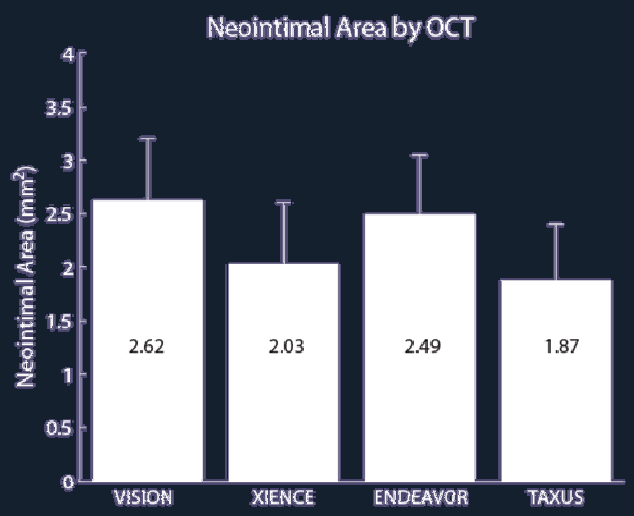

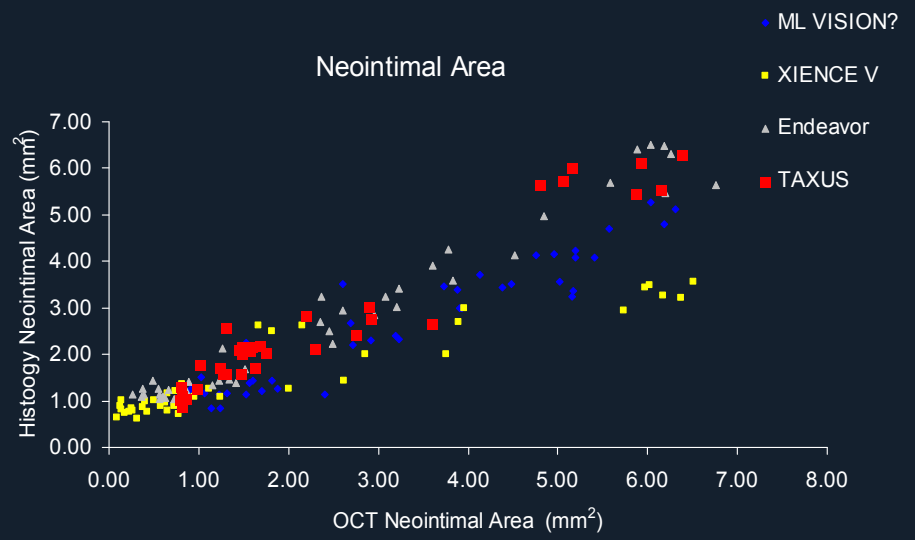

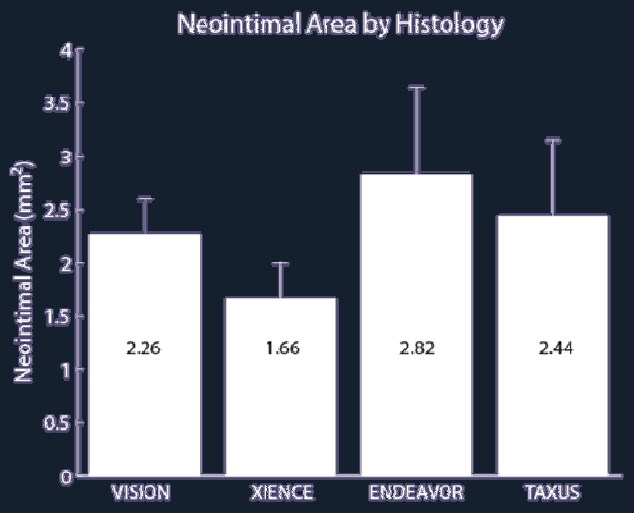

Neointima		Correlation Coefficient	95% Confidence Interval
	Endeavor	0.9821	0.9667, 0.9904
	TAXUS	0.9667	0.9339, 0.9834
	ML VISION	0.9546	0.9190, 0.9748
	XIENCE V	0.9302	0.8712, 0.9628

Columbia University Medical Center
NewYork-Presbyterian
The University Hospital of Columbia and Cornell
Cardiovascular Research Foundation

Murata A. JACC Cardiovasc Imaging. 2010 Jan;3(1):76-84.

Analysis of %AS Using OCT in Different DES Types (28 Days)

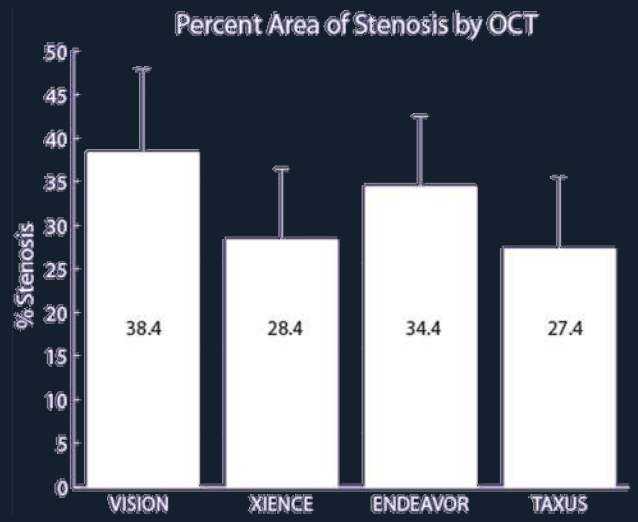

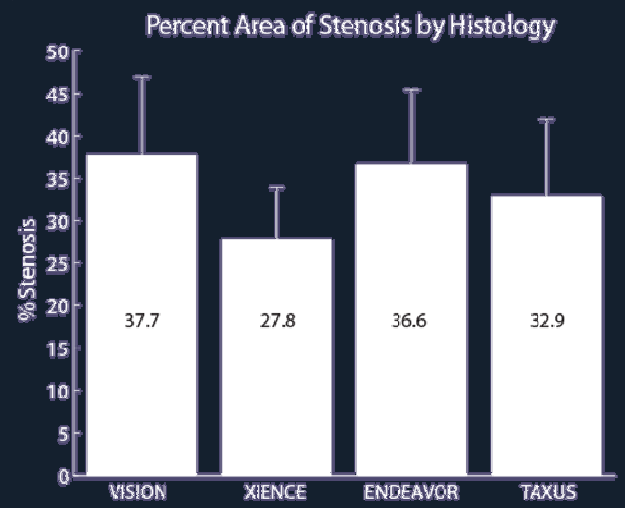

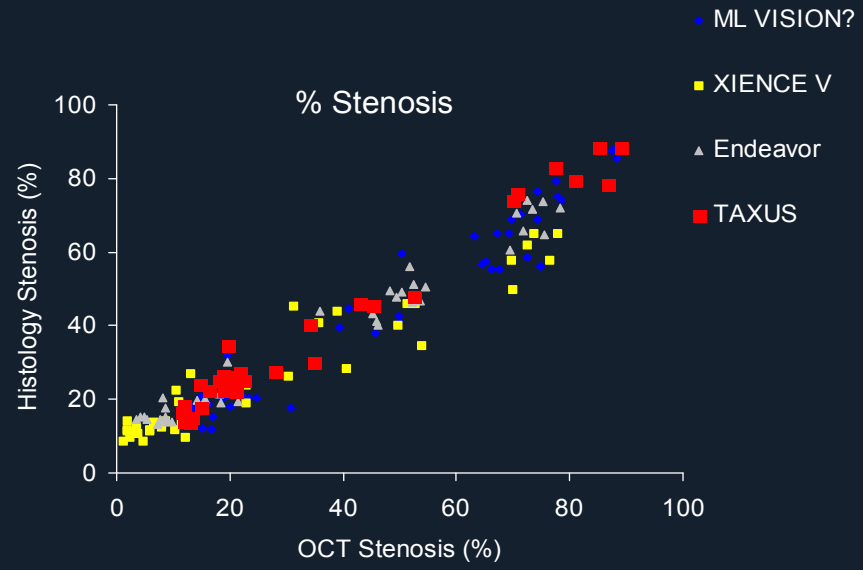

% Stenosis		Correlation Coefficient	95% Confidence Interval
	Endeavor	0.984	0.9702, 0.9914
	TAXUS	0.9867	0.9730, 0.9935
	VISION	0.9748	0.9549, 0.9859
	XIENCE V	0.96	0.9252, 0.9788

Columbia University Medical Center
NewYork-Presbyterian
The University Hospital of Columbia and Cornell
Cardiovascular Research Foundation

Murata A. JACC Cardiovasc Imaging. 2010 Jan;3(1):76-84.

Analysis of Neointimal Thickness Using OCT in Different DES (28 Days)

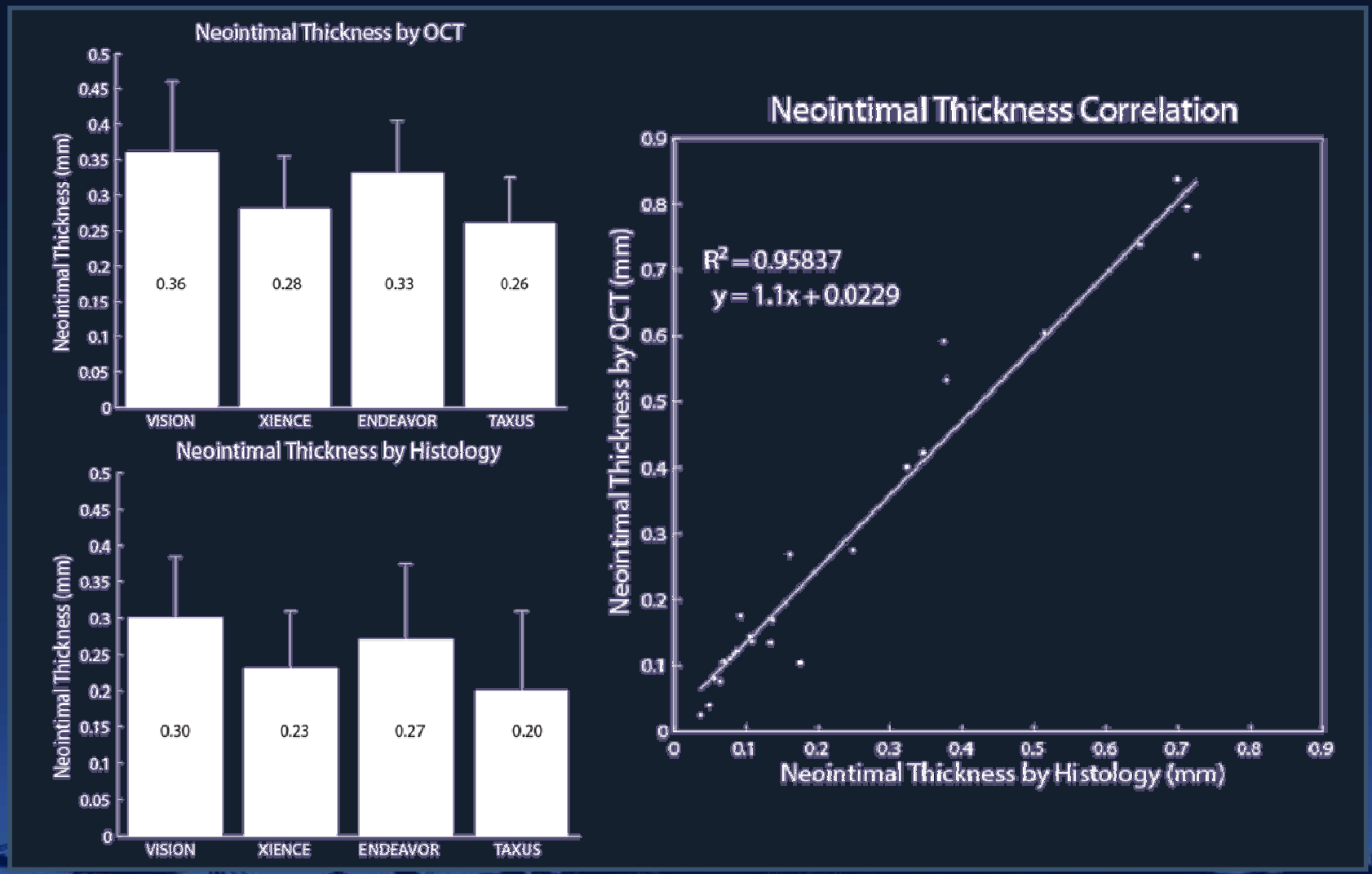

Columbia University Medical Center
NewYork-Presbyterian
The University Hospital of Columbia and Cornell
Cardiovascular Research Foundation

Murata A. JACC Cardiovasc Imaging. 2010 Jan;3(1):76-84.

Analysis of Stent Area Using OCT in Different DES Types (28 Days)

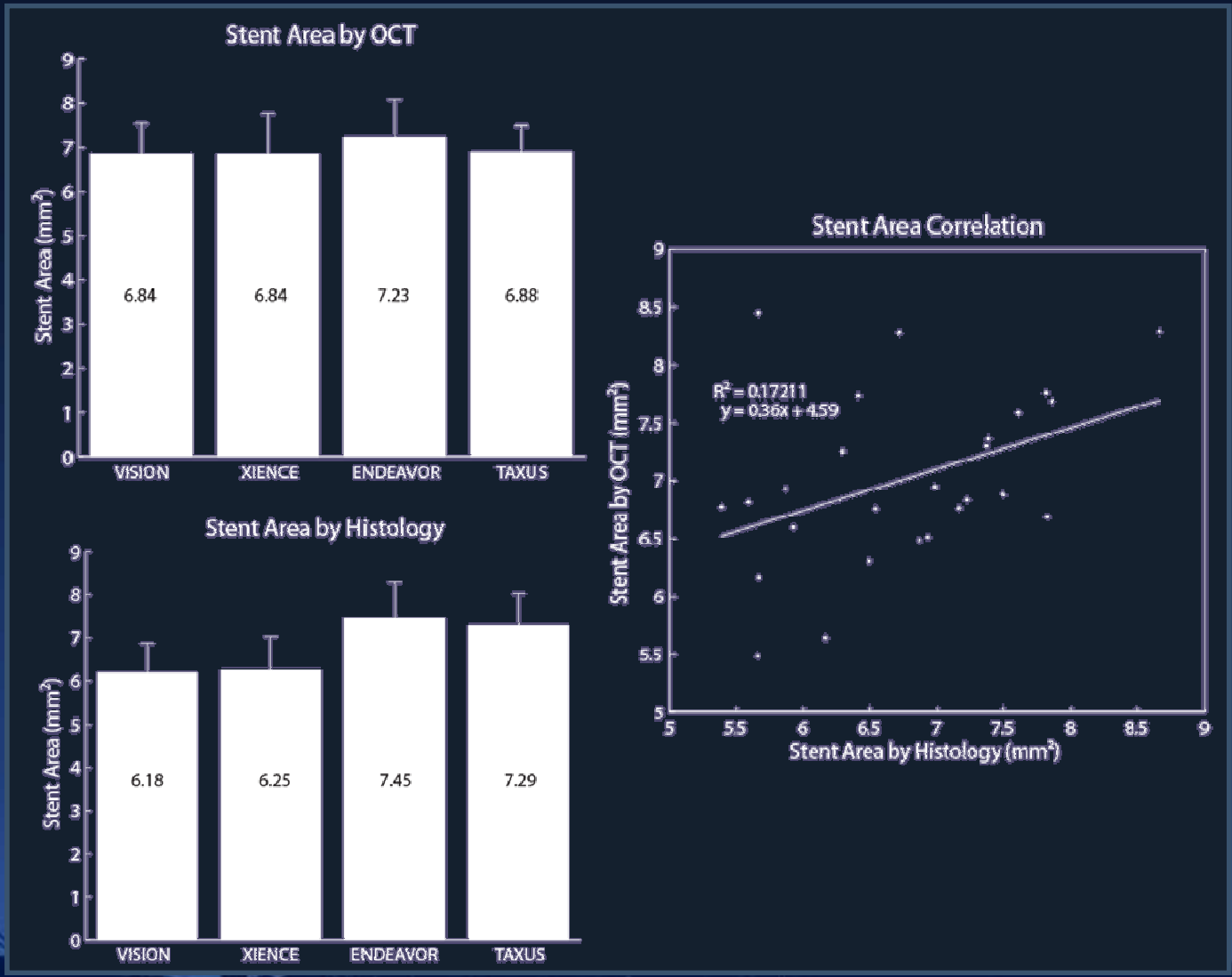

Columbia University Medical Center
NewYork-Presbyterian
The University Hospital of Columbia and Cornell
Cardiovascular Research Foundation

Murata A. JACC Cardiovasc Imaging. 2010 Jan;3(1):76-84.

Challenges of Evaluation of Stent Area : OCT *versus* Histology

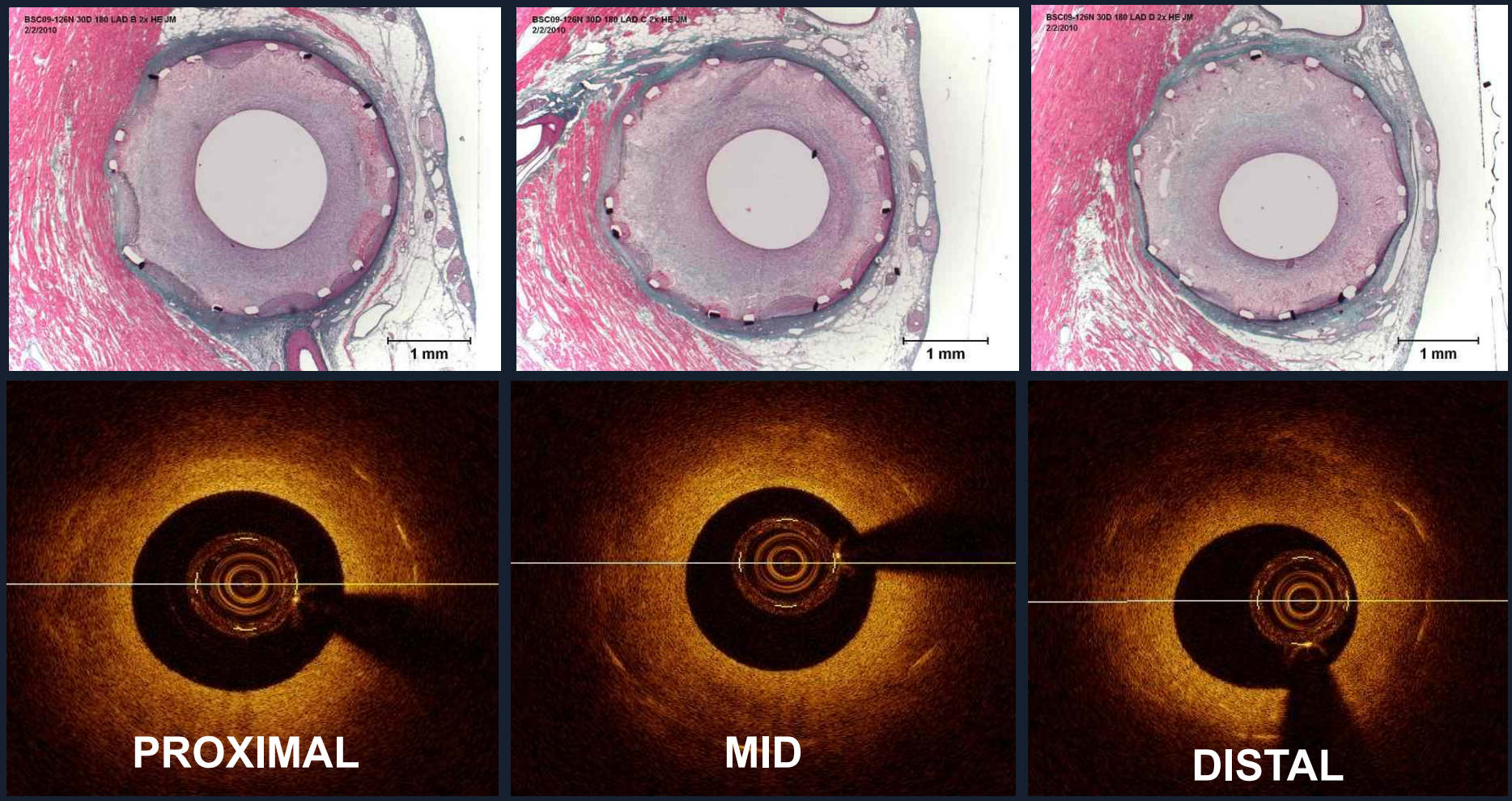

OCT Intra-Observer Variability

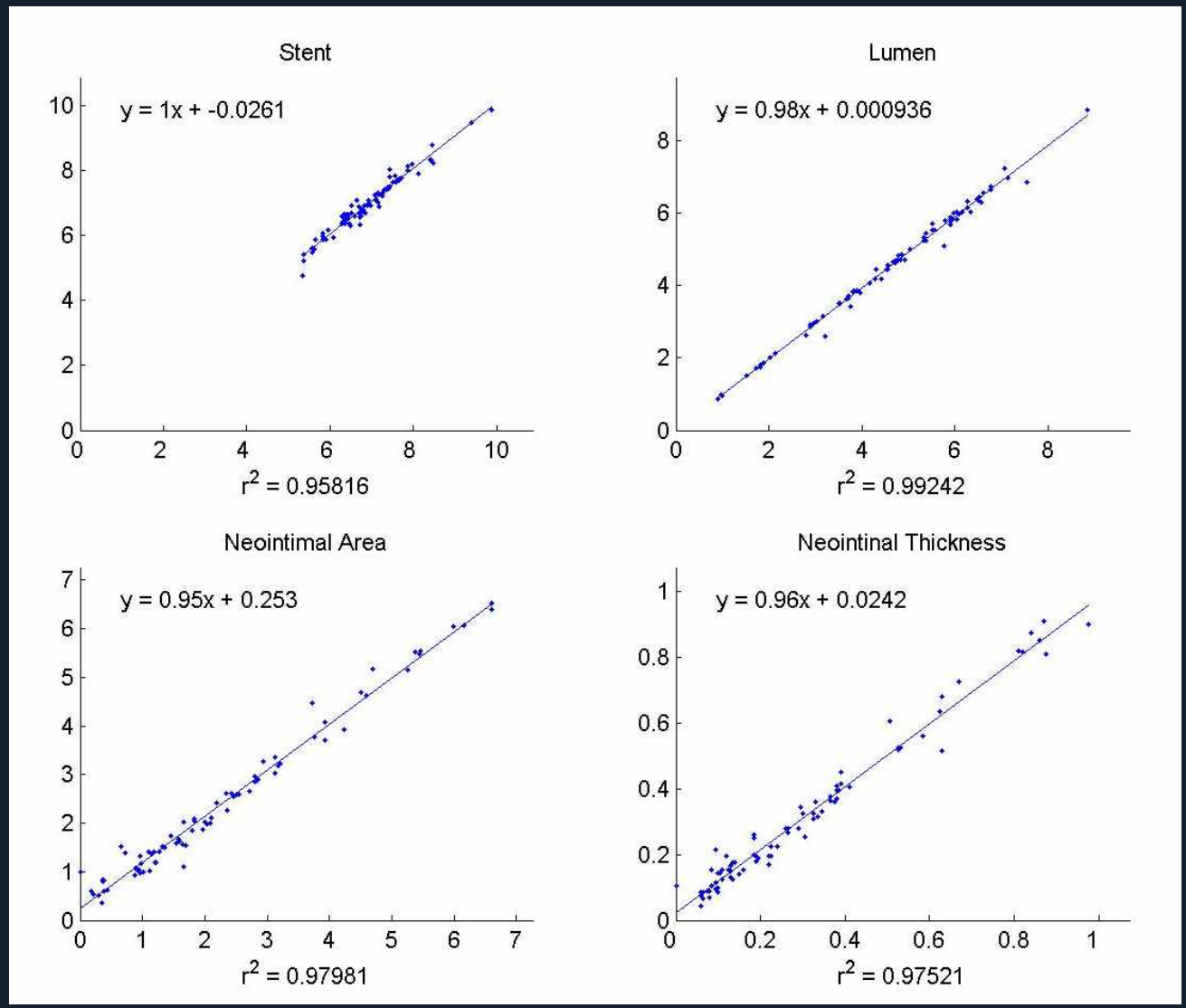

Murata A. JACC Cardiovasc Imaging. 2010 Jan;3(1):76-84.

OCT Inter-Observer Variability

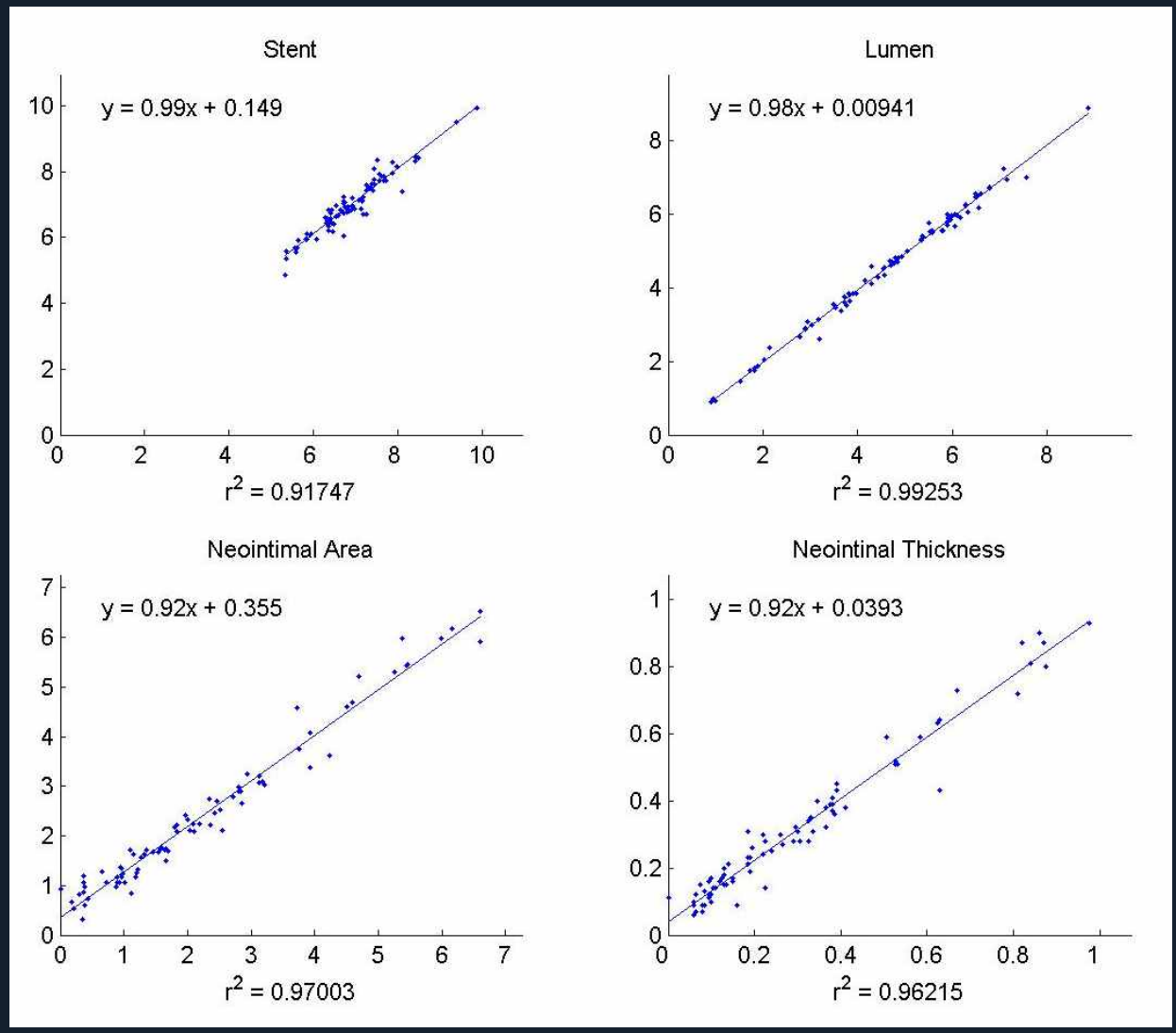

Murata A. JACC Cardiovasc Imaging. 2010 Jan;3(1):76-84.

Evaluation of Peri-Strut Coverage: OCT *versus* Histology

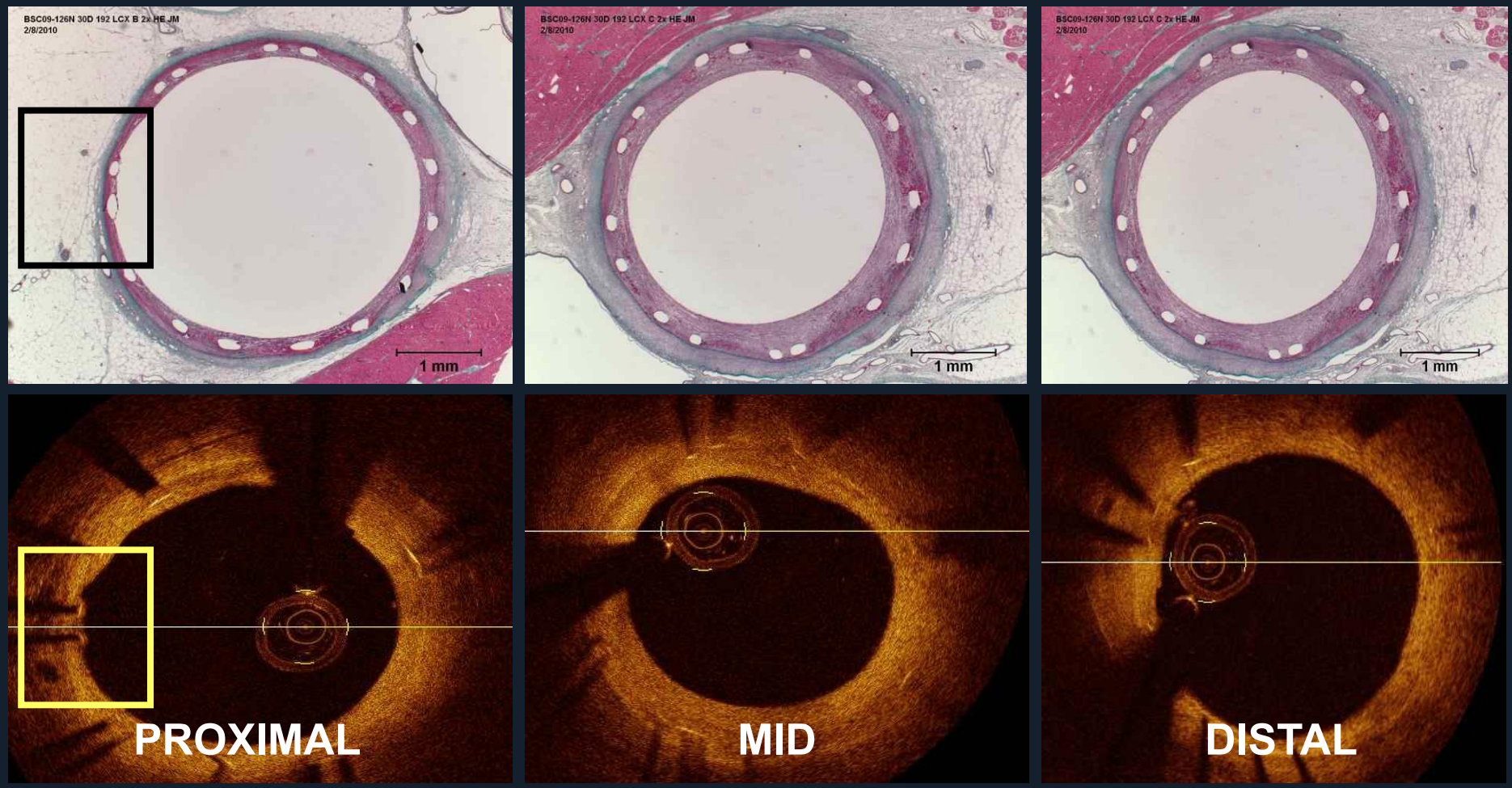

OCT Evaluation of Strut Coverage Following DES Implantation

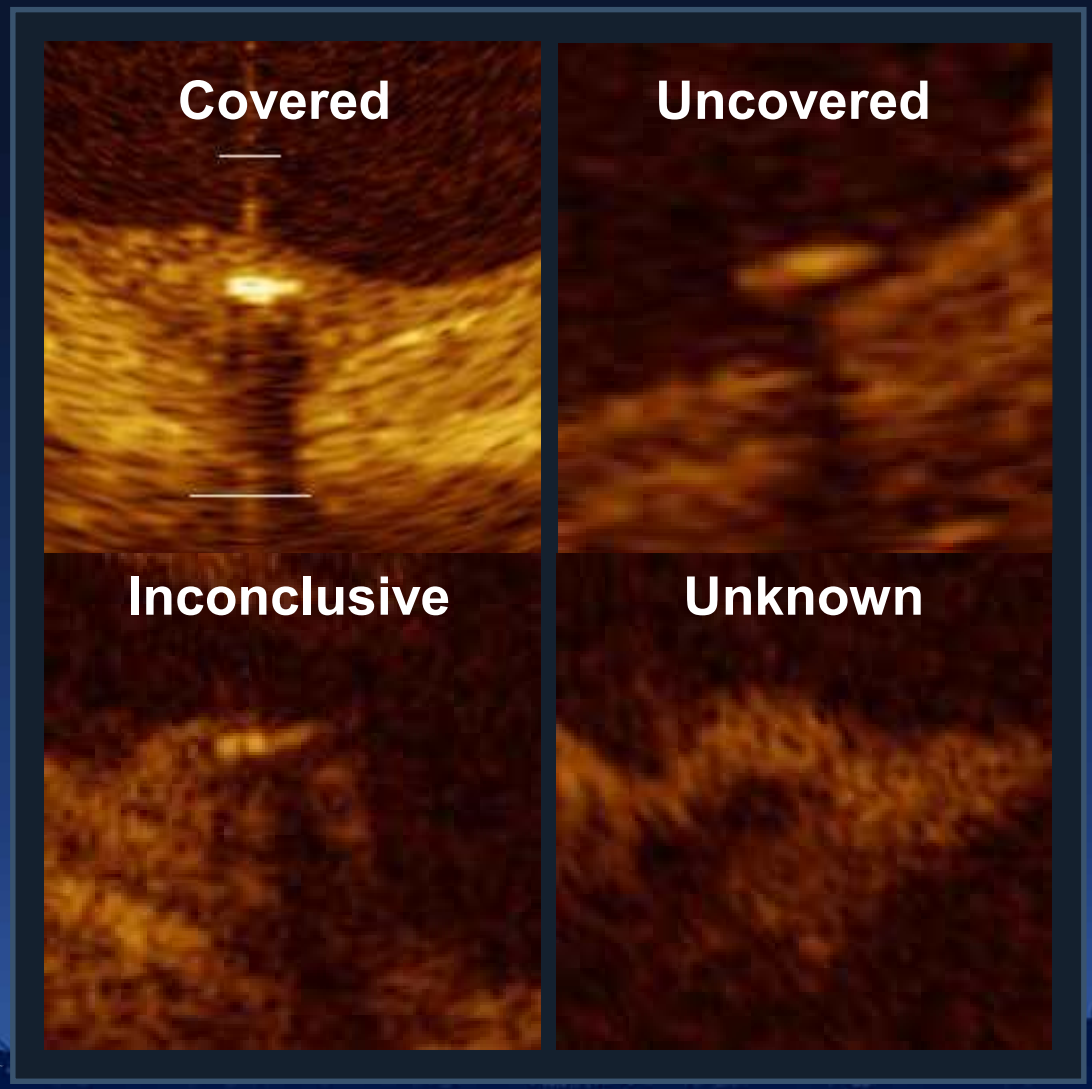

Analysis of Strut Coverage Using OCT in Different DES Types (28 Days)

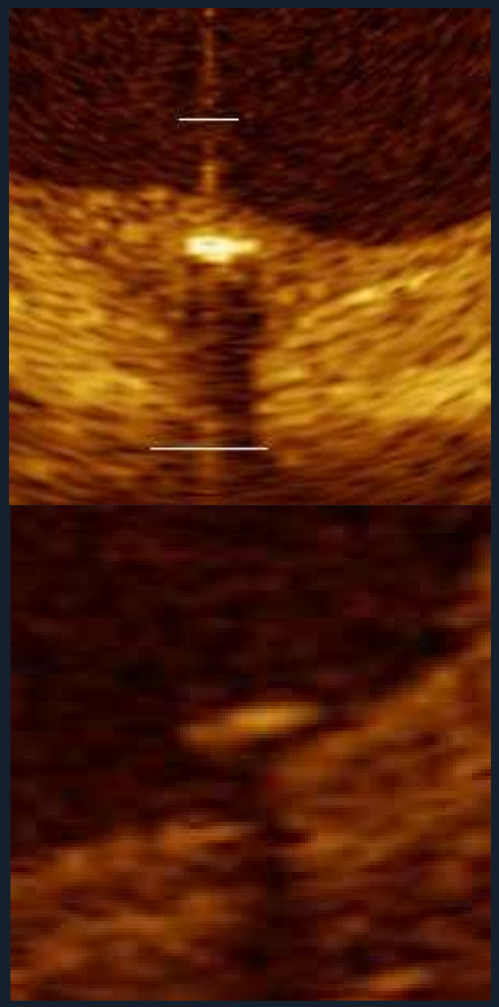

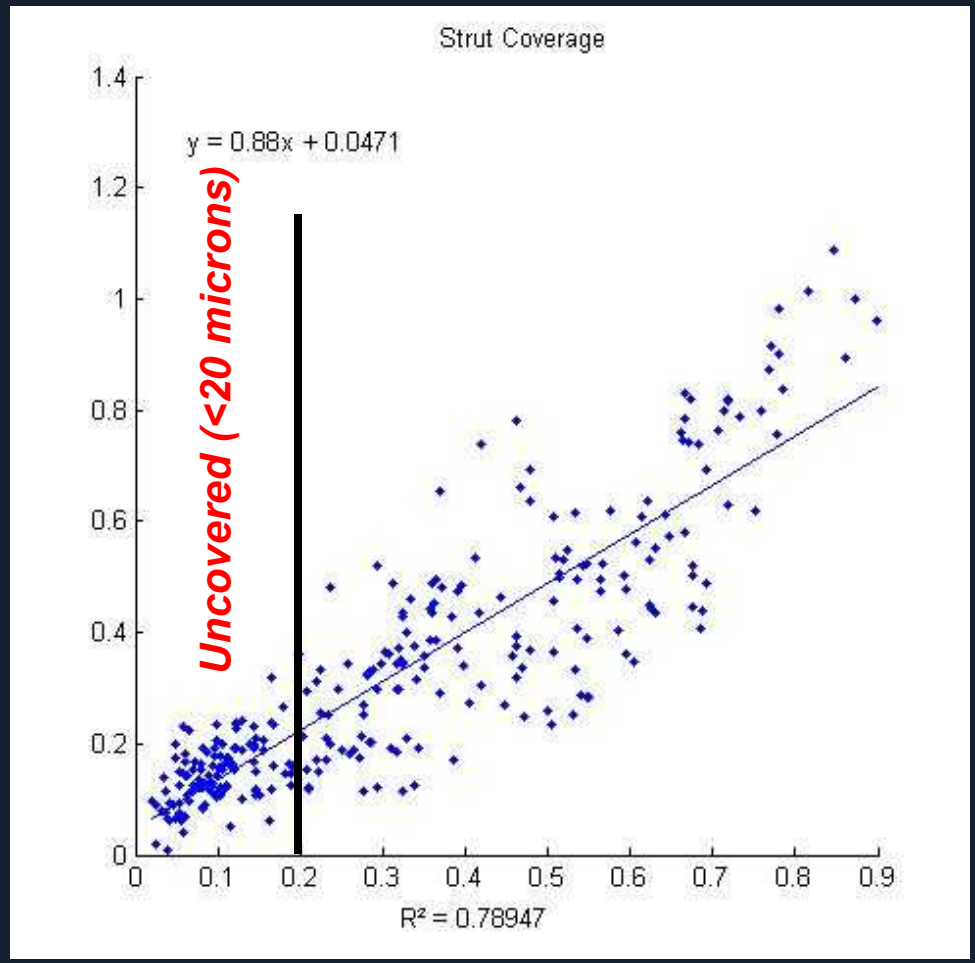

Proportion of Neointimal Thickness by OCT & Histology in DES: Implications for Individual Strut Coverage Analysis

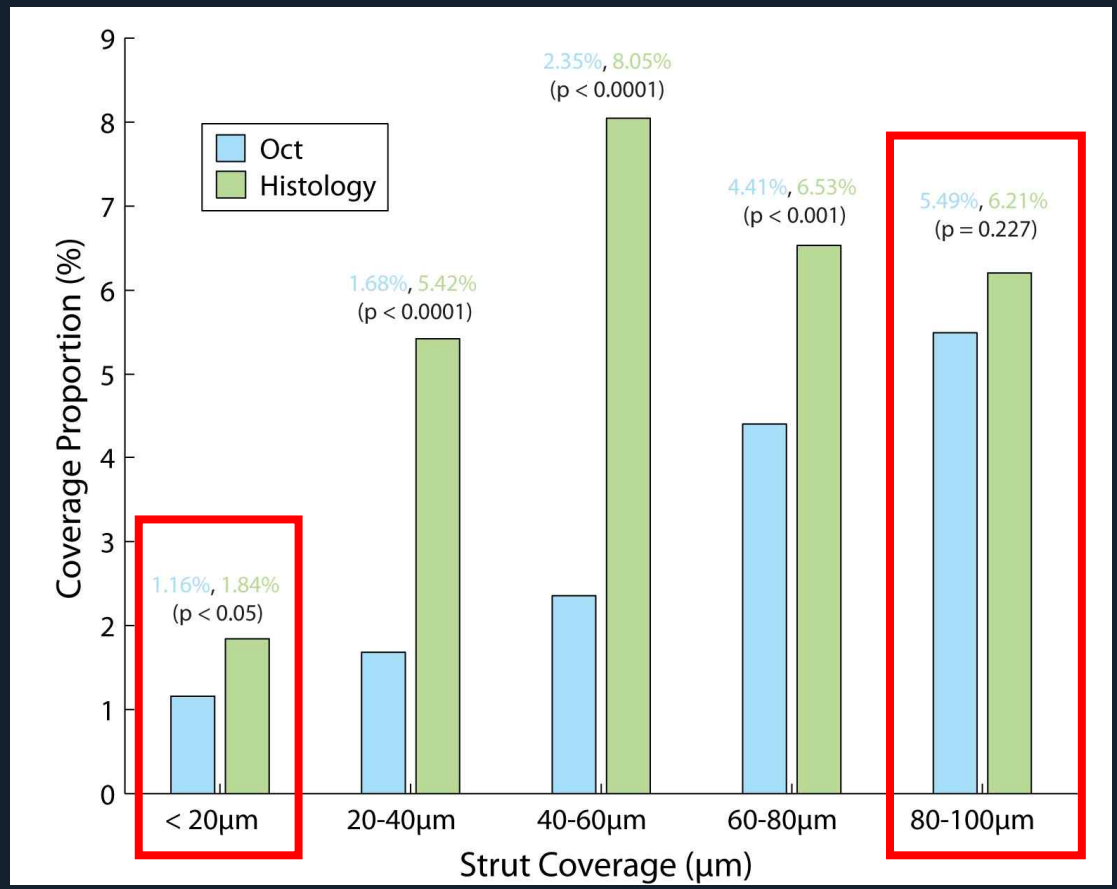

Murata A. JACC Cardiovasc Imaging. 2010 Jan;3(1):76-84.

Patterns of Strut Coverage Overtime

OCT Analysis BMS vs. DES at 4 Days

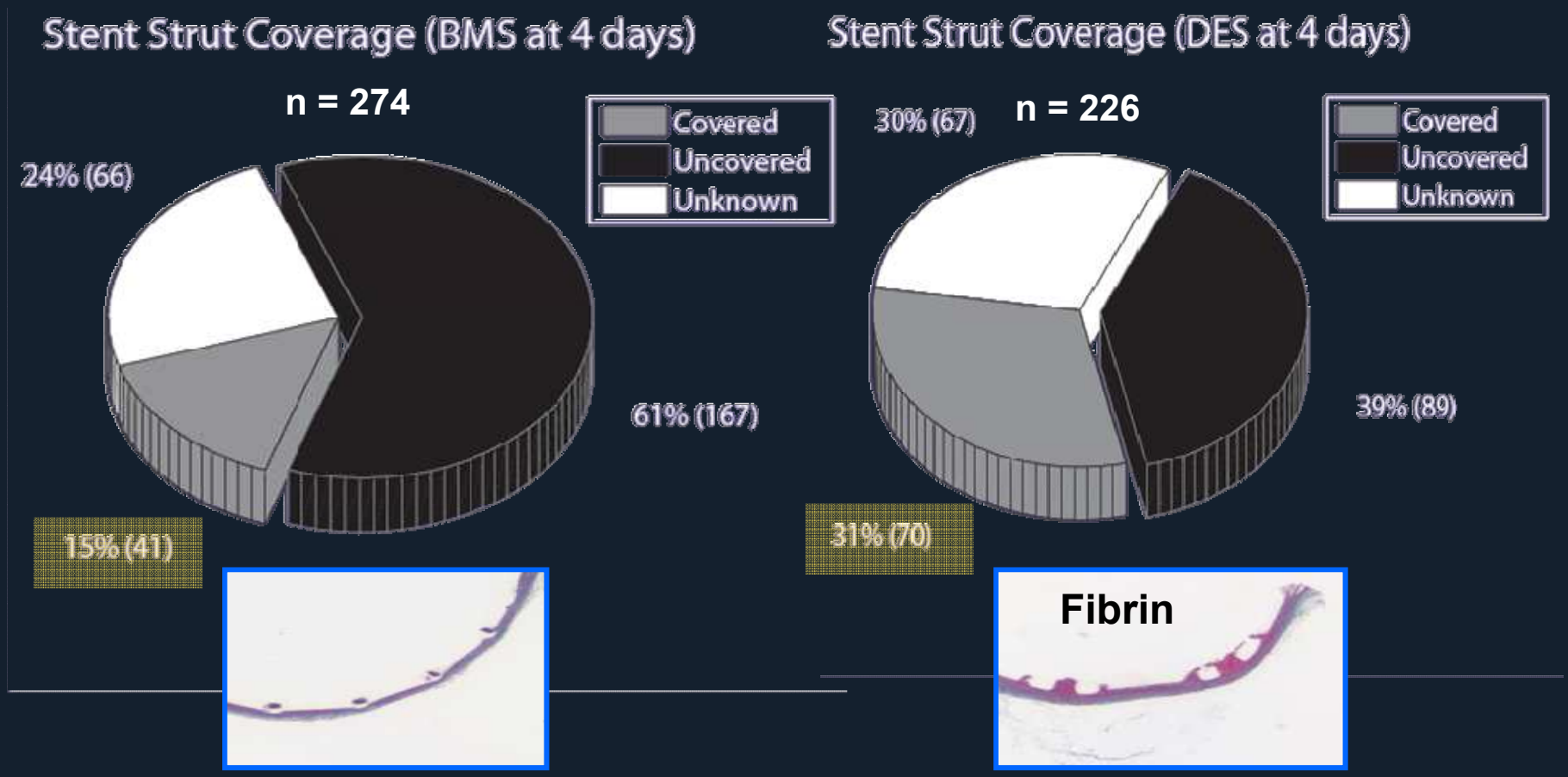

DES had twice as many covered struts compared to BMS

Patterns of Strut Coverage Overtime

OCT Analysis BMS vs. DES at 10 Days

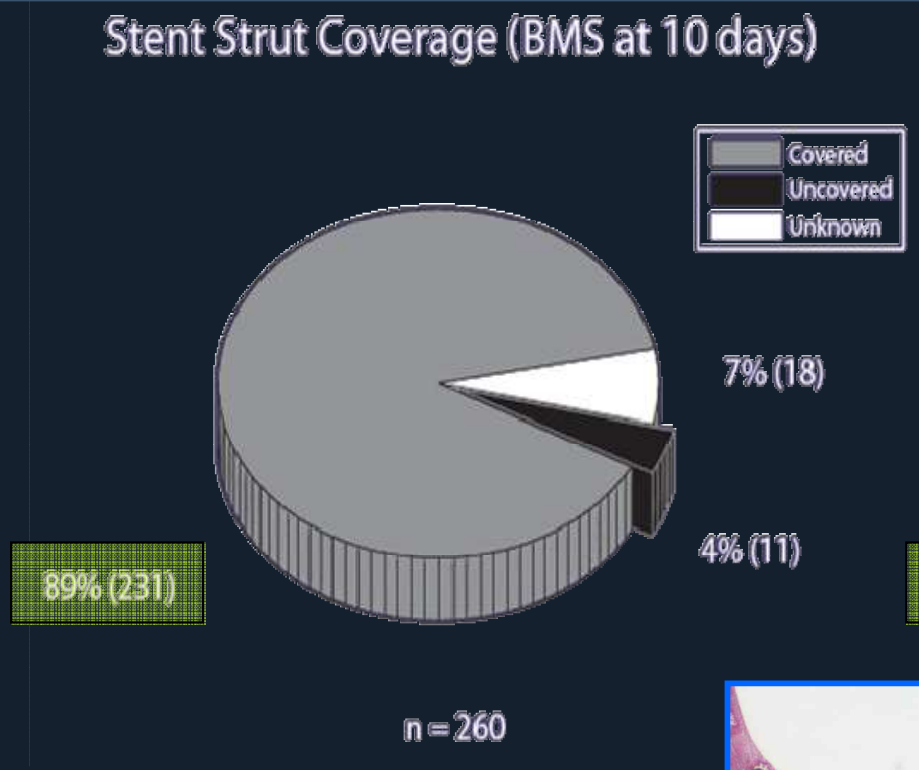



- BMS has more covered struts than DES
- Increased number of "difficult to analyze" struts in DES

Patterns of Strut Coverage Overtime

OCT Analysis BMS vs. DES at 28 Days

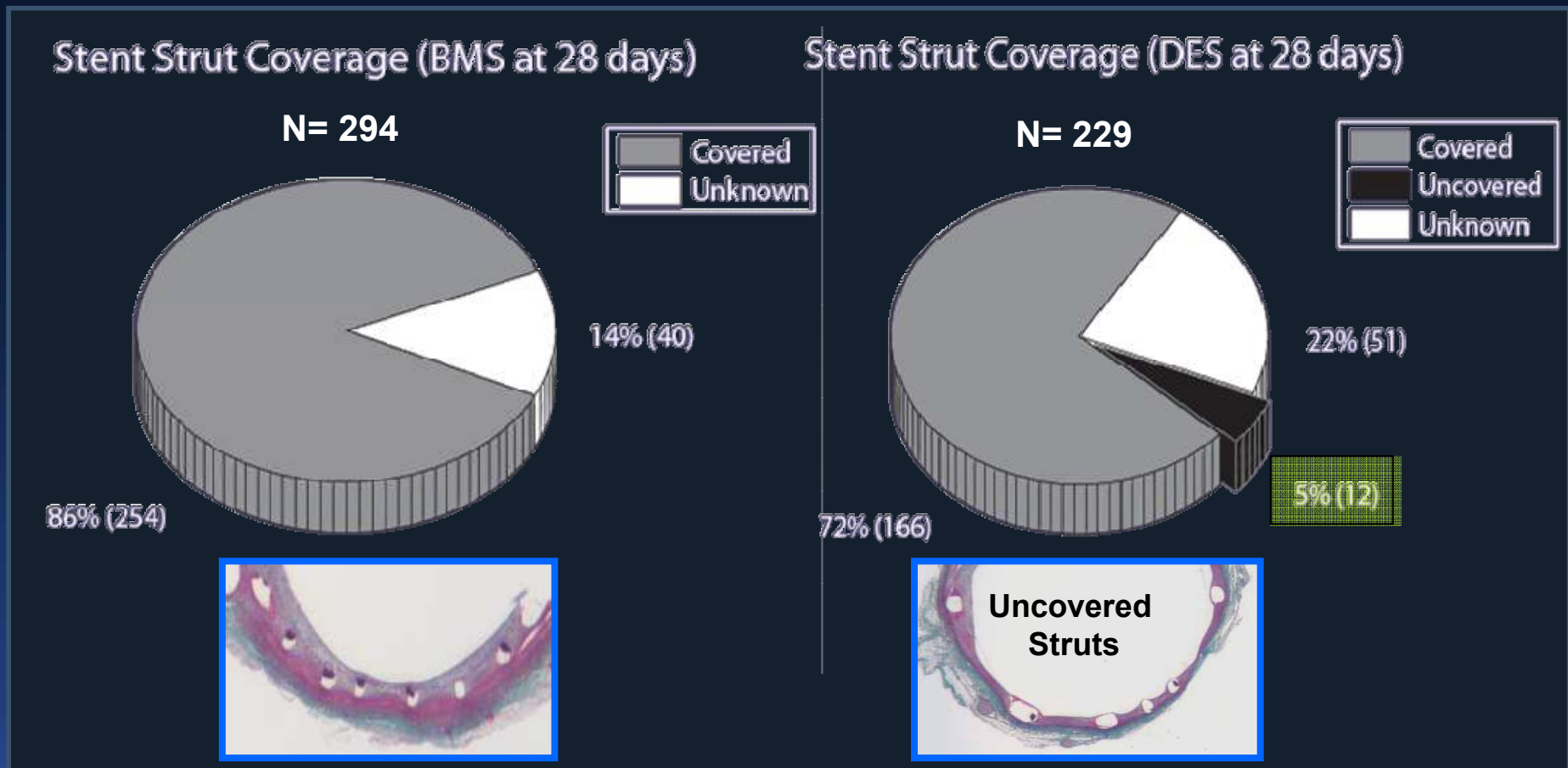

Uncovered struts by OCT persist only in the DES group

Strut Coverage Analysis

OCT versus Histology

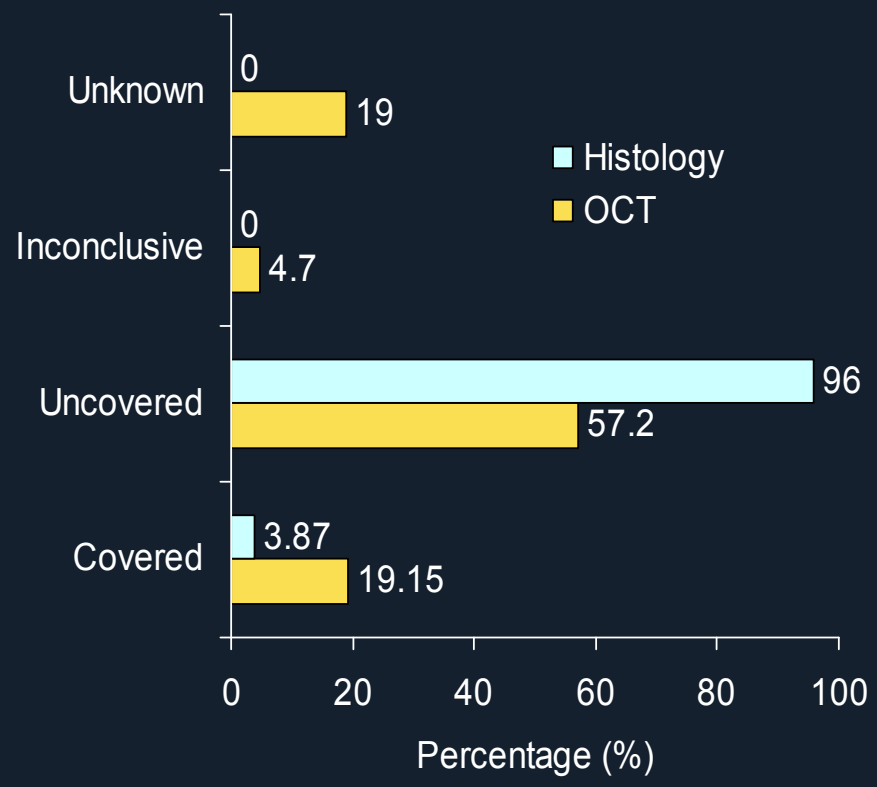

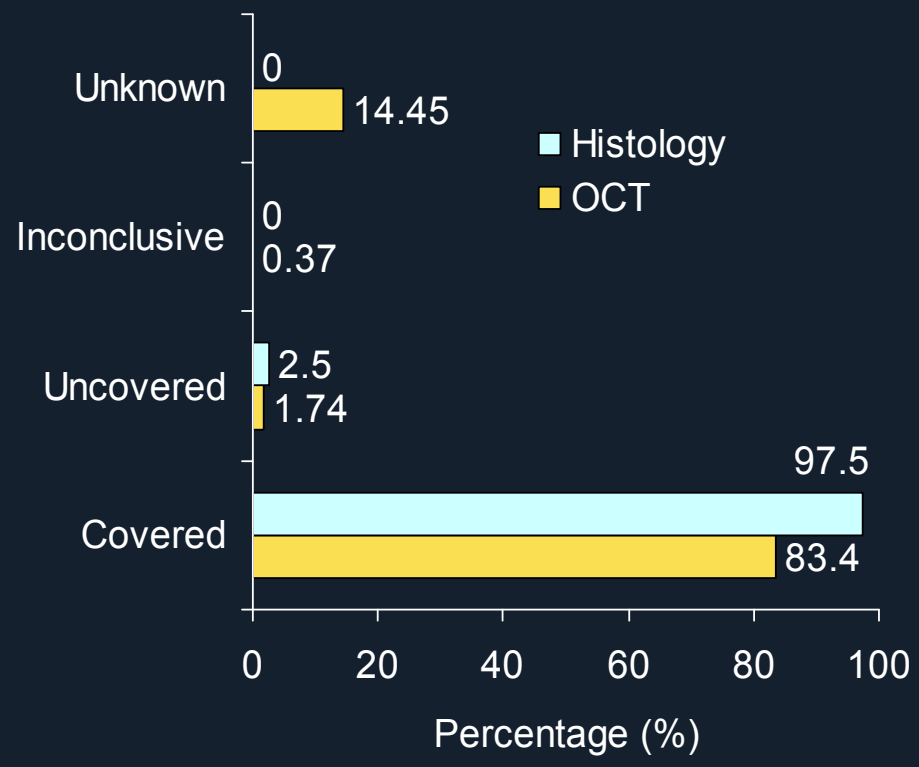

Strut Coverage Analysis

OCT versus Histology

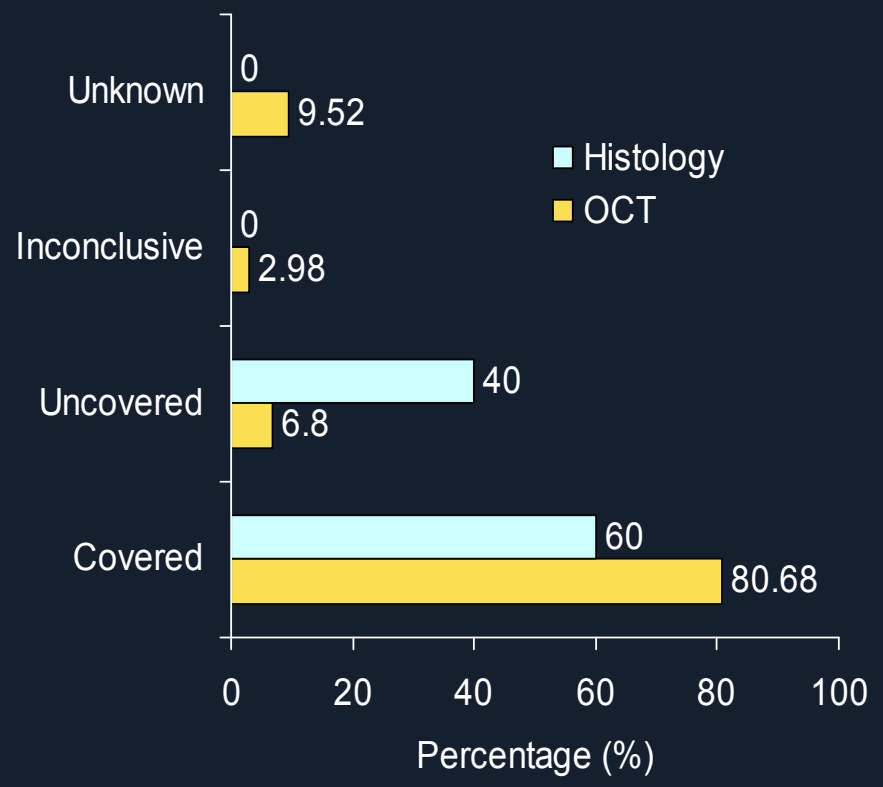

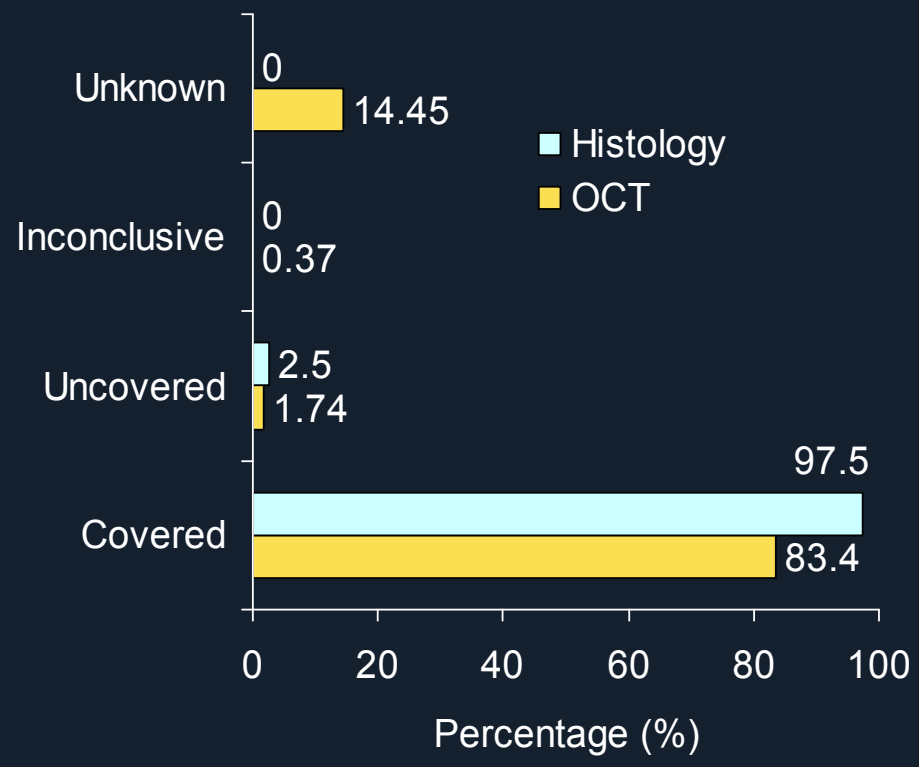

“The Protruding Strut”: Implications for Healing and Coverage

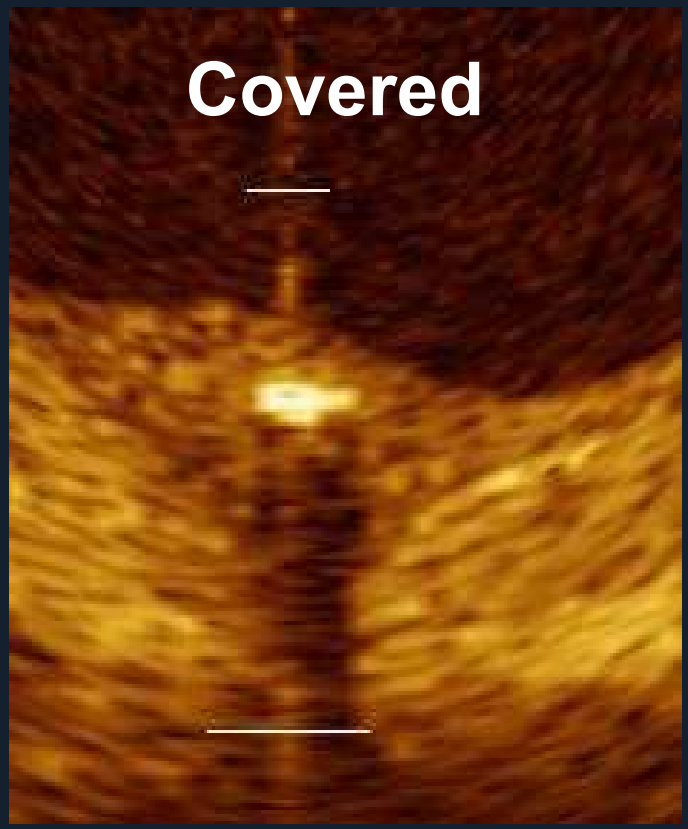

The Protruding Strut: Is It an OCT Surrogate of Vascular Healing?

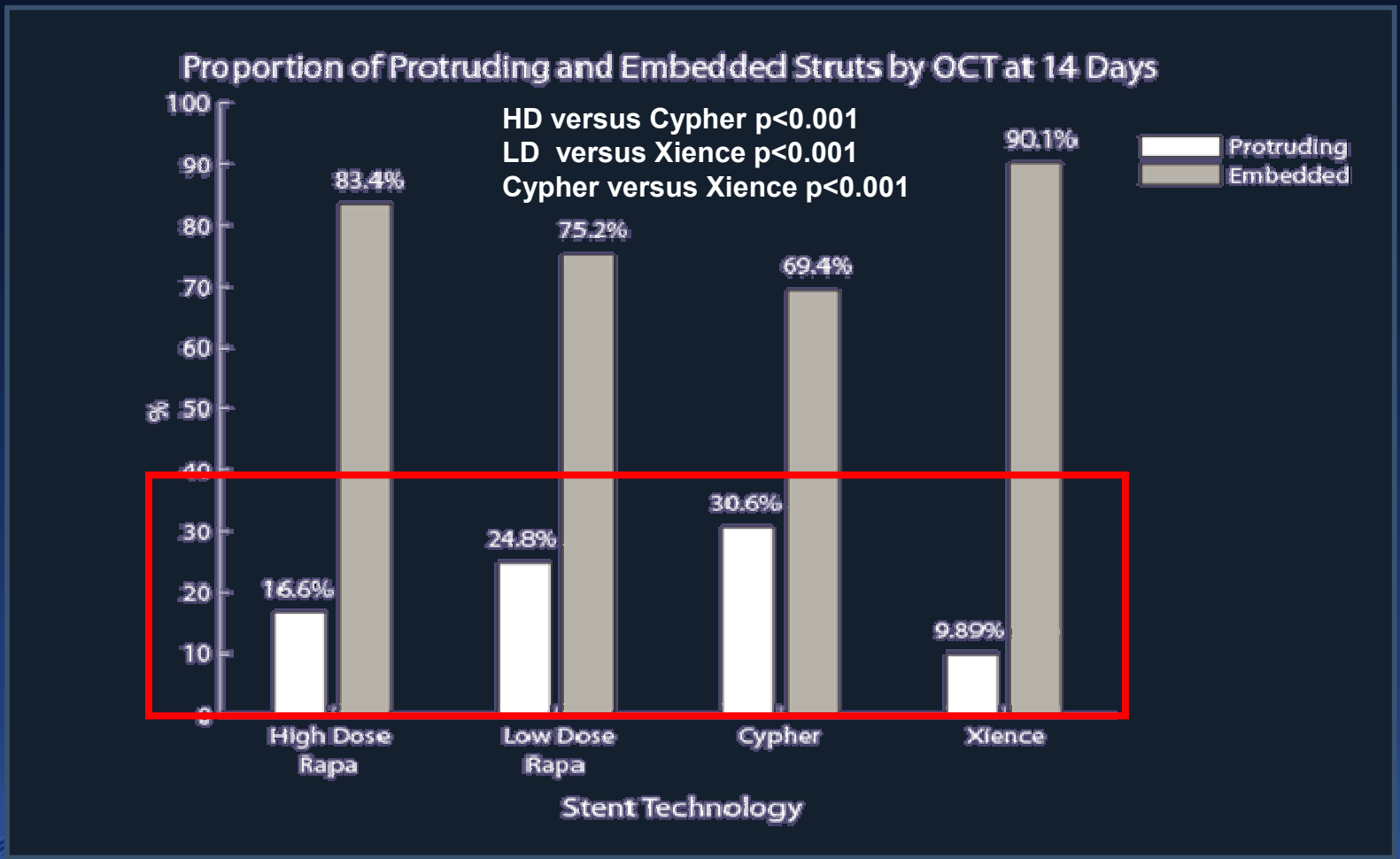

Columbia University Medical Center
NewYork-Presbyterian
The University Hospital of Columbia and Cornell
Cardiovascular Research Foundation

Aboodi M. J Am Cardiol. Sept. 2009; Vol 104 (6) TCT-137 55D.

Protruding Struts by OCT Display Lower Degrees of Neointimal Thickness at 14 Days

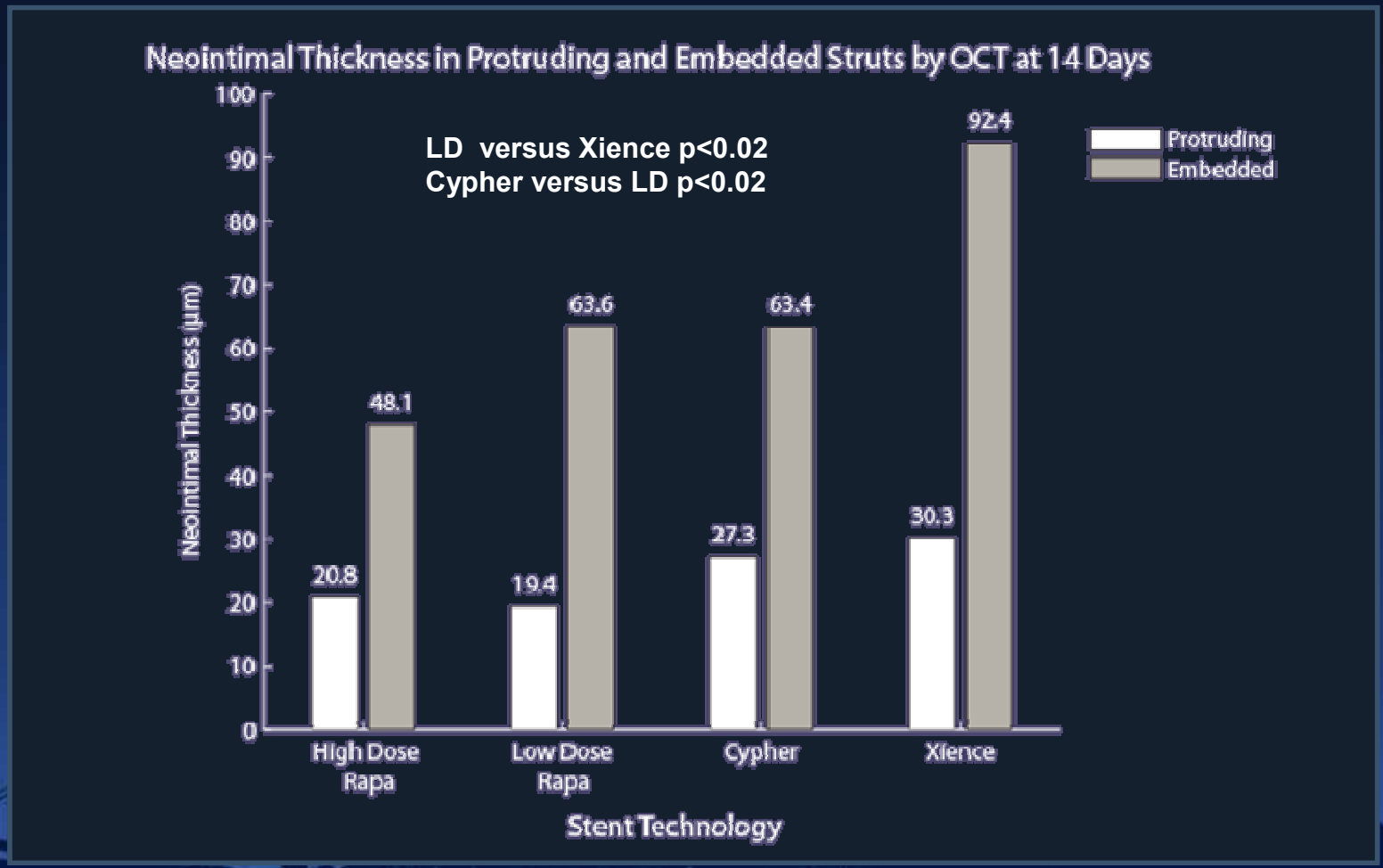

Columbia University Medical Center
NewYork-Presbyterian
The University Hospital of Columbia and Cornell
Cardiovascular Research Foundation

Aboodi M. J Am Cardiol. Sept. 2009; Vol 104 (6) TCT-137 55D.

Uncovered Struts Are Frequently Seen on Protruding Strut Evaluated by OCT at 14 Days

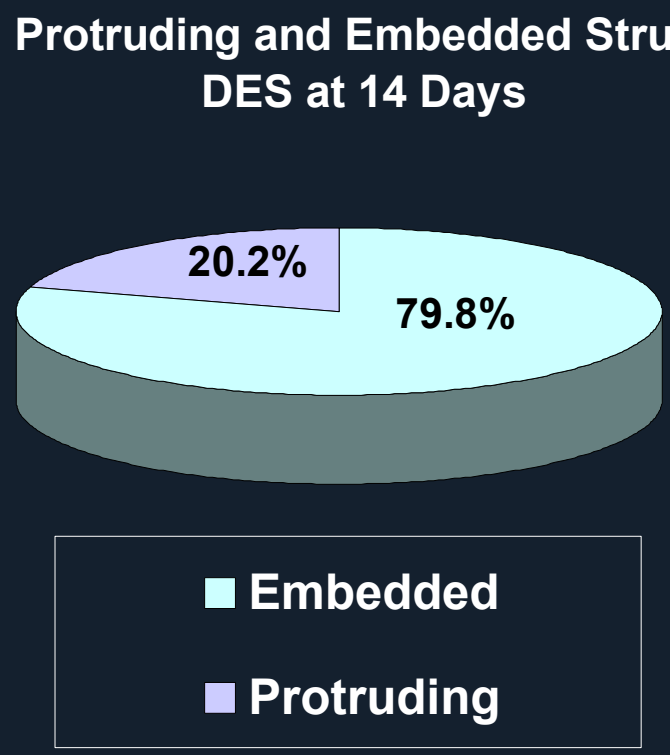

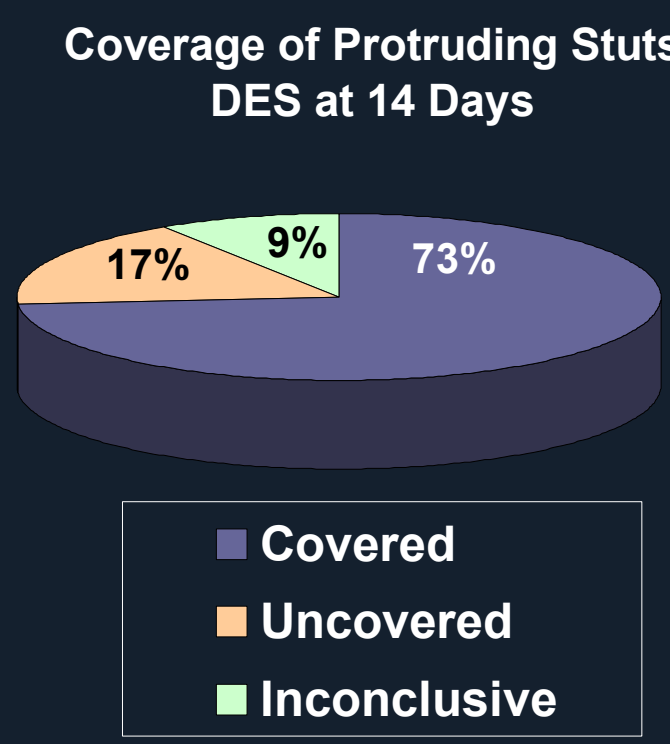

1427 stent struts were analyzed

Columbia University Medical Center
NewYork-Presbyterian
The University Hospital of Columbia and Cornell
Cardiovascular Research Foundation

Aboodi M. J Am Cardiol. Sept. 2009; Vol 104 (6) TCT-137 55D.

Different Neointimal Patterns Seen in OCT Following DES Implantation

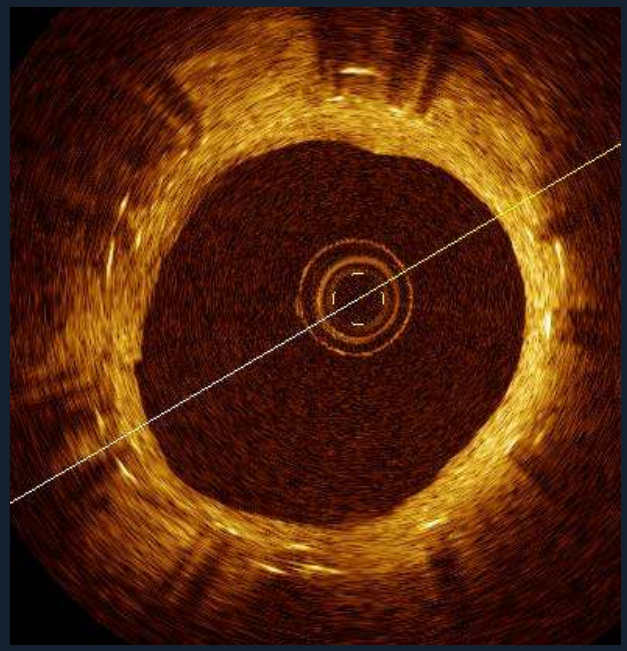

Cypher - 6 Months

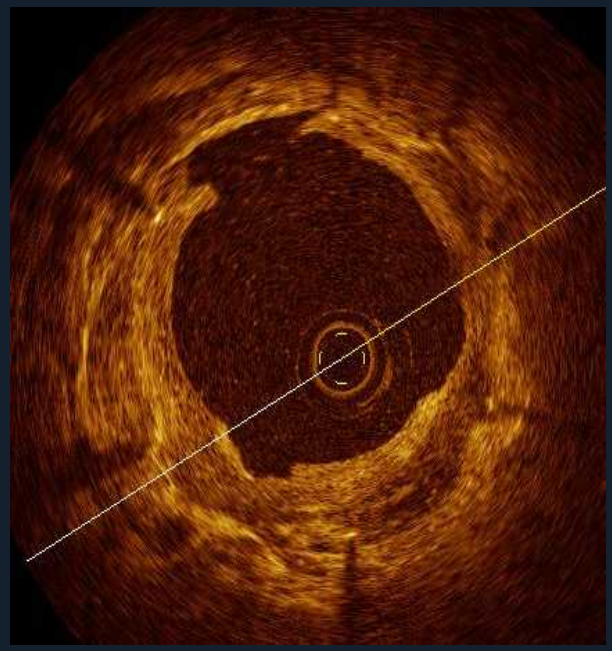

Cypher - 6 Months

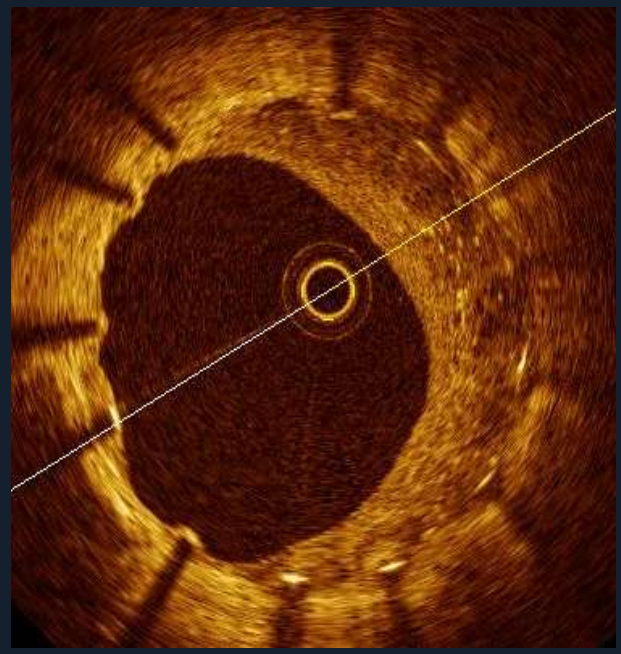

Taxus - 13 Months

OCT Histological Correlates
Drug Eluting Stents at 28 Days

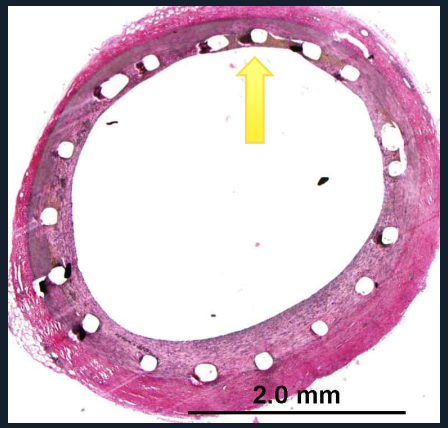

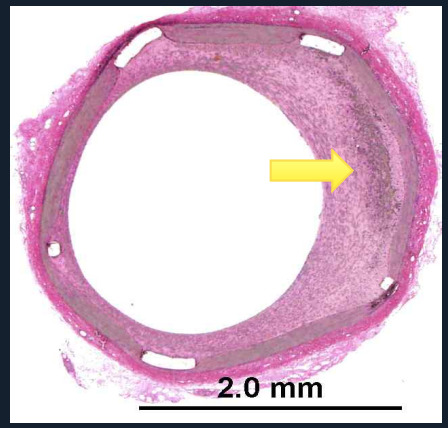

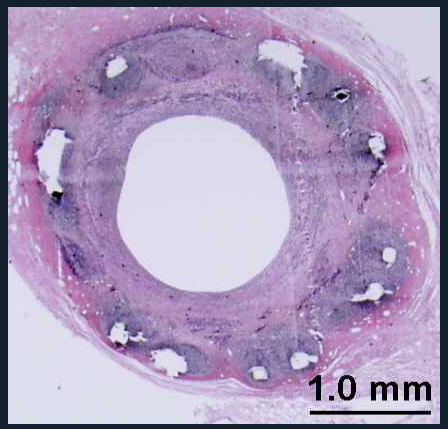

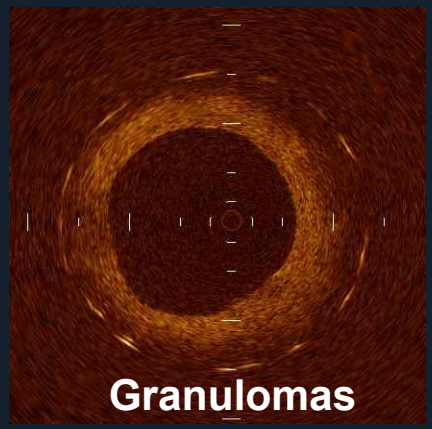

Therefore, several OCT imaging patterns may be the result of the deposition of different tissue types carrying different biological consequences.

Assessment of Strut Coverage: Volumetric Stent Analysis



Strut Coverage Map

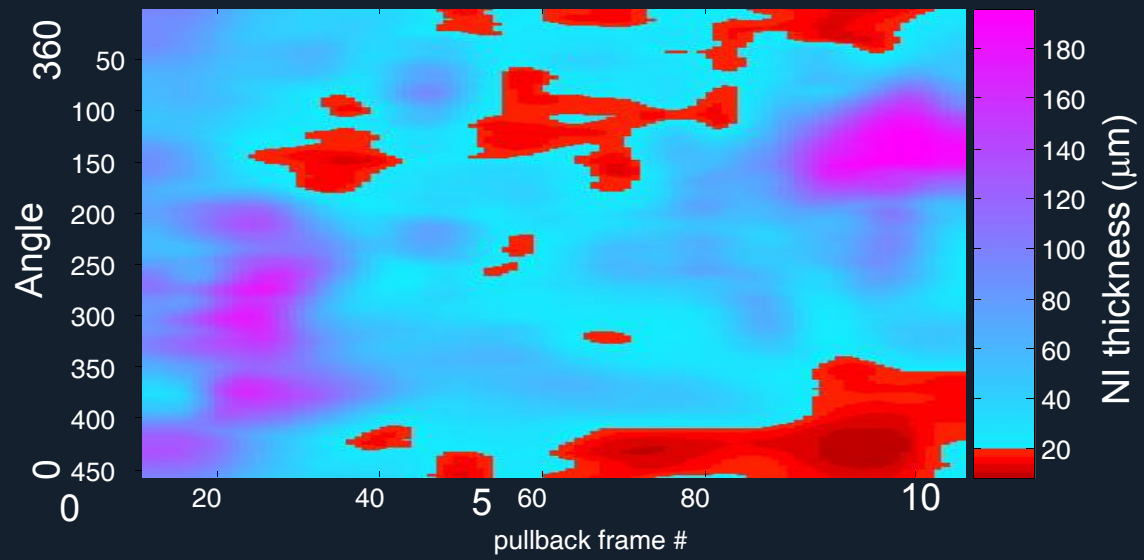

3-D reconstruction – In-vivo Fresh Stent Implantation, Helios Heart Center

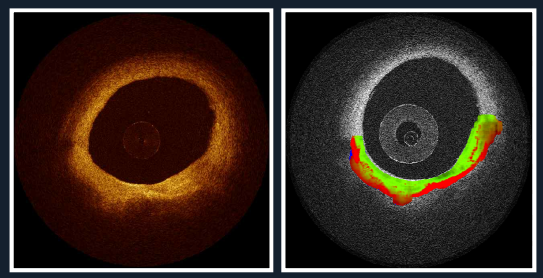

Tissue Characterization

OCT Imaging and Vascular Healing Assessment Following DES Implantation

- Today, due to significant improvements in OCT technology, the *in vivo* assessment of vascular healing following stent implantation is possible.
- OCT can accurately and reproducibly measure subtle changes in neointimal area, thickness, and percent area of stenosis.
- The assessment of strut coverage is feasible and reproducible. However, its clinical significance is still unknown and further research is required to elucidate the importance of this finding.
- As these biological changes may be technology-specific, tissue characterization studies of different DES technologies are essential.
- Due to its technical limitations in the far field, OCT combination technologies may be required.
- In the future, it is possible that lessons learned from prospective clinical trials using this technology will provide the basis of DES safety profile enhancement.