

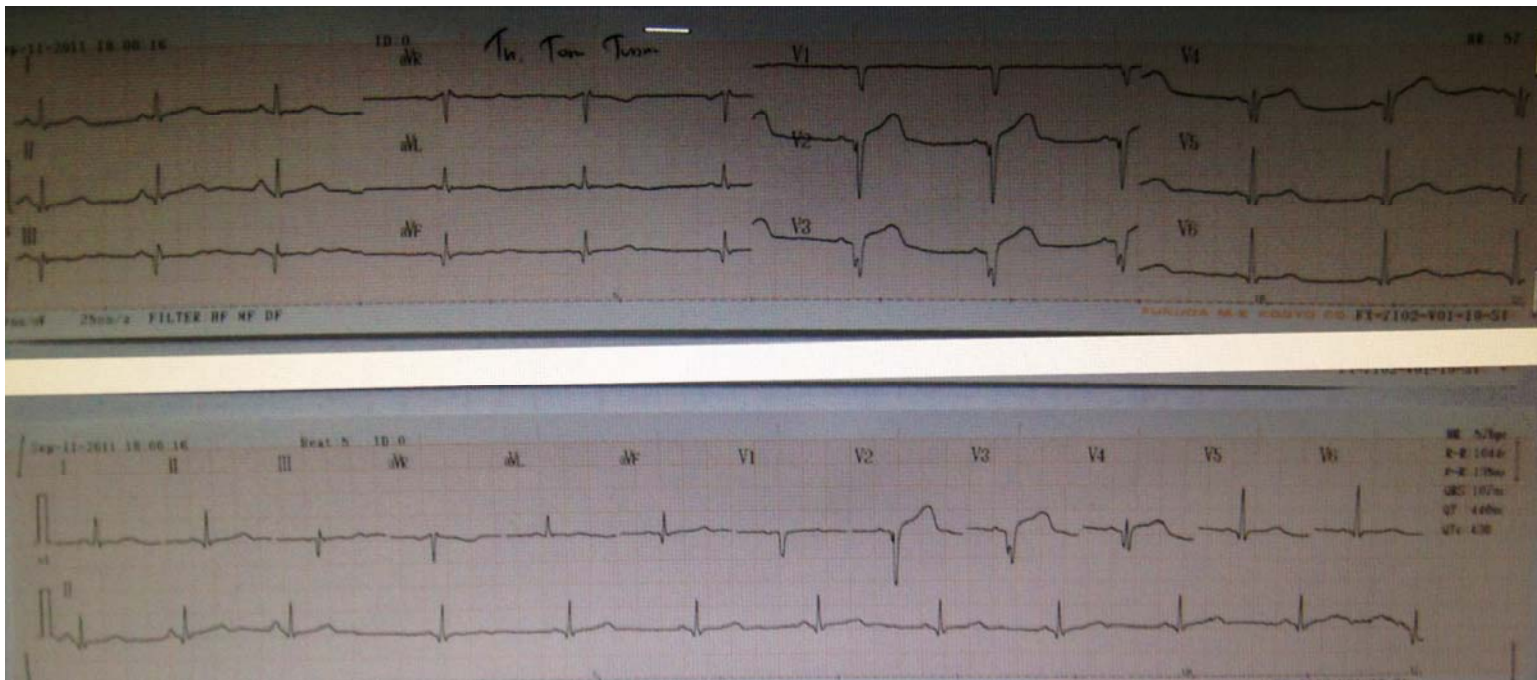
Cut – off Stent Balloon during Primary PCI

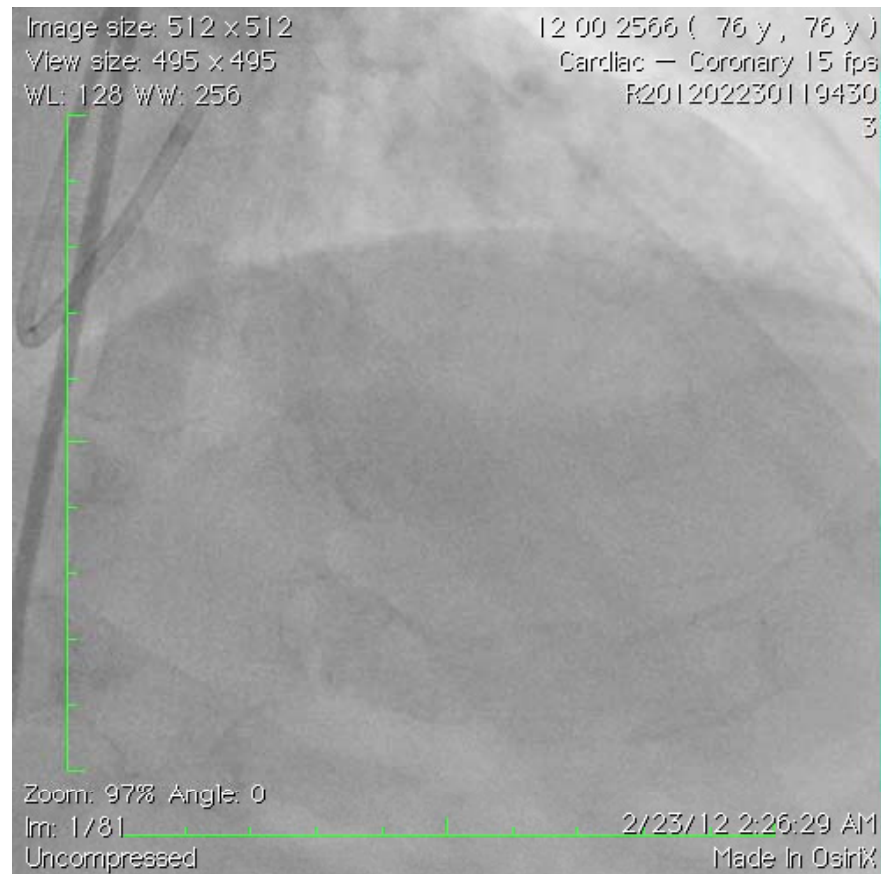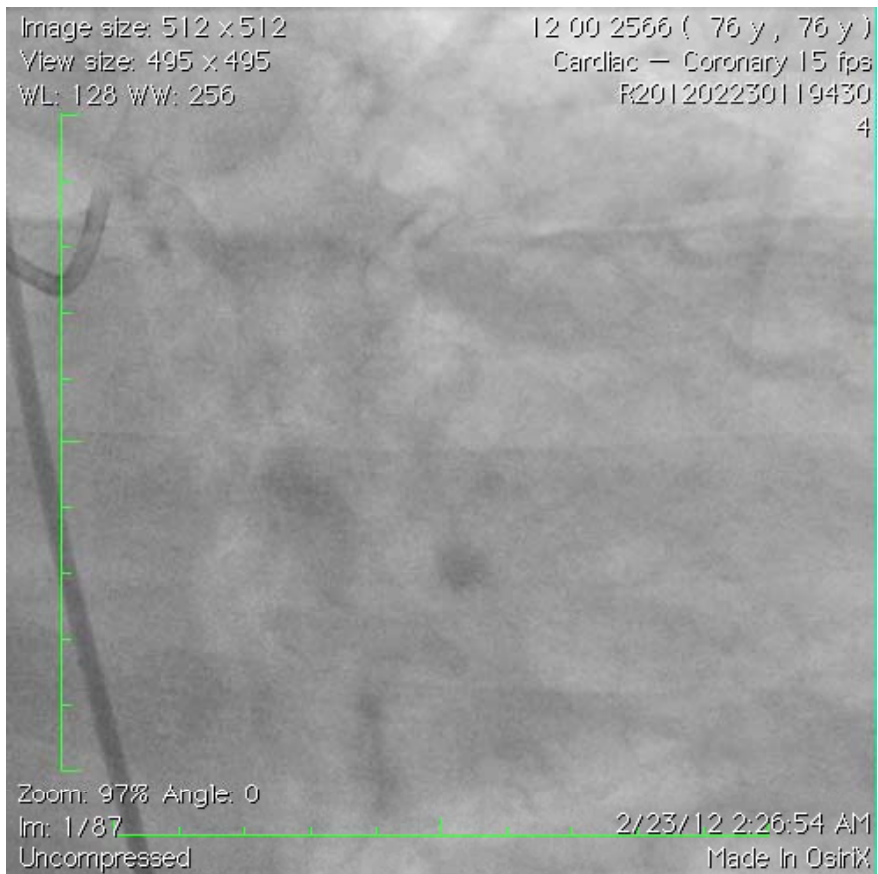Januar Wibawa Martha

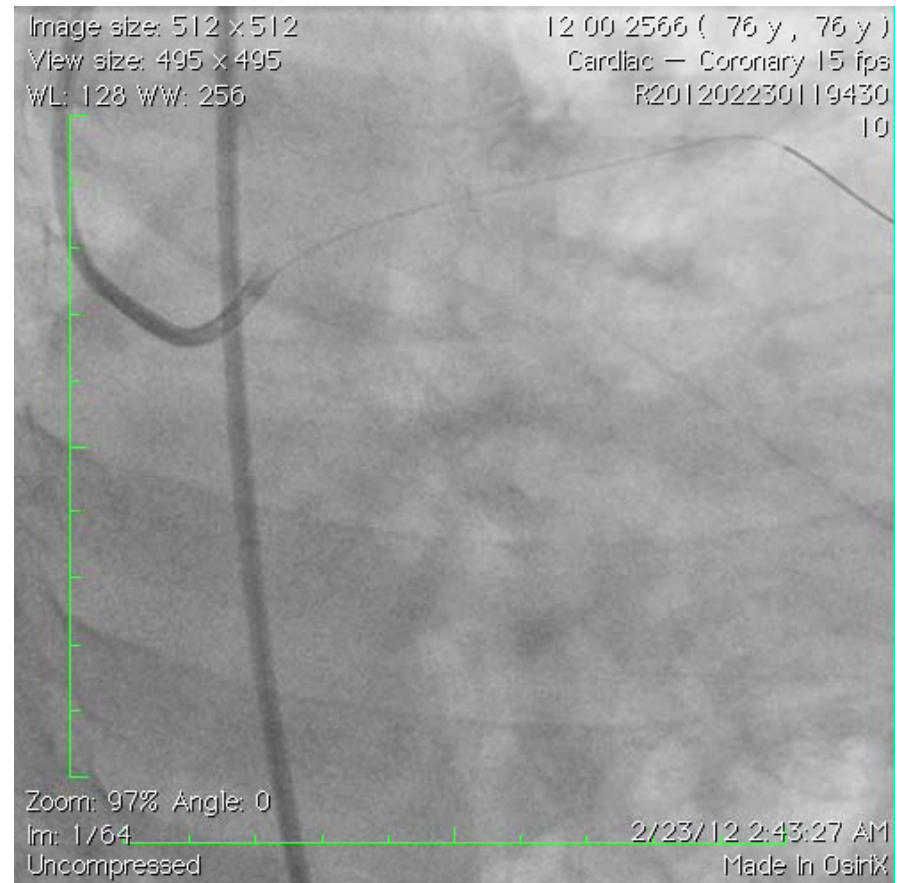
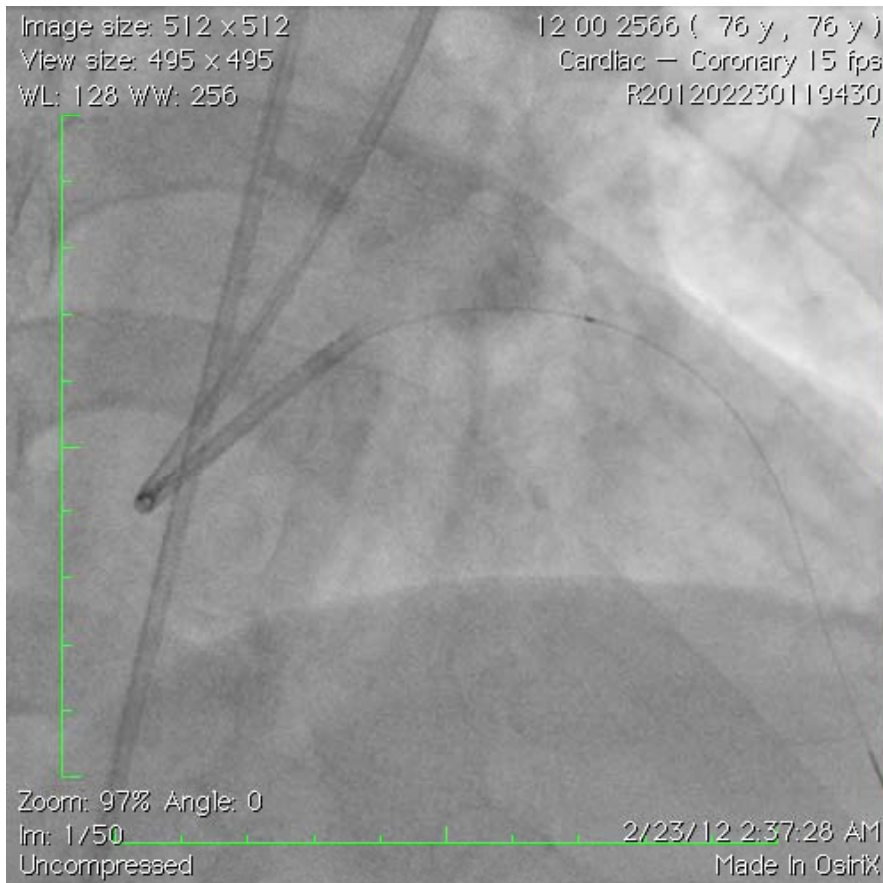
Department of Cardiology & Vascular Medicine
Padjadjaran University
Bandung, Indonesia

The Case

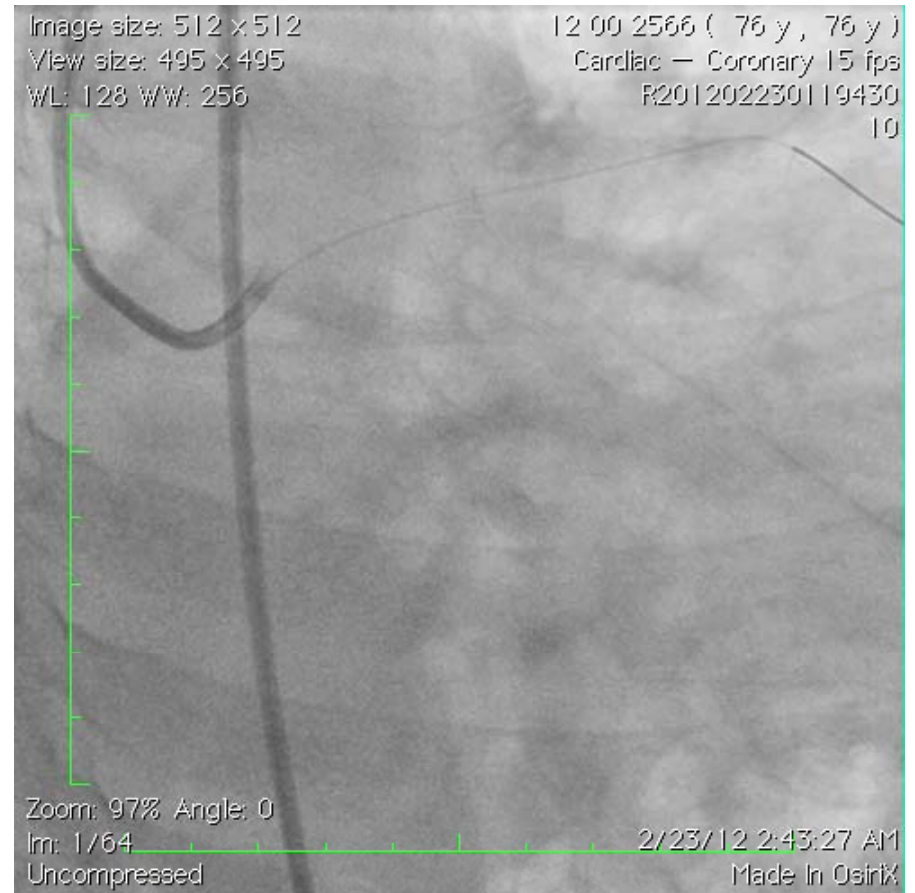
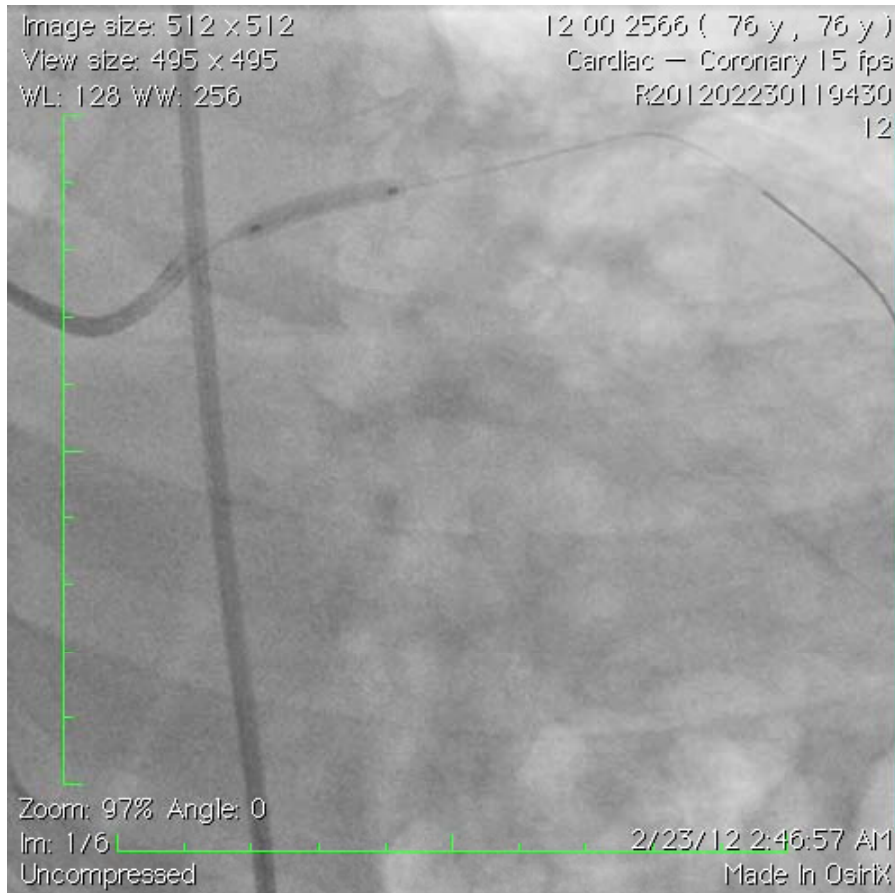- 54 year old male with acute anterior wall MCI of 5 hours duration. Risk factors: dyslipidemia, smoking



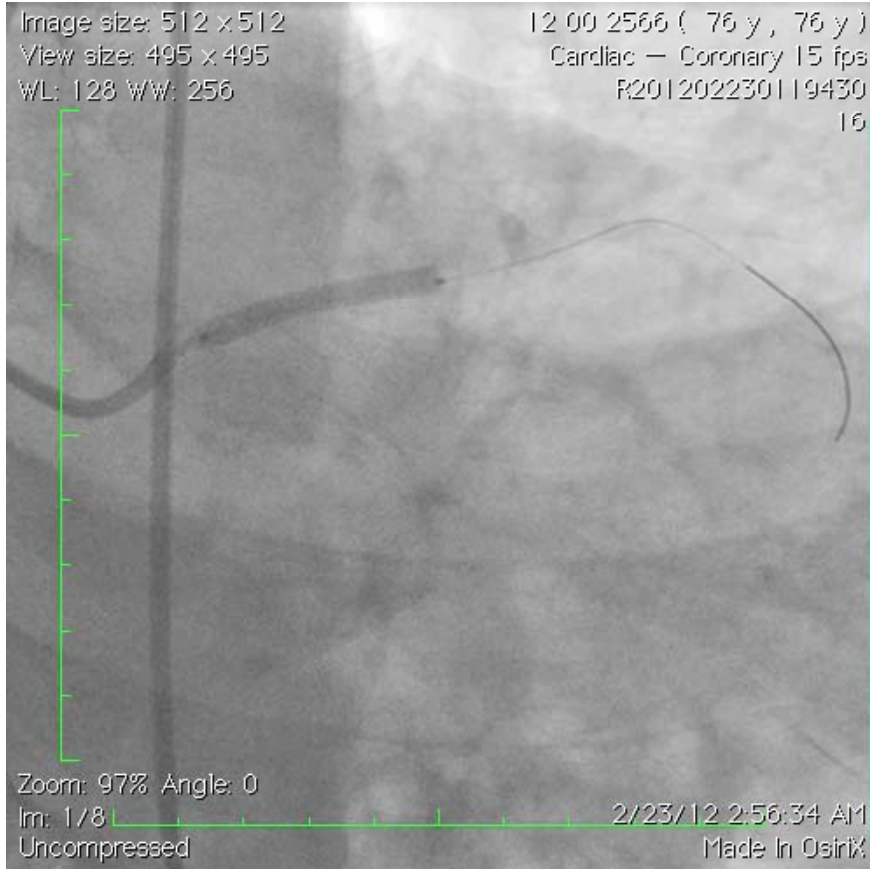




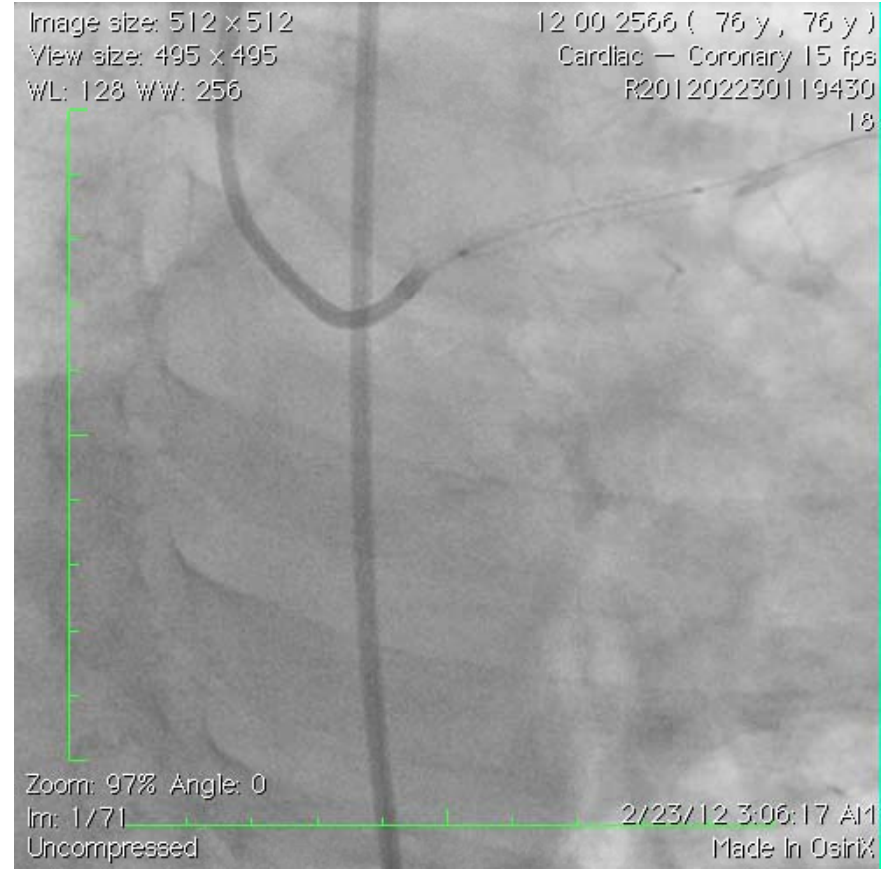
Thrombosuction.....



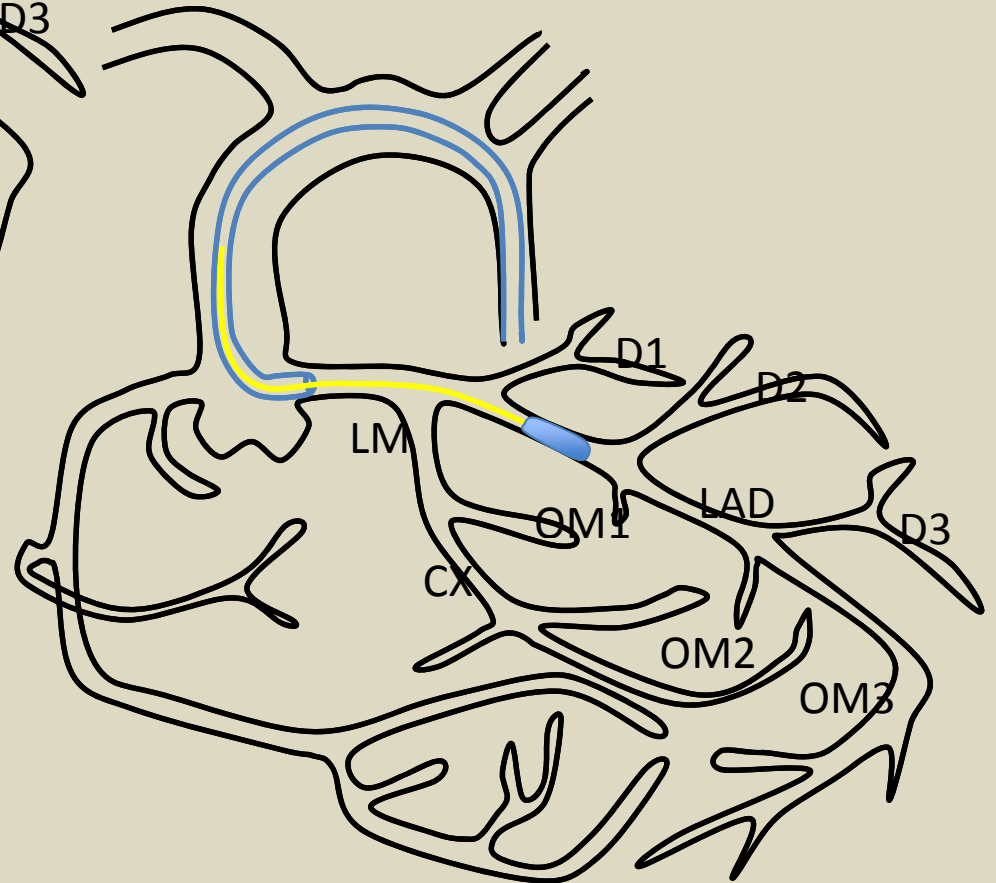
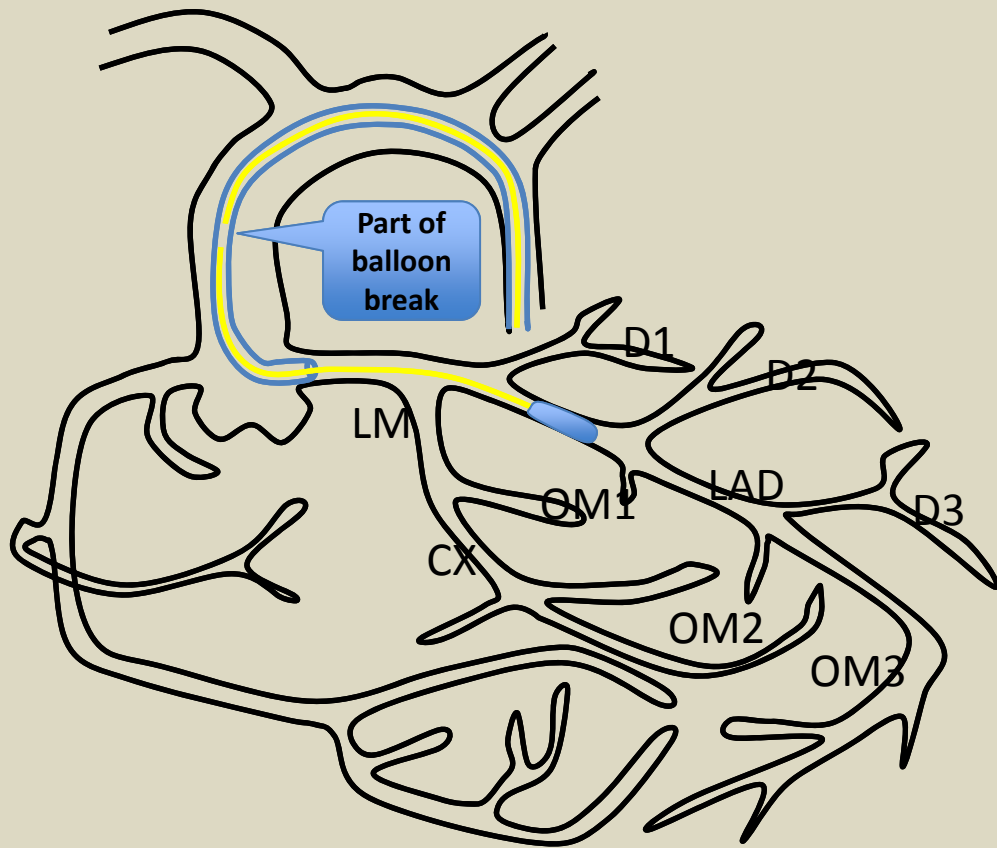
Predilation 2,0-15 balloon.....

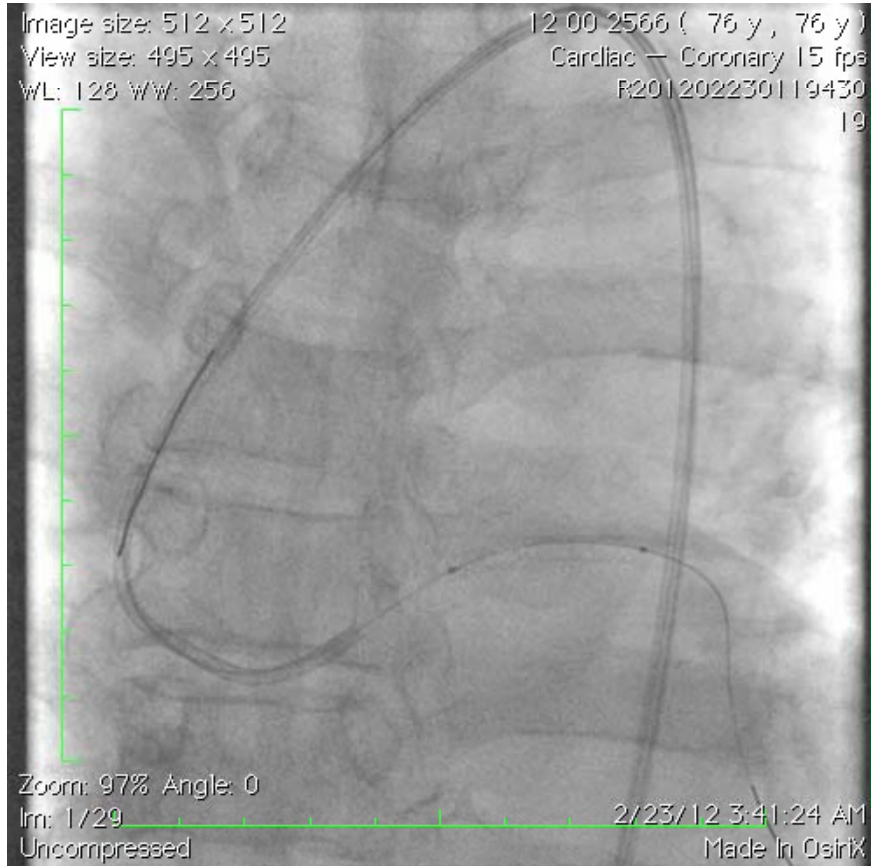

Stenting 3,0-23 BMS 14 atm

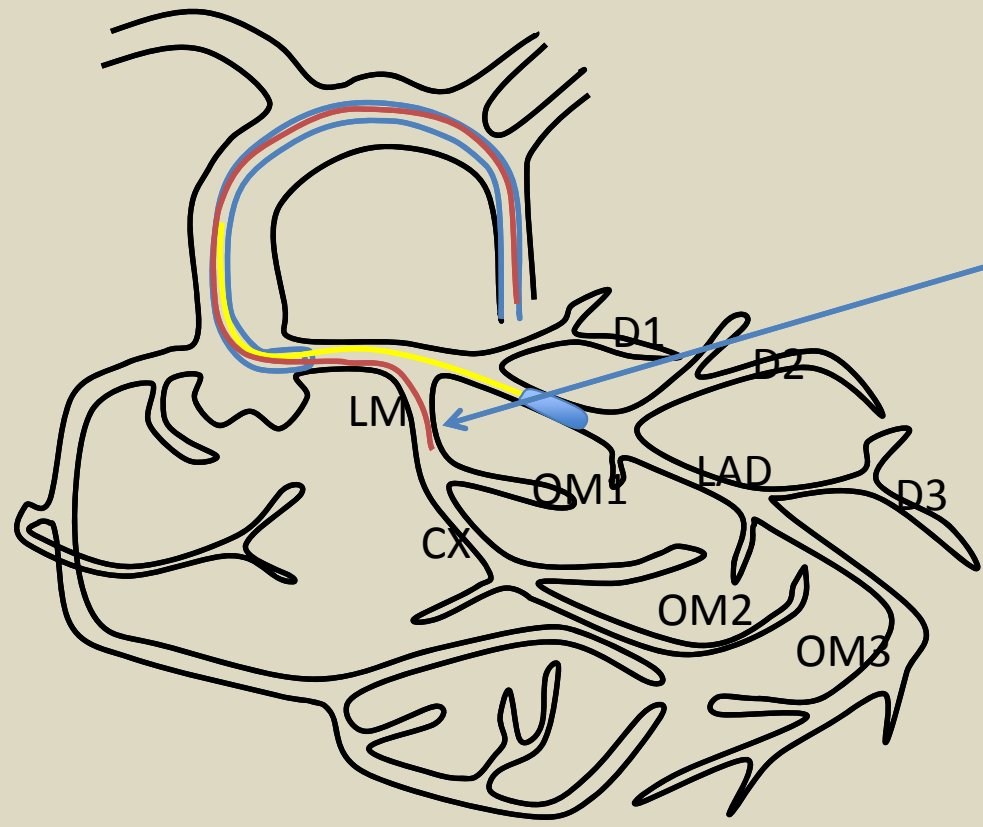


What is wrong?

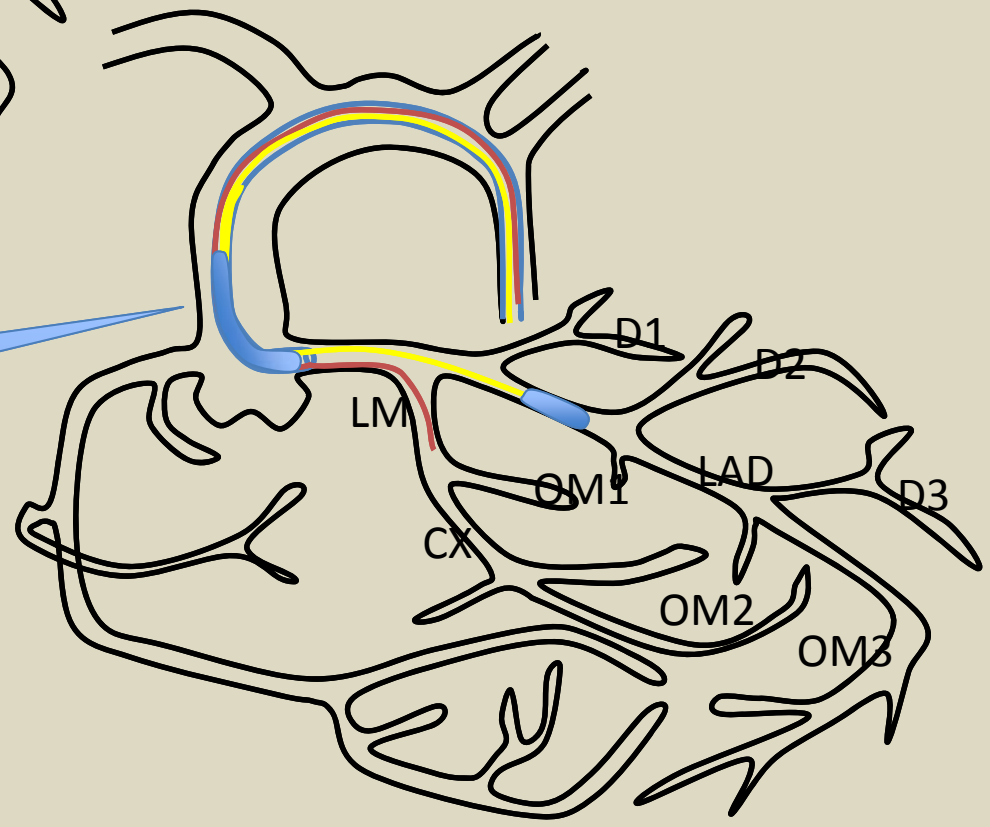




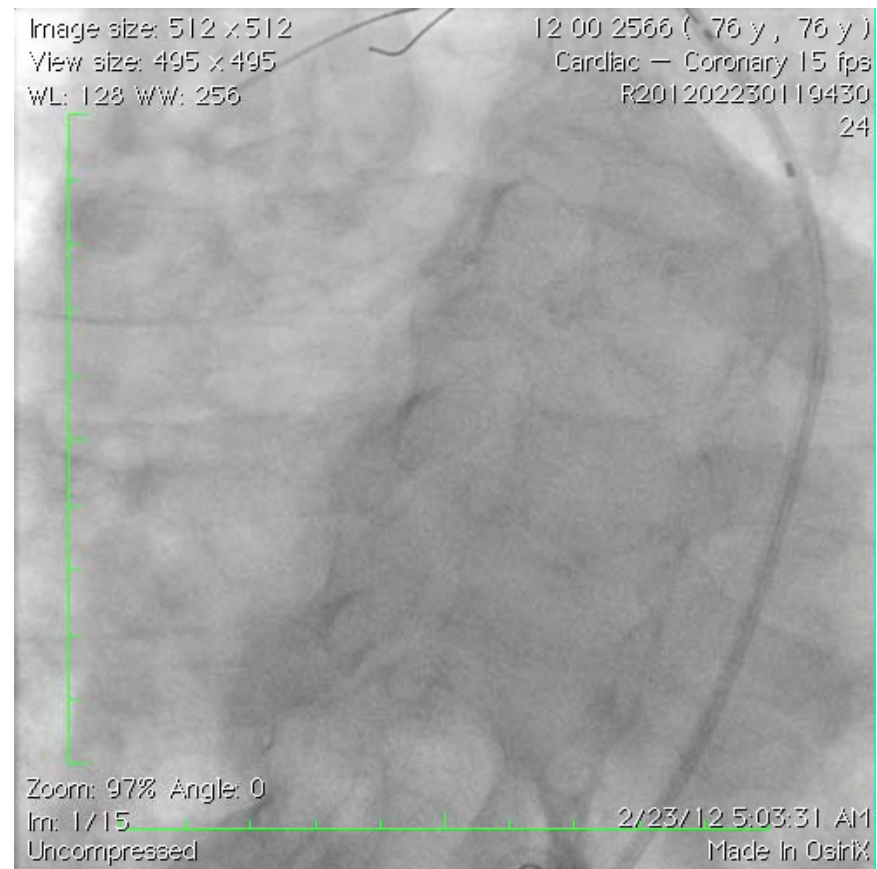
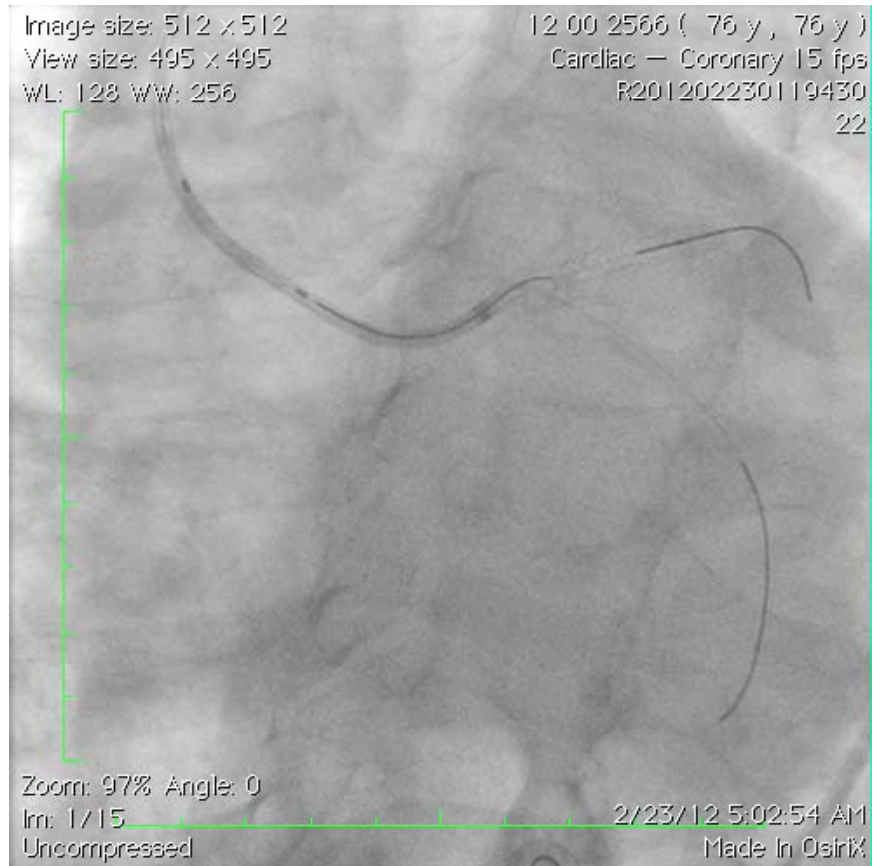After 1,5 hours trying to snare,
both the balloon and the part inside
the guide, we started to give up
and call the surgeon
(at 3 in the morning)


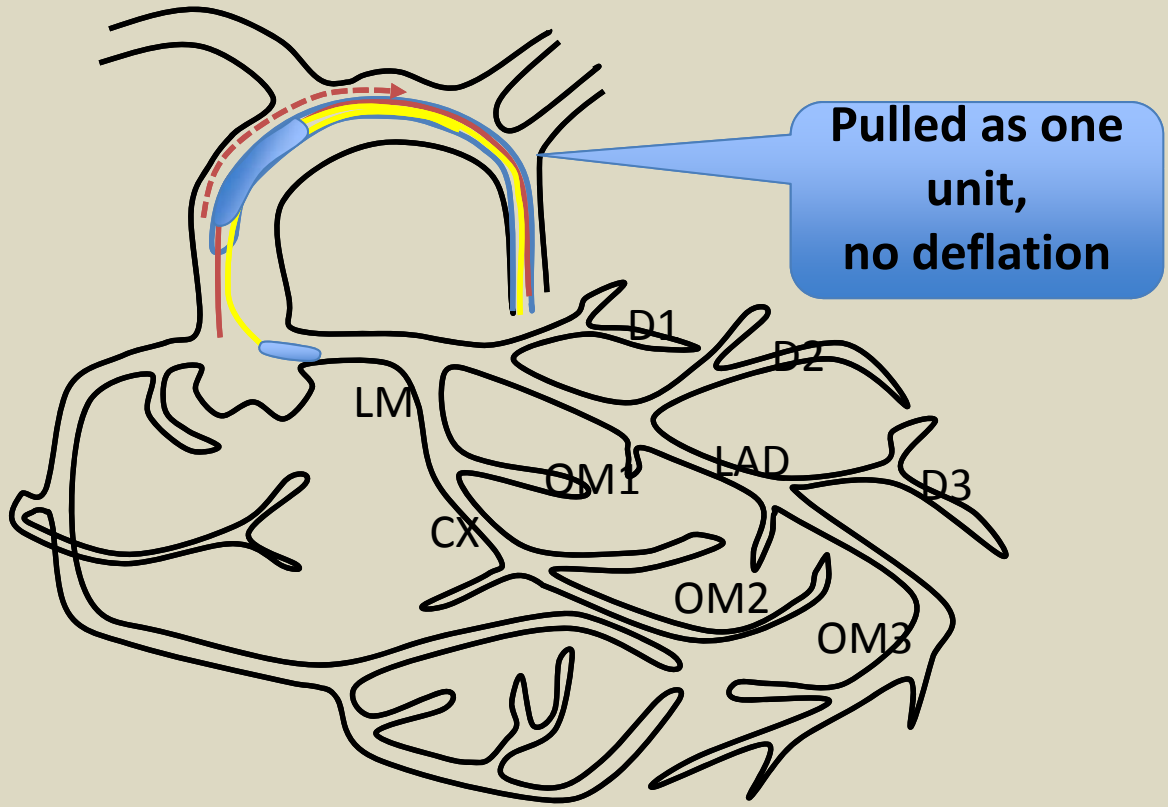

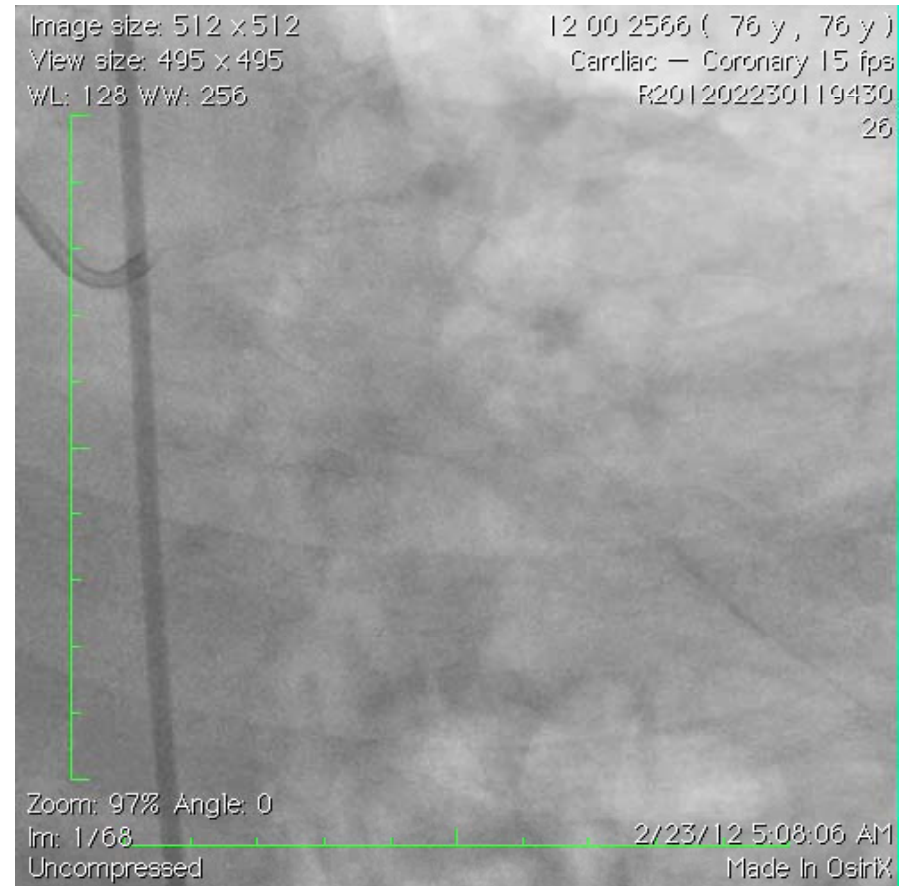
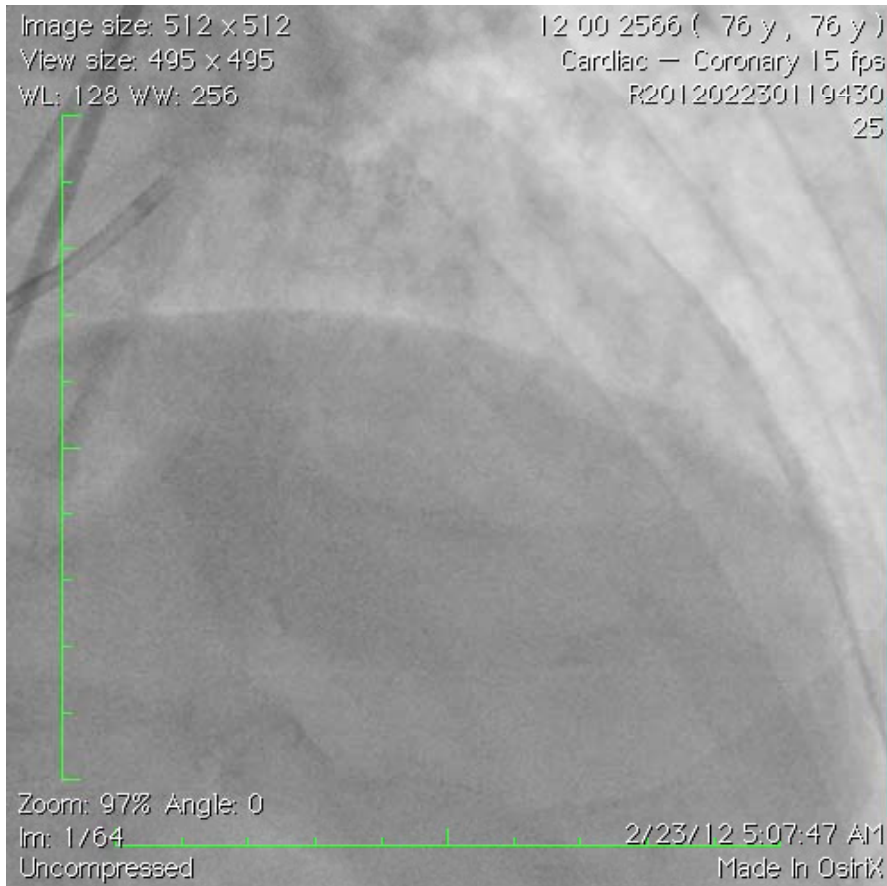
Insert second wire



**Peripheral balloon
3,0-40 20 atm**







Final Result.....

Take Home Messages

- Ensure balloon fully deflated before being pulled out (some balloons are deflated slowly)
- If a part of balloon still in the guide, DO NOT LOSE THE GUIDE
- Be creative....
- It is YOUR PATIENT, YOUR PROBLEM, so you do the best to finish the job