

Real-world Application of Bioresorbable Vascular Scaffold

Dr. Vincent O.H. Kwok

MBBS FRCP (Lond, Edin, Glas) FACC FSCAI FAPSIC

Director, Cardiology Center

Director, Cardiac Cath & Intervention Center

Honorary Consultant

Hong Kong Sanatorium & Hospital

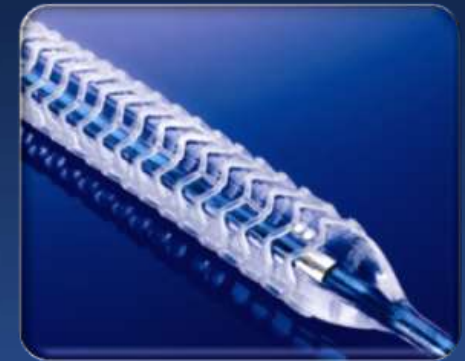Honorary Clinical Associate Professor,

Li Ka Shing Faculty of Medicine

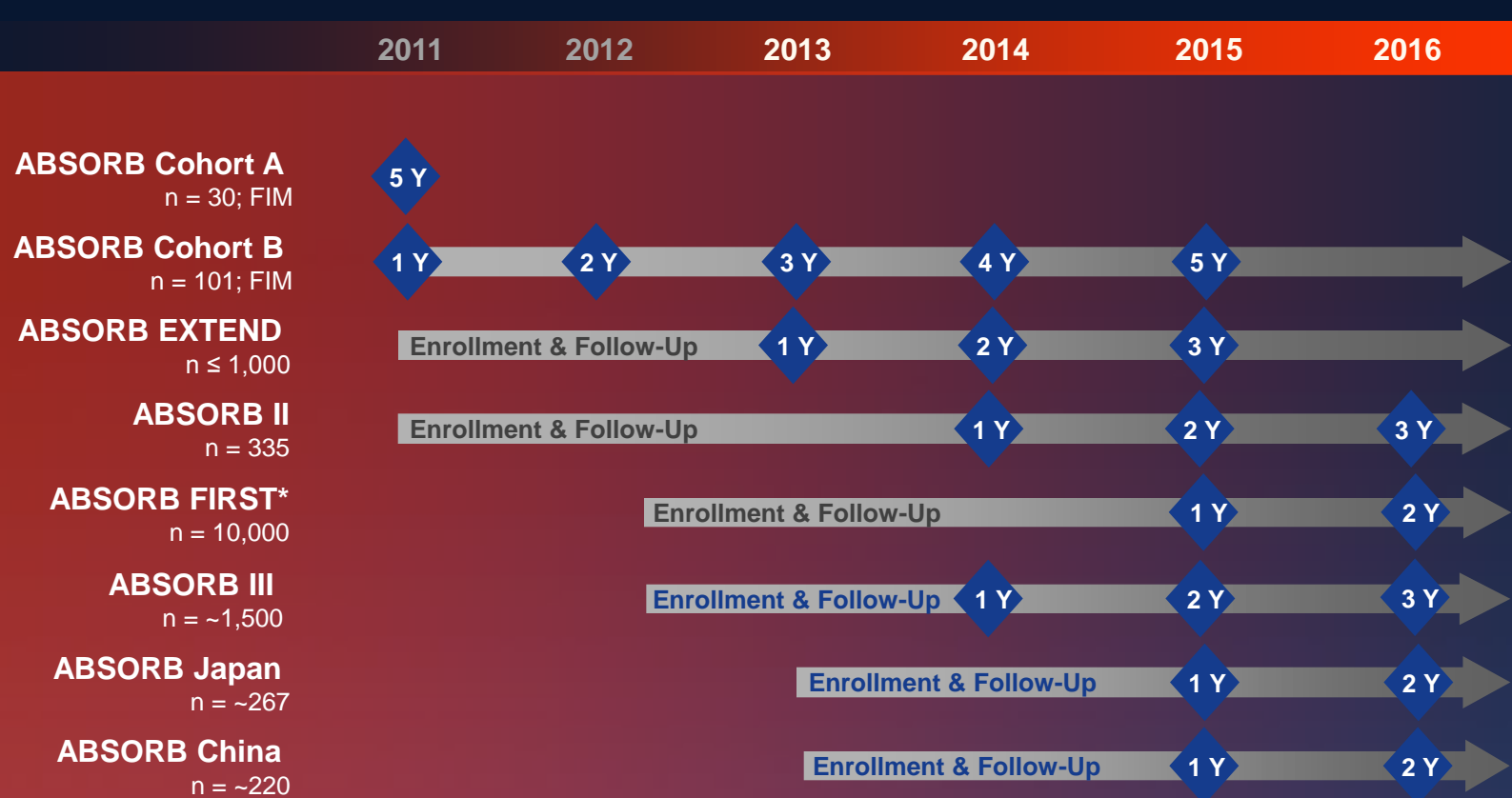
The University of Hong Kong

Honorary Professor,

Beijing Hospital, Ministry of Health, PR China



Investing in a Comprehensive ABSORB Clinical Trial Program



Total Patients Studied n~599 n~930 n~5,674 n~13,453 n~13,453 n~13,453

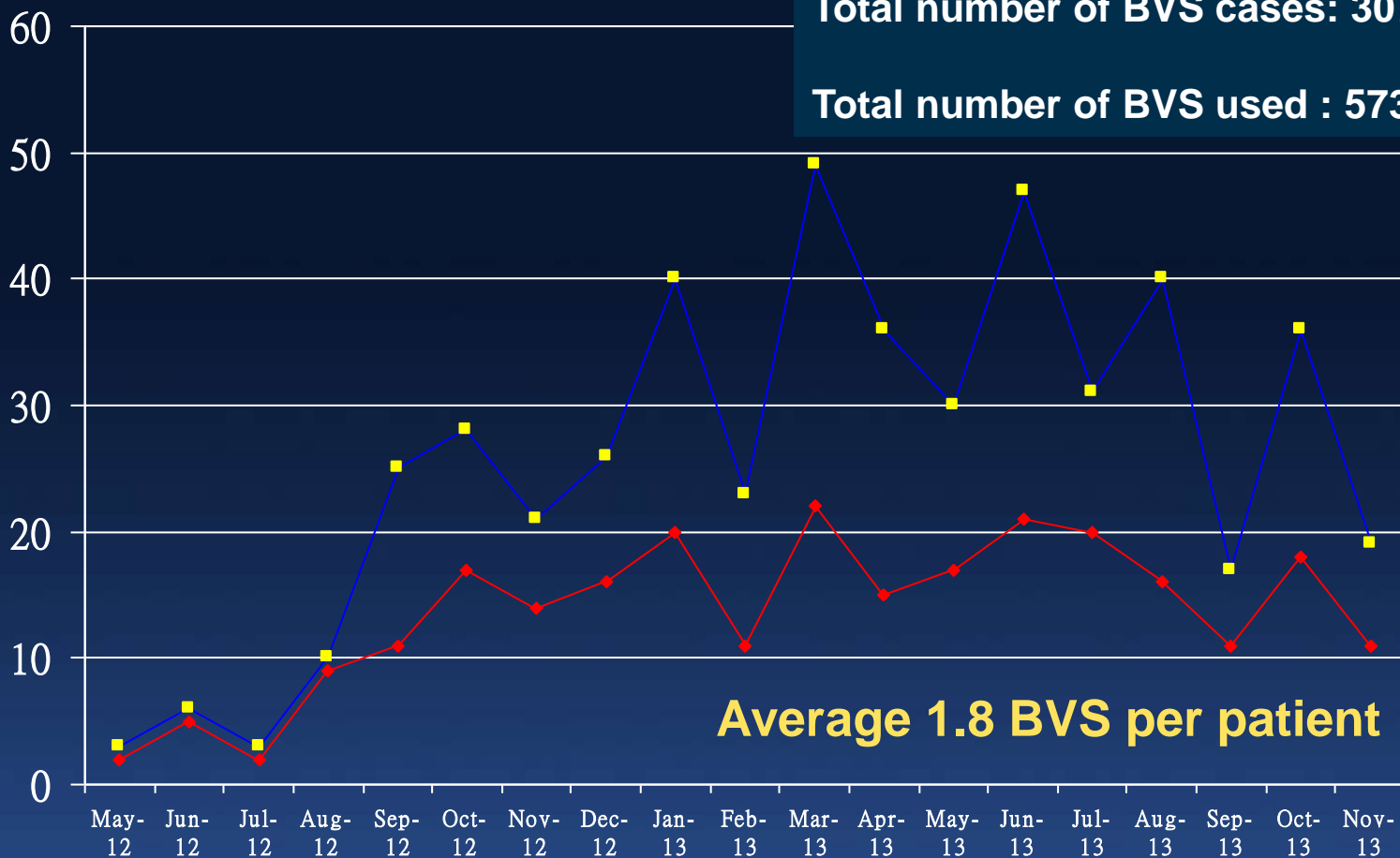
Note: Sample sizes reflect Absorb patients only.

* n= 10,000 f/u at 6 months. 1,000 patients f/u at 1 -3 years, 1,000 patients at 2-4 years

The BVS cases number and number of BVS used from 5/2012-02/2014 in HKSH

Total number of BVS cases: 307

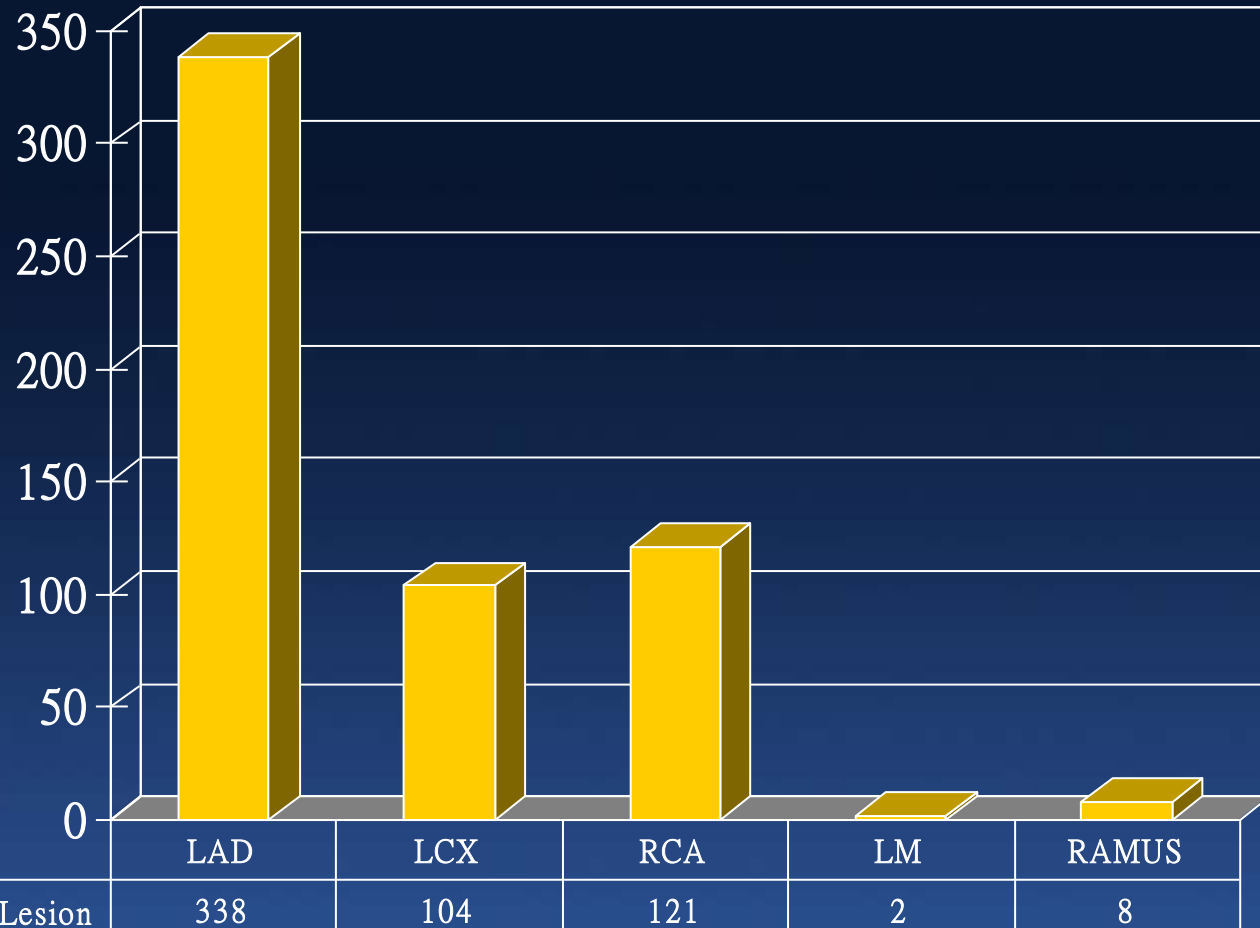
Total number of BVS used : 573



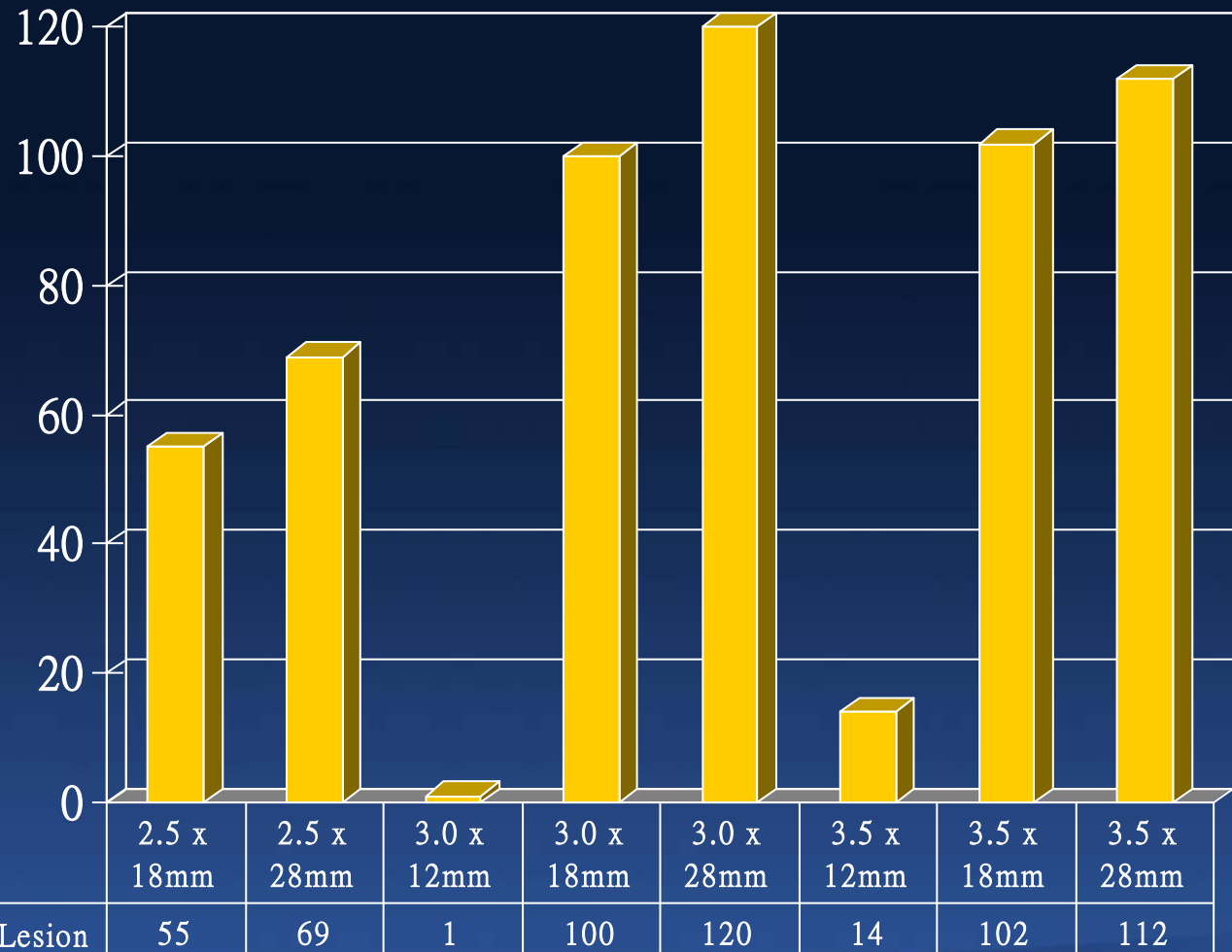
May-12 Jun-12 Jul-12 Aug-12 Sep-12 Oct-12 Nov-12 Dec-12 Jan-13 Feb-13 Mar-13 Apr-13 May-13 Jun-13 Jul-13 Aug-13 Sep-13 Oct-13 Nov-13

	May-12	Jun-12	Jul-12	Aug-12	Sep-12	Oct-12	Nov-12	Dec-12	Jan-13	Feb-13	Mar-13	Apr-13	May-13	Jun-13	Jul-13	Aug-13	Sep-13	Oct-13	Nov-13
◆ Total number of cases	2	5	2	9	11	17	14	16	20	11	22	15	17	21	20	16	11	18	11
■ Total number of BVS used	3	6	3	10	25	28	21	26	40	23	49	36	30	47	31	40	17	36	19

Number of BVS used in difference coronary artery from 5/2012-2/2014

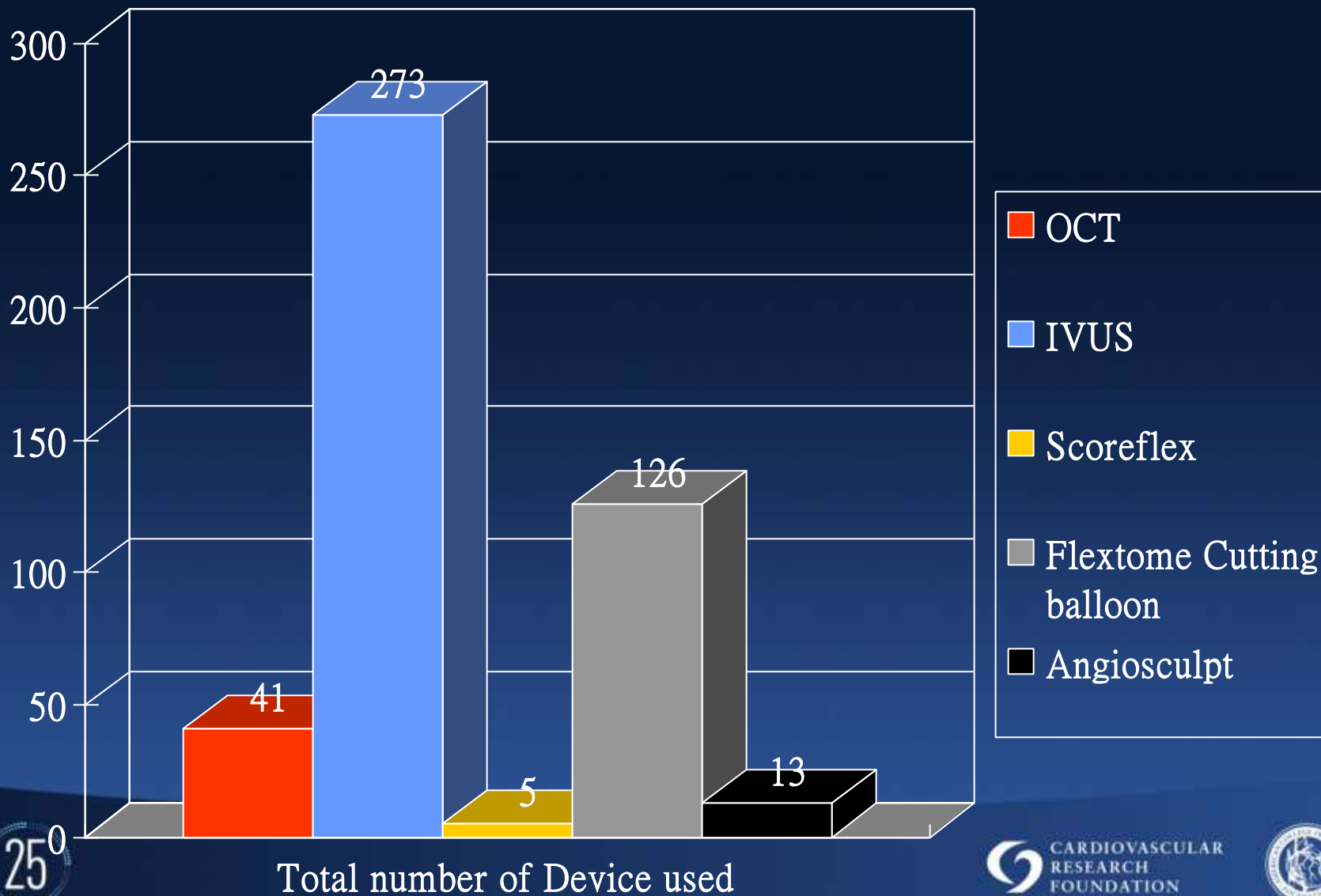


Number of BVS used in different size from 5/2012-2/2014



■ Number of BVS used in Lesion

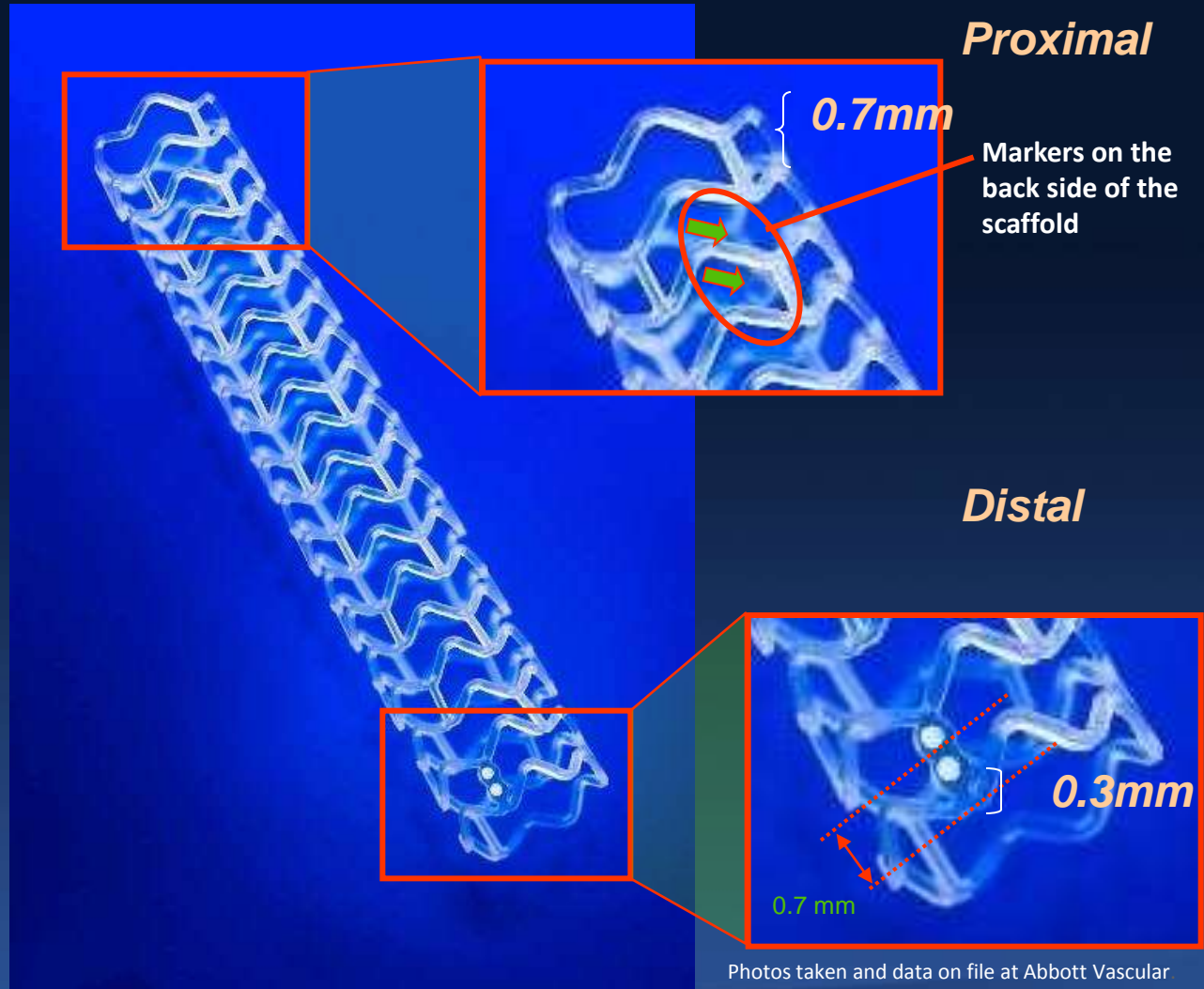
Number of imaging devices and pre dilation devices used in BVS cases used from 5/2012-2/2014 in HKSH



Scaffold Marker Beads

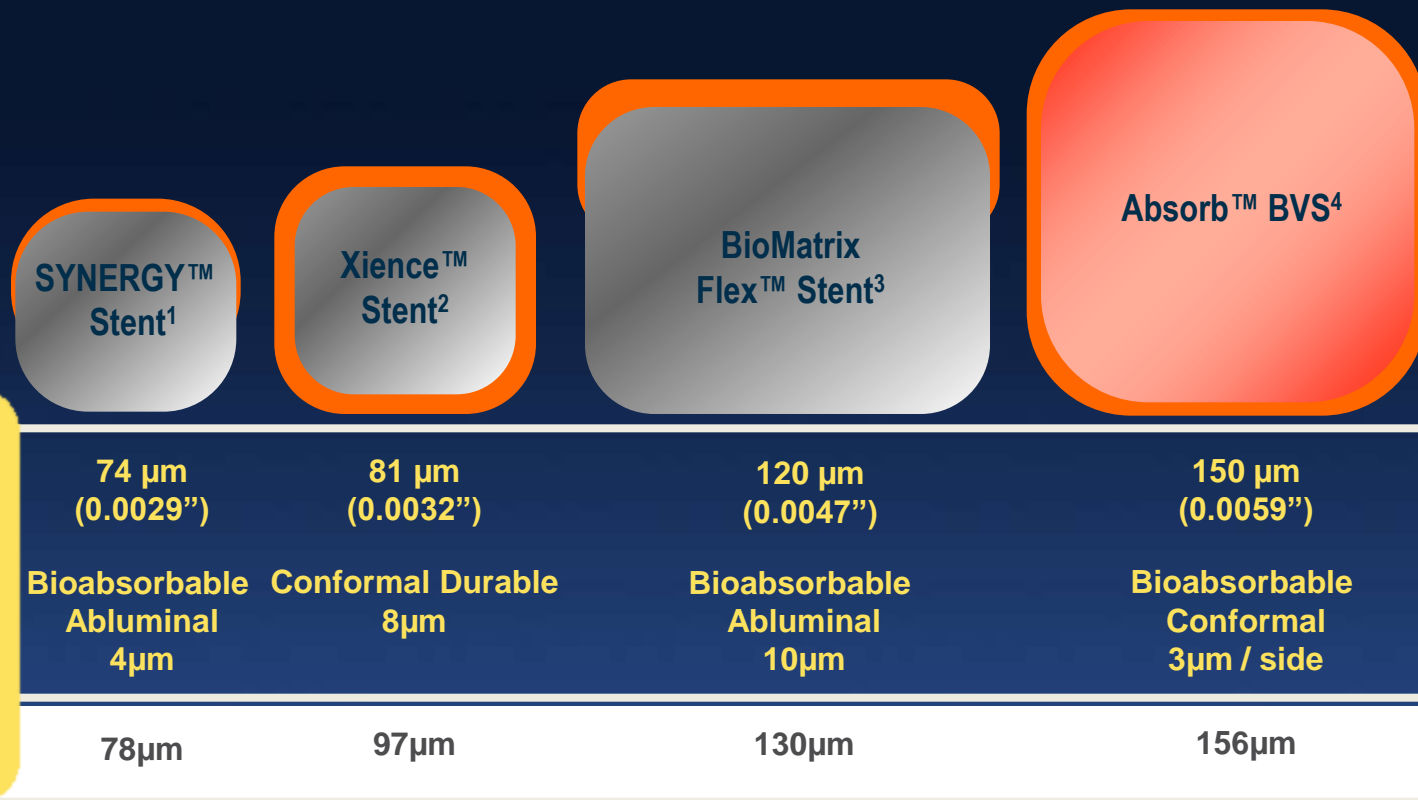
- There are two pairs of platinum marker beads – one pair at each end of the scaffold
- Each end of the scaffold is aligned with markers on the delivery catheter
 - Scaffold markers lie near the inner edge of each marker on the delivery catheter

NOTE: the struts are not visible under fluoroscopy



Bioabsorbable Coatings in Perspective

Relative Coating Thickness



Guiding Catheter Compatibility

- **Guiding catheter compatibility:**
 - **6F / 0.070" / 1.8 mm minimum inner diameter (i.e., inner diameter must be \geq 0.070" / 1.8 mm)**

NOTE: do not insert a 5-in-6, or a 6-in-7 GuideLiner into a 6F or 7F guiding catheter, as doing so will result in an inner diameter that is too small for use with the Absorb BVS:

- The 5-in-6 GuideLiner has an inner diameter of only 0.056"
- The 6-in-7 GuideLiner has an inner diameter of only 0.062"

NOTE: only the 7-in-8 GuideLiner provides an adequate inner diameter (0.071" ID), however, this device requires an 8F guiding catheter

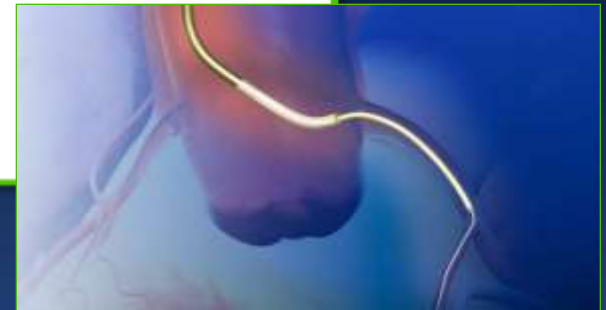


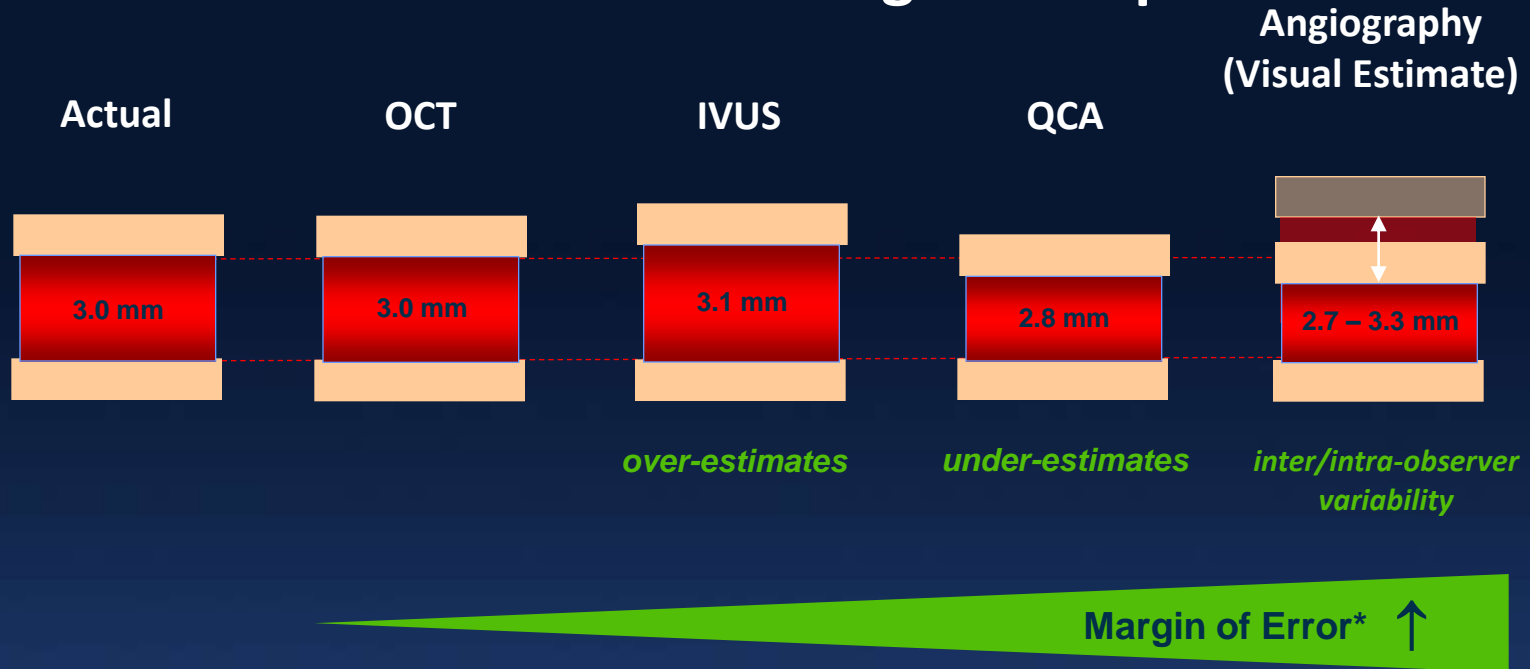
Image from Vascular Solutions website

If challenges with crossing the lesion are encountered, consider an extra back-up support guide catheter

For specific details refer to the Absorb IFU, Sections 10.4 and 10.5

#1 Proper Vessel Sizing

Limitations of Various Vessel Sizing Techniques



Recognize the risk of under-estimating vessel size by visual estimation

Use pre-dilatation to help guide and confirm vessel size

*Margin of error estimates based on resolution for each imaging modality:
Resolution of OCT and IVUS: Bezerra, H.G., J Am Coll Cardiol.: Cardiovasc Interv. 2009; 2: 1035.
Resolution of QCA: Dahm, J. and van Buuren, F. Int J Vasc Med. 2012.
Offset and variability of visual estimate: data on file at Abbott Vascular.

#3 Pay Attention to Expansion Limits

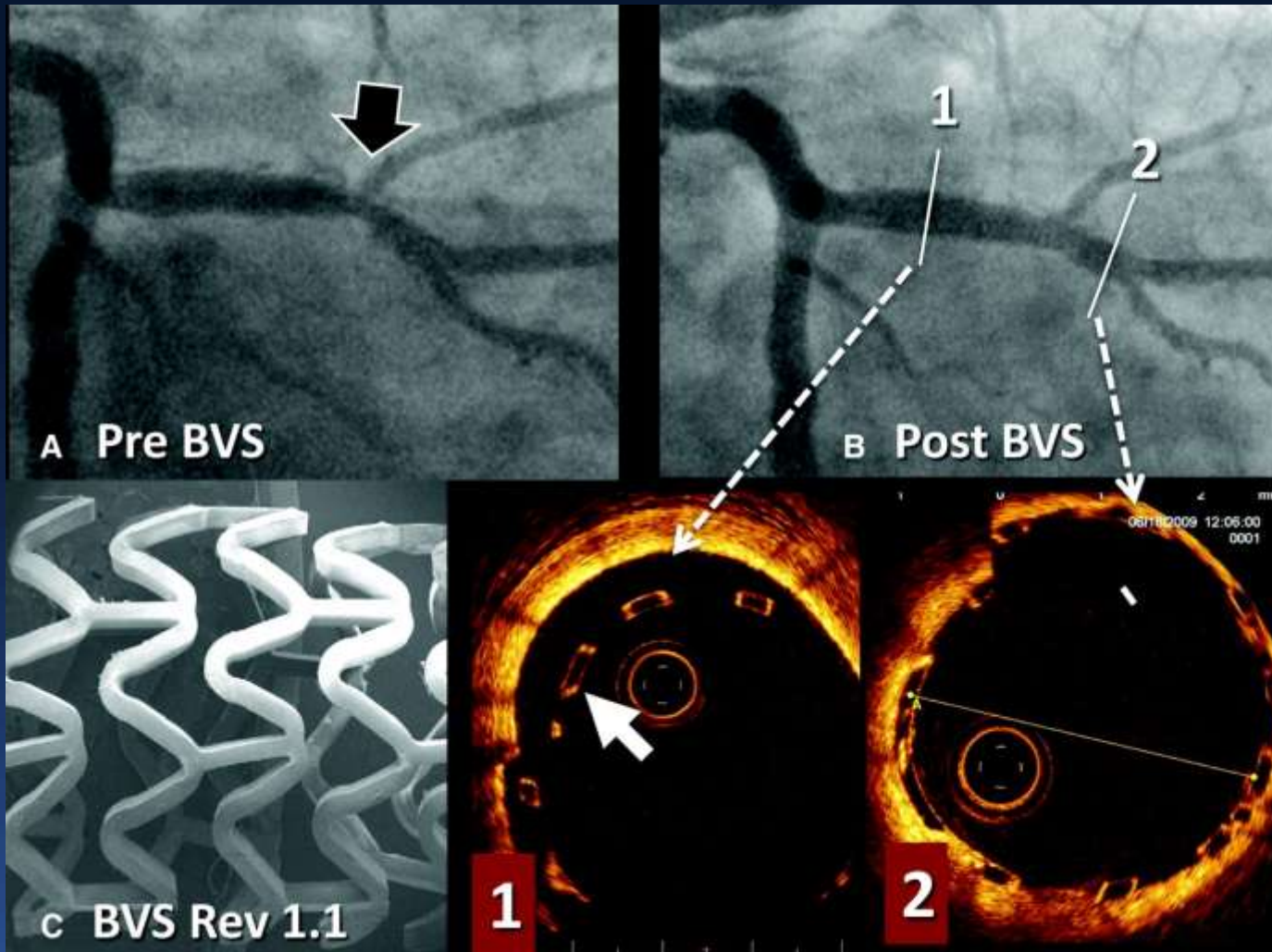
- When expanding the scaffold, be sure to stay within the expansion limits of the device:

Nominal Scaffold Diameter	Maximum Dilatation Limit
2.5 mm	3.00 mm
3.0 mm	3.50 mm
3.5 mm	4.00 mm

CAUTION: Do not dilate the scaffold beyond the maximum dilatation limit. Expansion beyond the dilatation limits listed above, may result in scaffold damage.

This is consistent with the Absorb IFU, Section 10.7

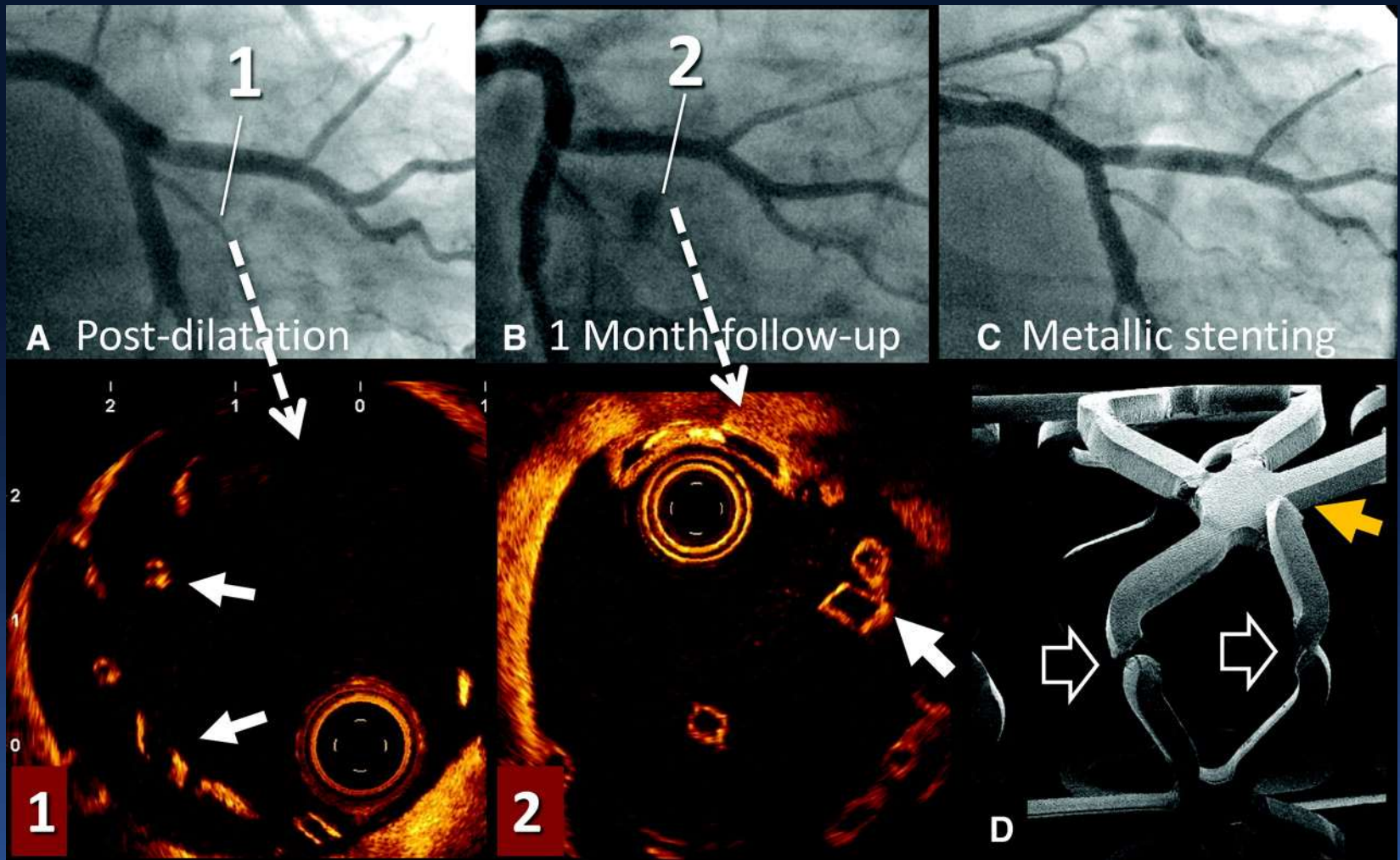
A, Stenosis in the obtuse marginal branch of the left circumflex coronary artery before ABSORB bioresorbable vascular scaffold (BVS) implantation; B, artery after deployment of a 3.0 × 18 mm ABSORB BVS scaffold and after dilatation with a 3.25-mm noncompliant...



Ormiston J et al. *Circ Cardiovasc Interv* 2011;4:535-538

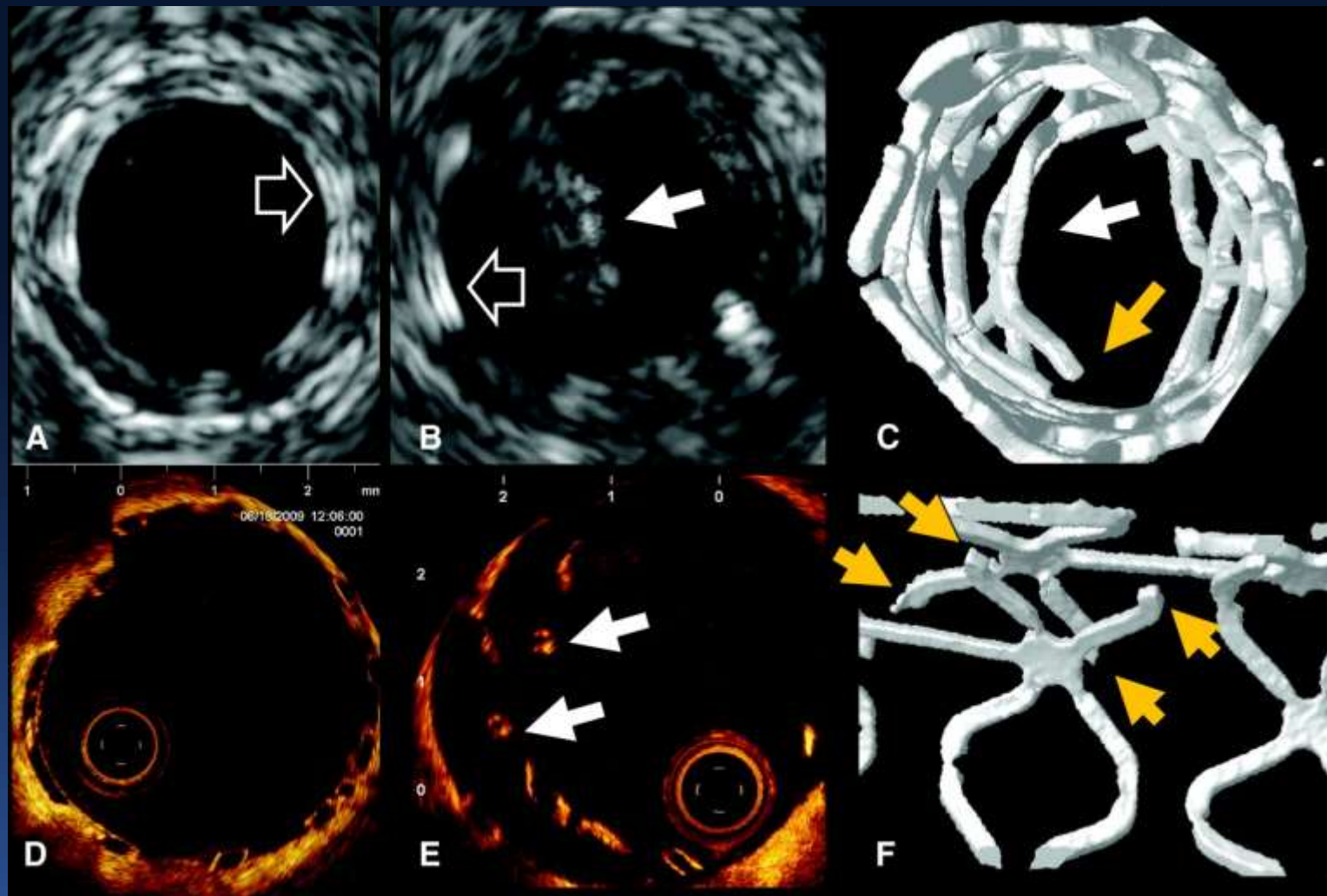
Copyright © American Heart Association

A, Apparently good angiographic result after postdilatation with a compliant 3.5-mm balloon at 16 atm.



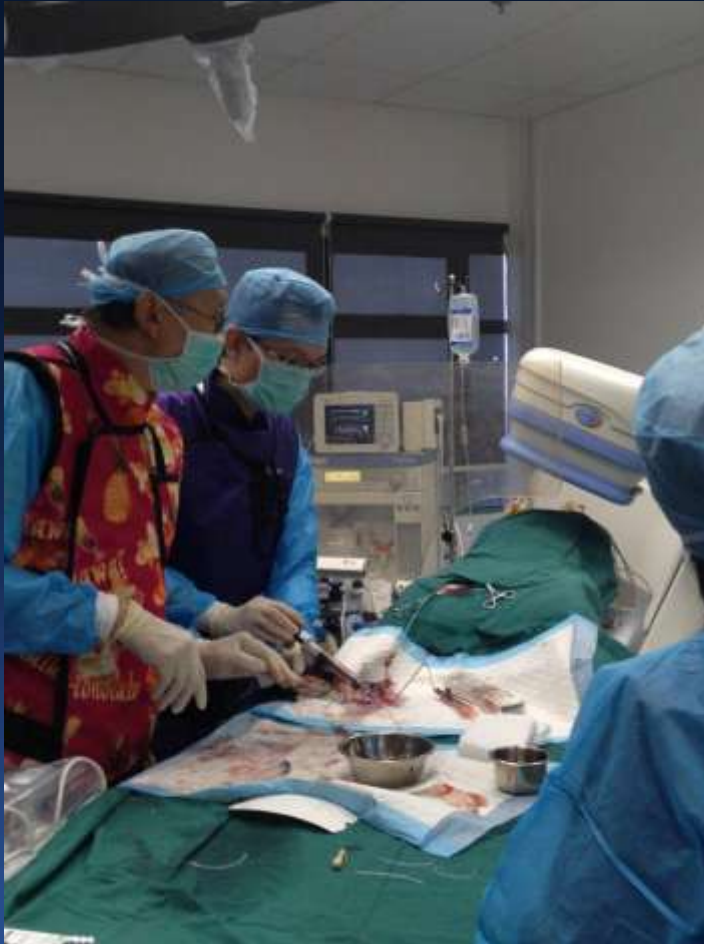Ormiston J et al. *Circ Cardiovasc Interv* 2011;4:535-538

A, Intravascular ultrasonic image of from the distal end of the bioresorbable vascular scaffold (BVS) scaffold in this patient.



Ormiston J et al. *Circ Cardiovasc Interv* 2011;4:535-538

ABSORB Clinical Experience Program (ACE) Offsite Training in Singapore- April 2012

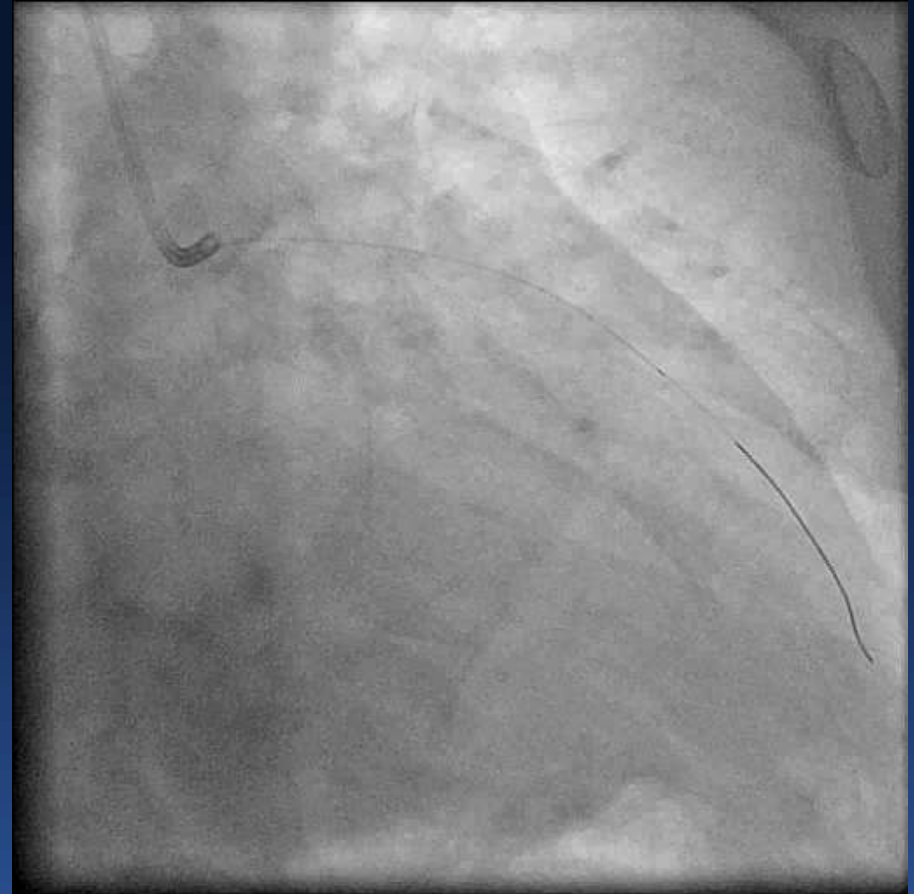
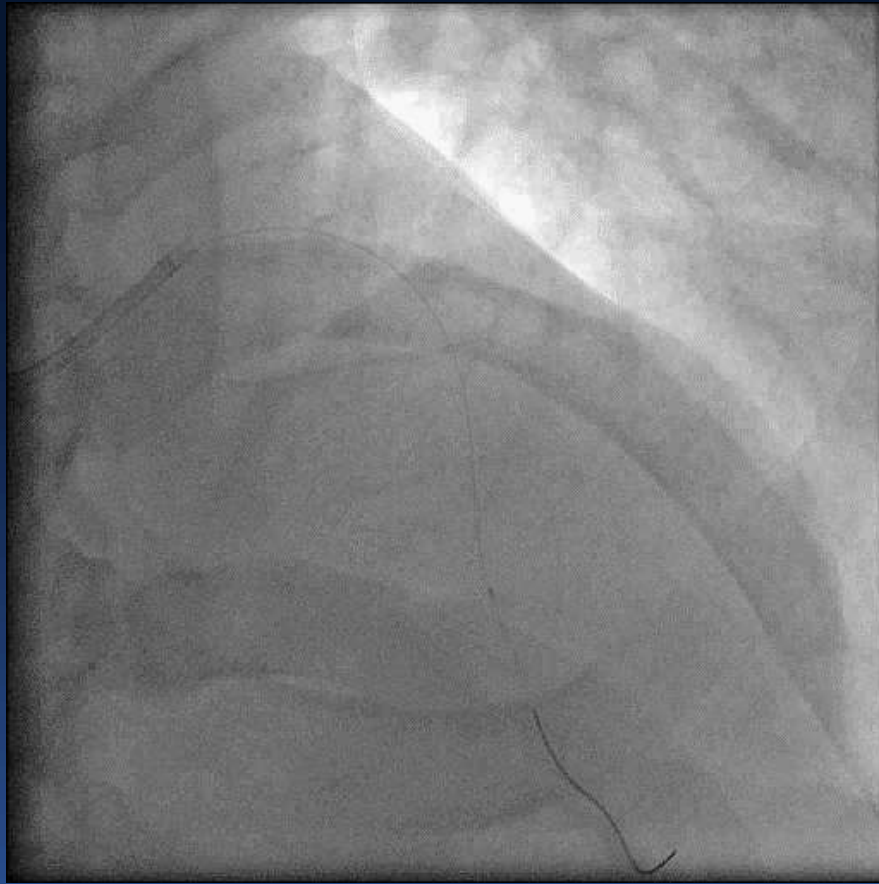
*Our first BVS
experience....*

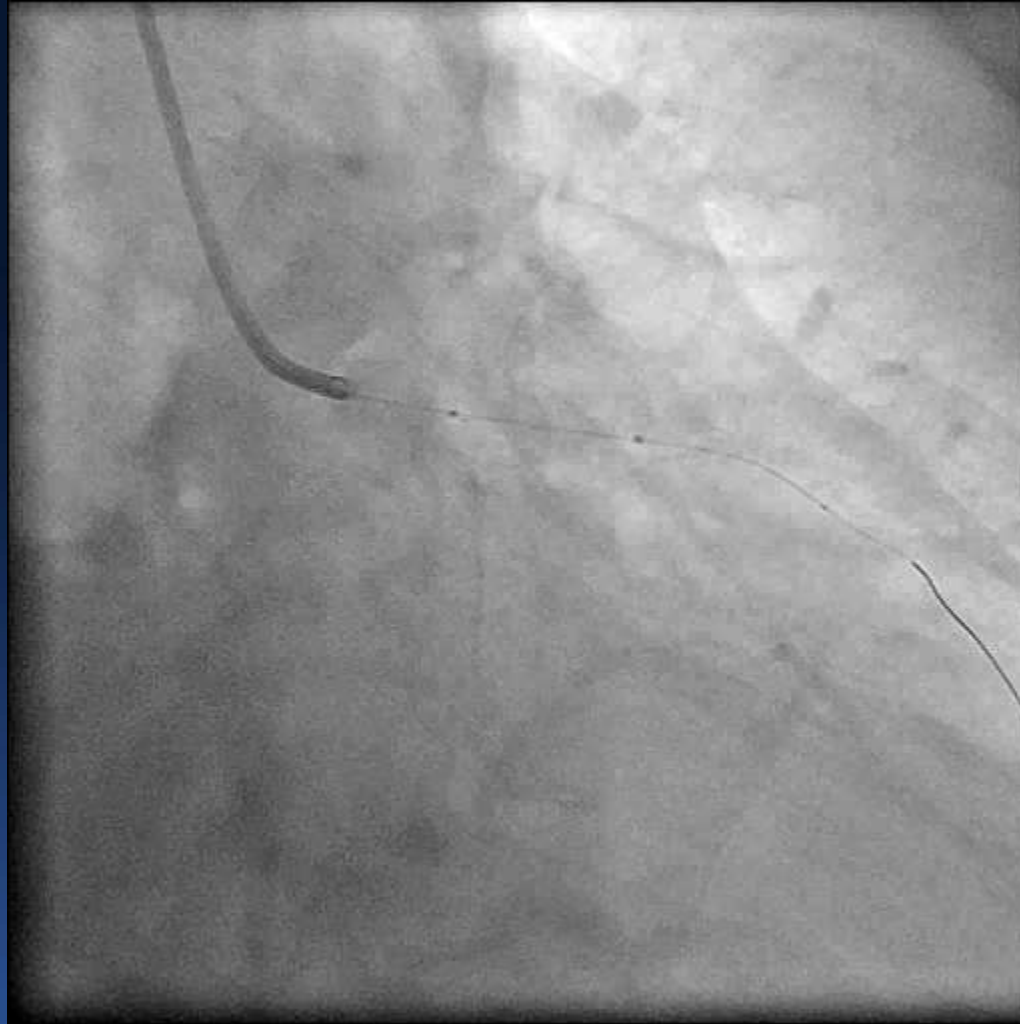
1st ACE case in Hong Kong on 19 May 2012

- M/67 yrs old Indonesian Chinese
- *High cholesterol, strong family history of coronary artery disease (all 5 siblings have either PCI or CABG)*
- *(remarks: his 80+ year-old mother was treated with 2 BVS in Indonesia several months later)*
- *c/o dyspnoea on exertion*
- *CT coronary angiogram: 70% proximal LAD stenosis*
- *CAG: de novo lesion located in pLAD (70% stenosis)*
- Pre-dilatation was done by Trek 2.5/15mm up to 12atm
- BVS 3.0 x 18mm was deployed at 12atm
- Post-dilatation was done by NC Trek 3.25/12mm up to 18atm

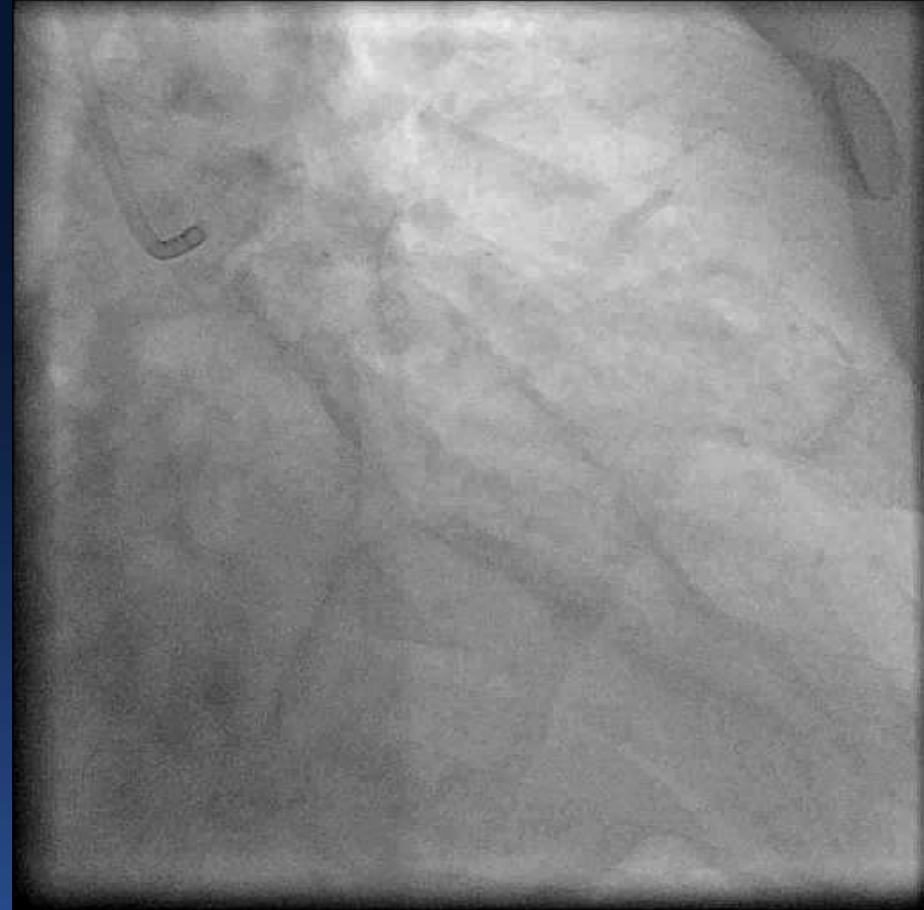
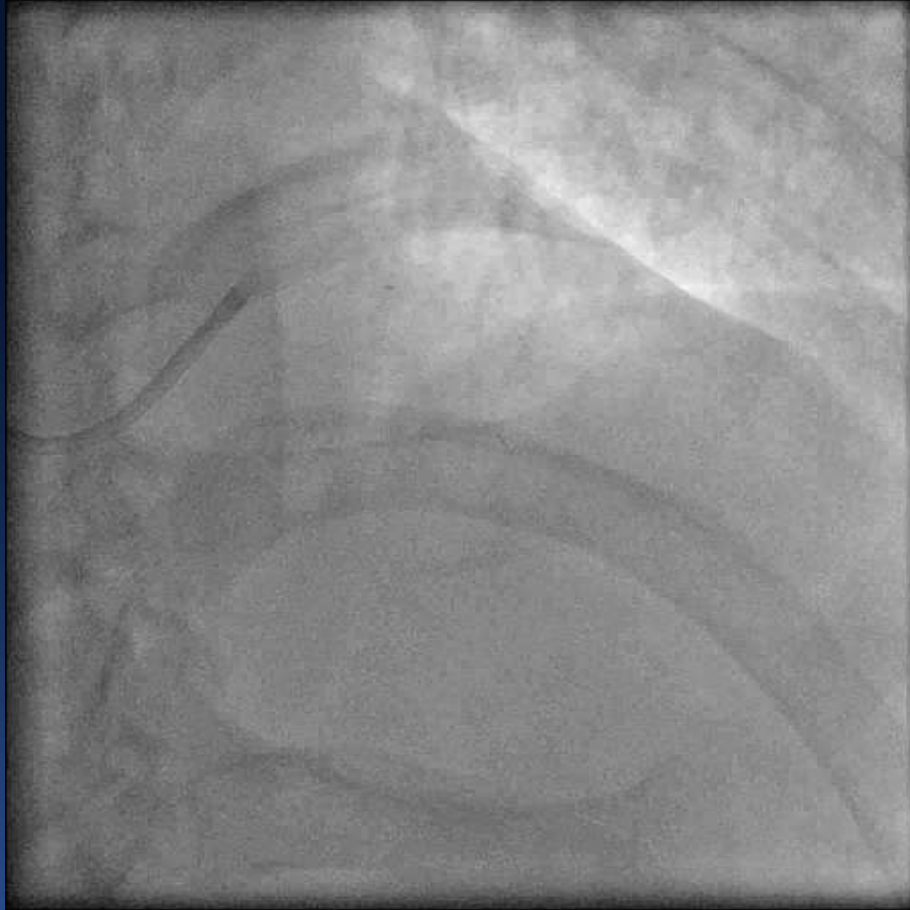Coronary angiogram



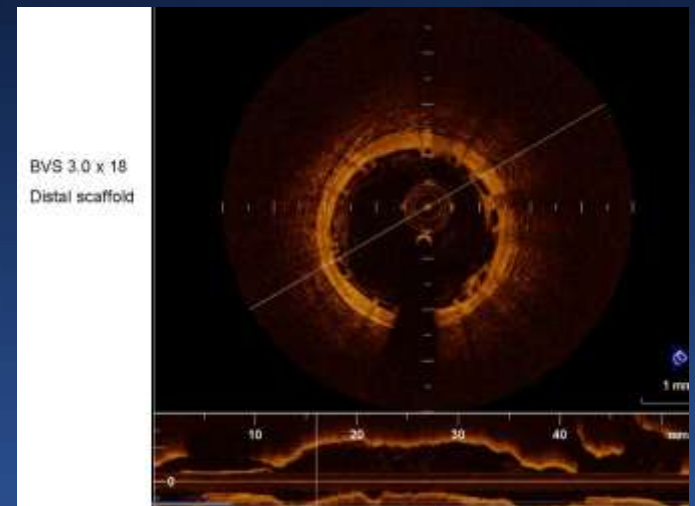
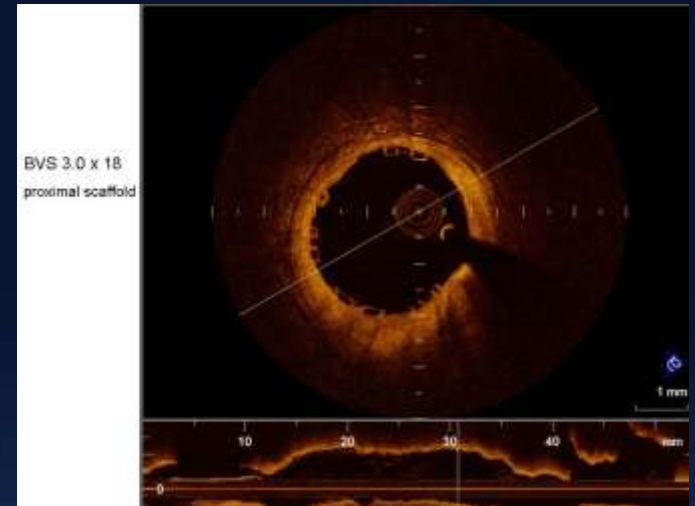
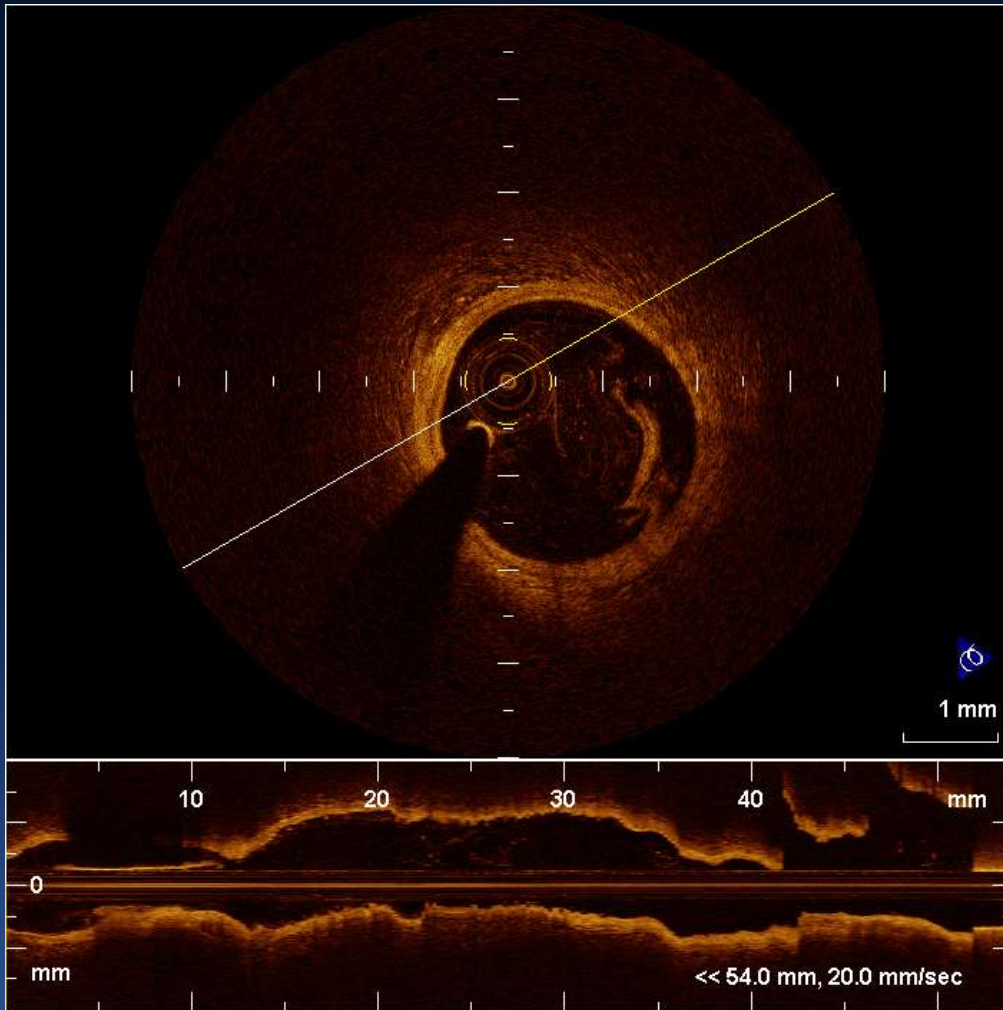
Positioning



Final Angiogram

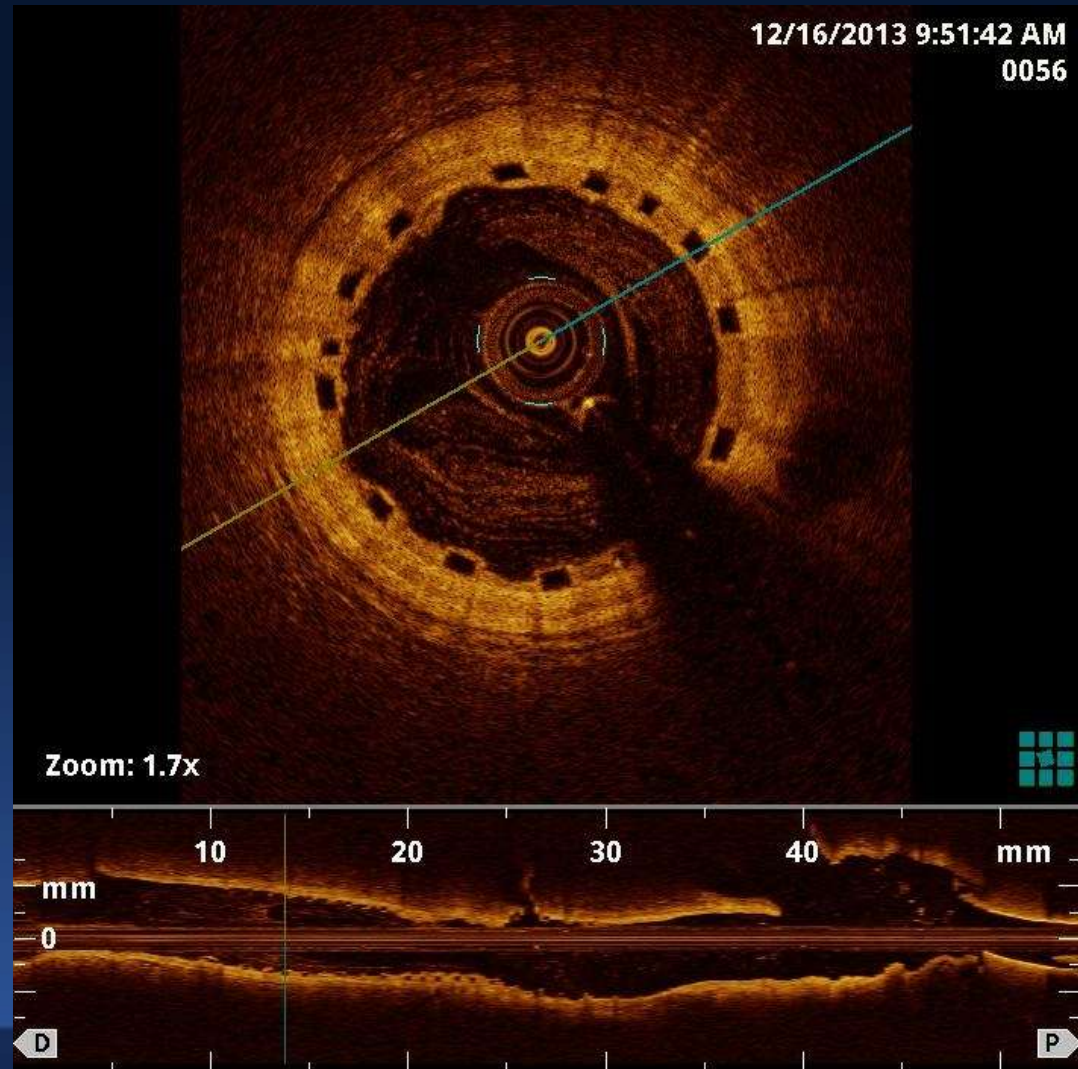


Optical Coherence Tomography (OCT)

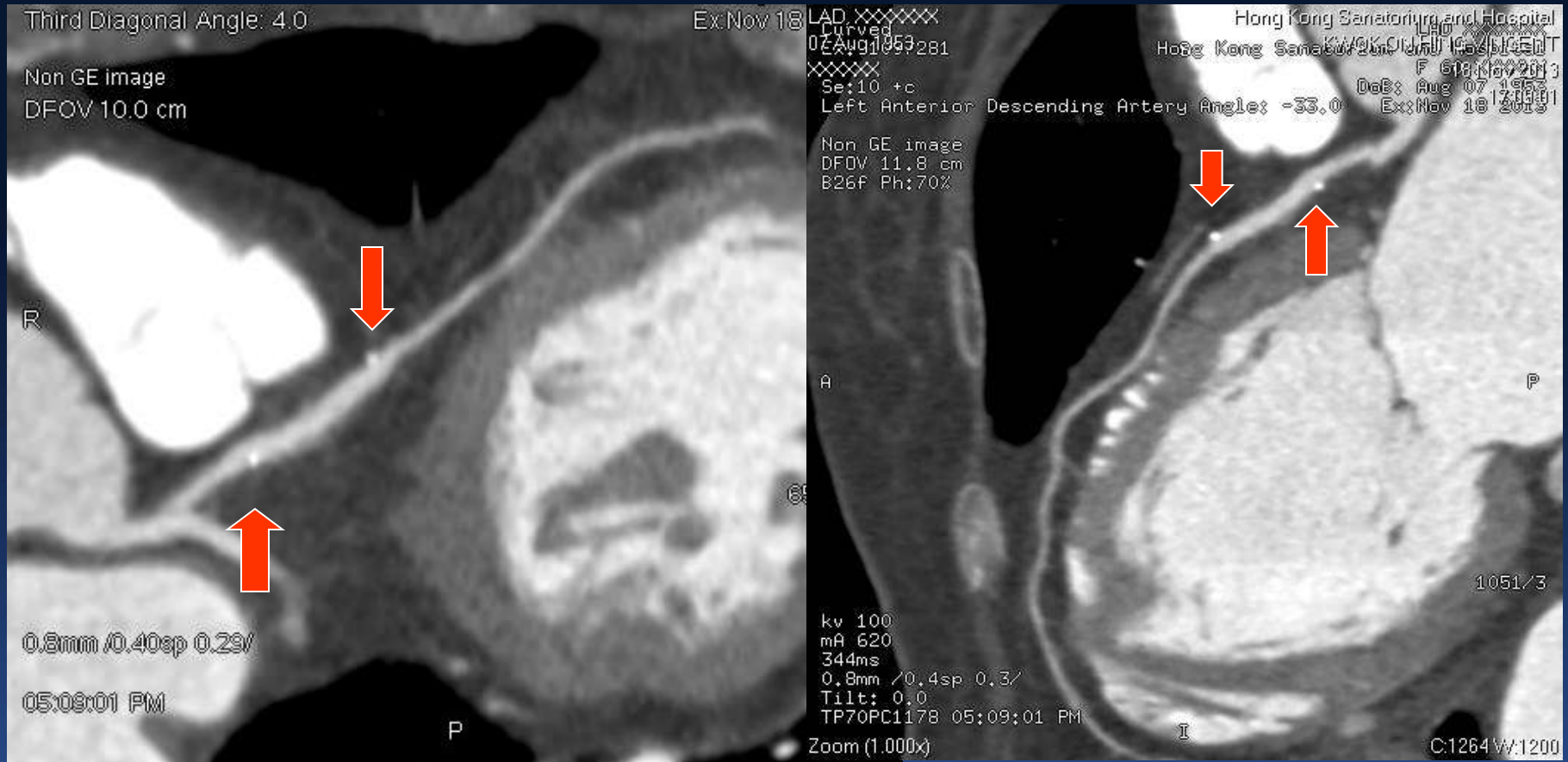


18-month OCT follow-up

OCT showed complete re-endothelialization of the BVS struts



18 month CTA follow-up



CASE #1

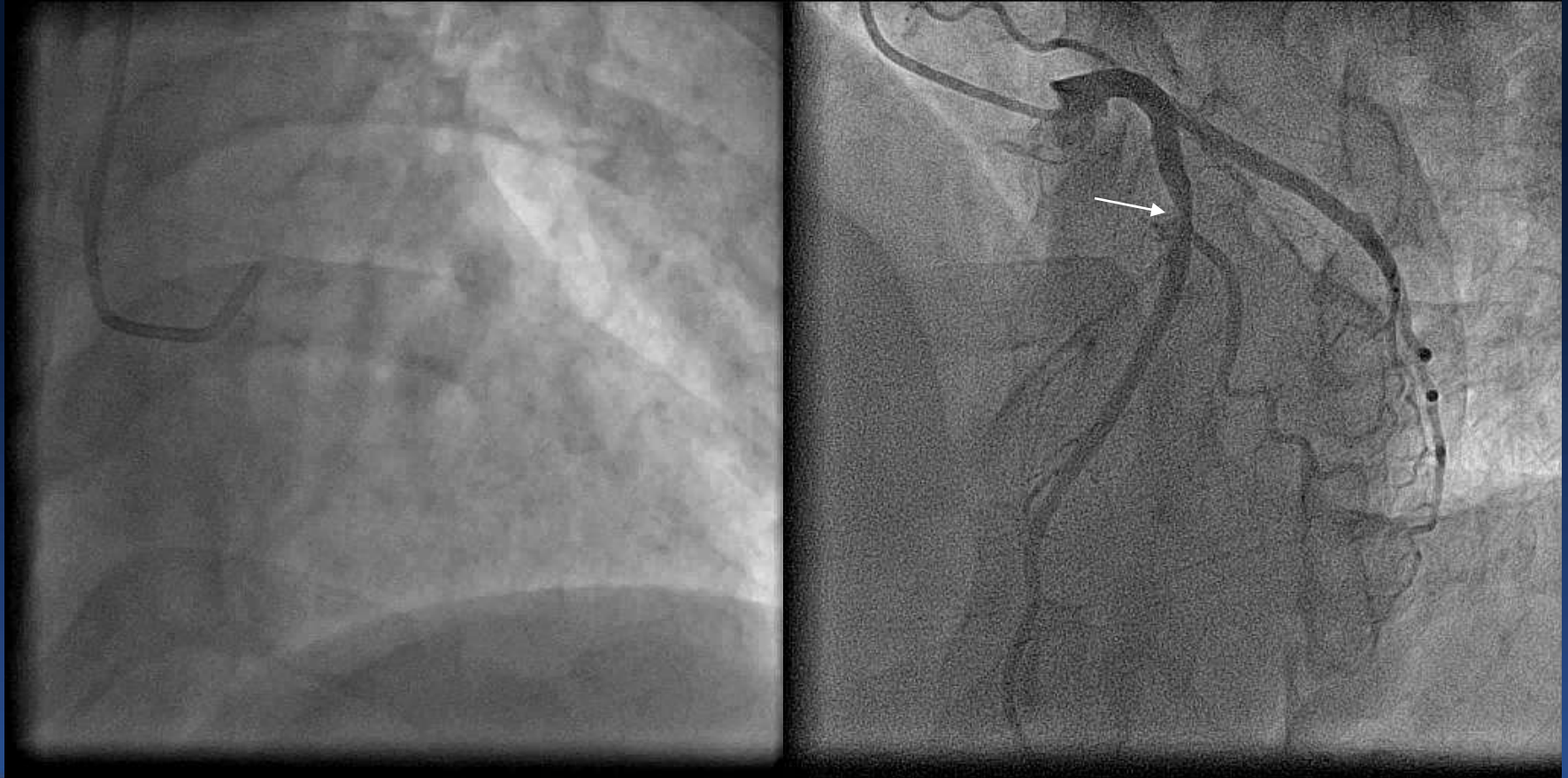- **M/42 years old**
- **Ex-smoker**
- **High cholesterol, Family history of CAD**
- **c/o Recent onset angina on exertion**
- **CT coronary angiogram showed >75% stenosis**

Coronary angiogram

6Fr Right radial approach

5 Fr Tiger II

Critical mid LAD 80% stenosis at D1 bifurcation




Breaking the limits



BVS 3.0x18 mm, test in the air



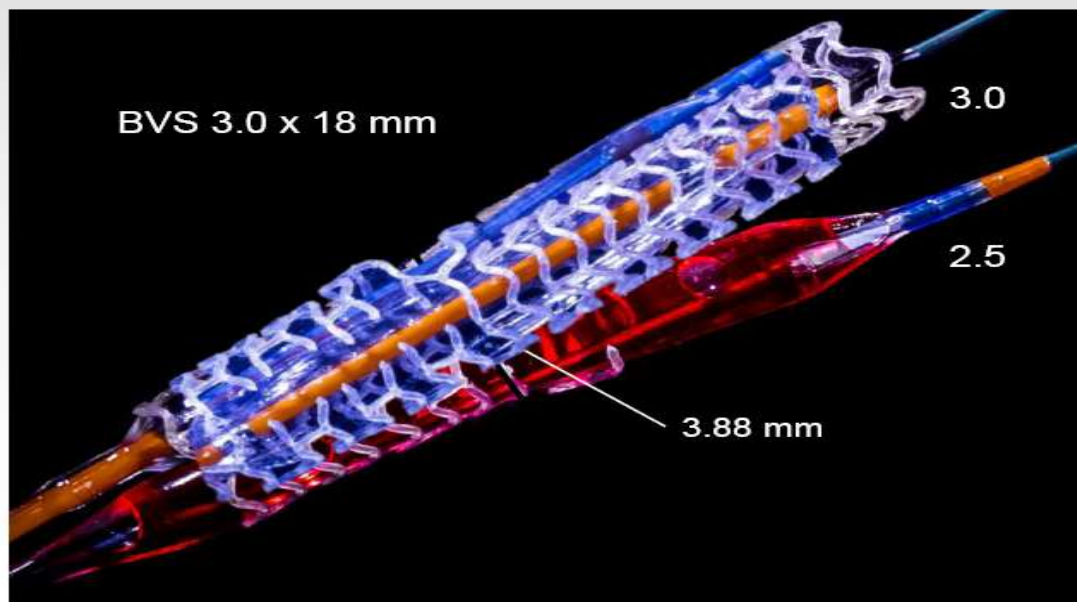
2.0 mm balloon 8 ATM



2.5 mm balloon 8 ATM

Conventional Kissing is prohibited!!

Test in the air



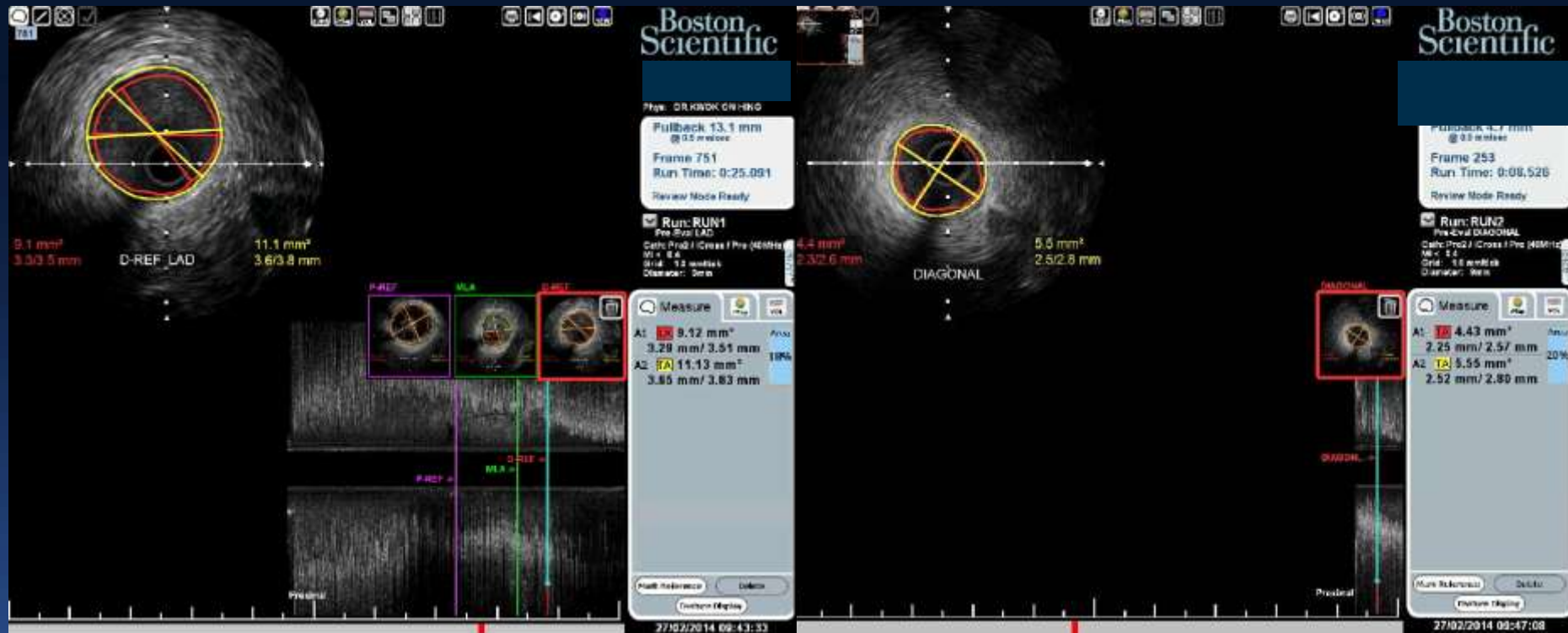
Kissing with two NC balloons 3.0 & 2.5 @ 8 ATM



Pre-IVUS measurement

LAD

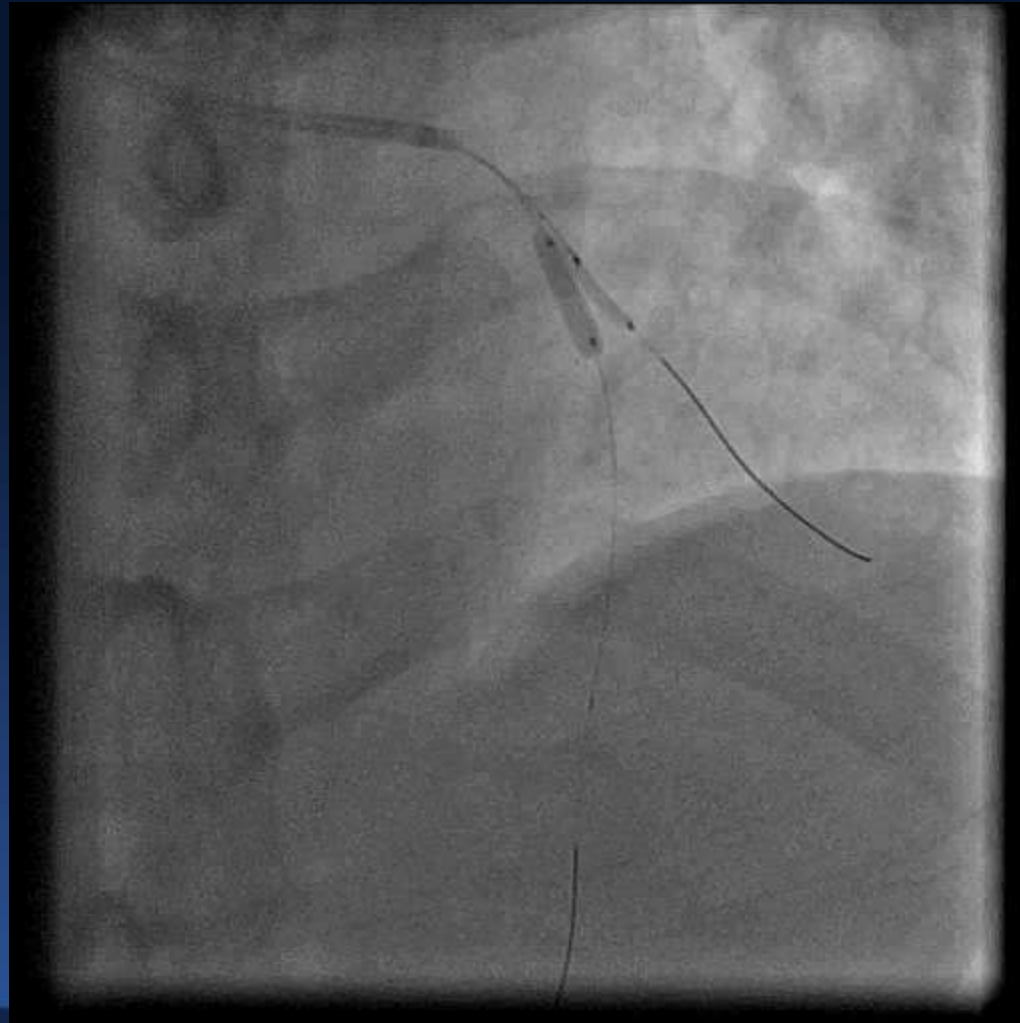
Diagonal



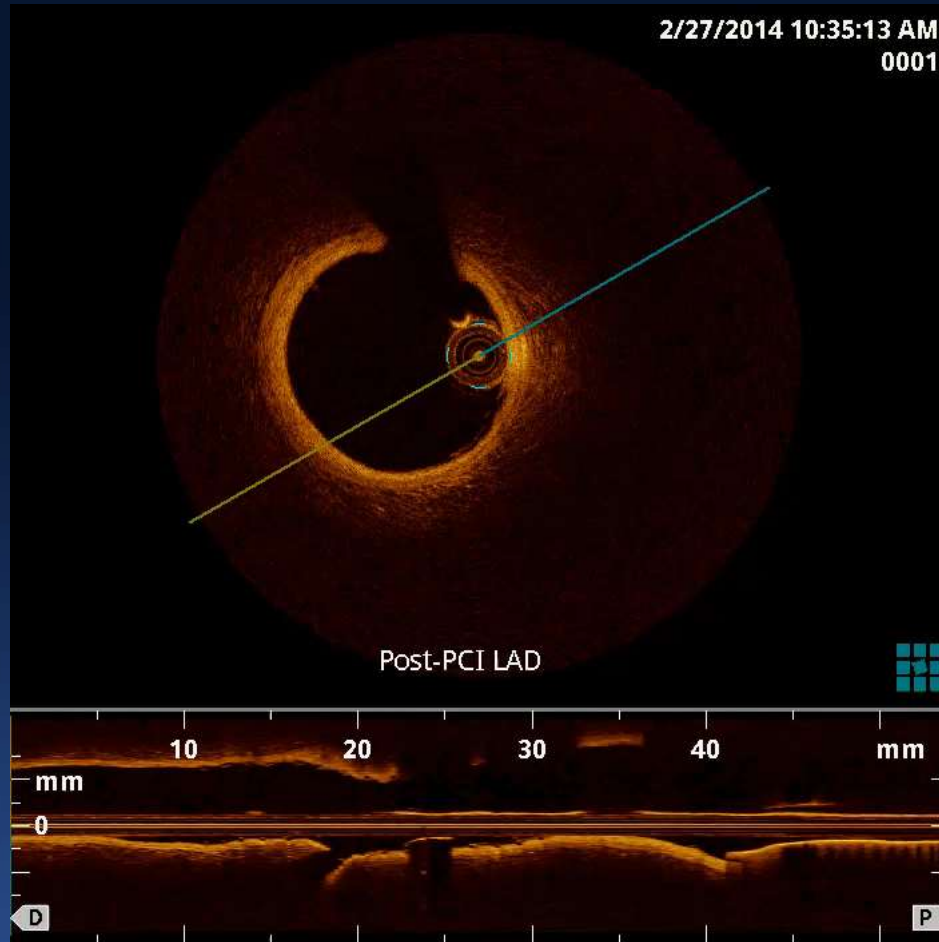
Procedure

- 3.5x10mm Flextome cutting balloon at 12 ATM
- 3.5x18mm Absorb BVS at 10 ATM.
- Post-dilation with 3.5mm NC Trek at 18 ATM
- Post-dilation with 4.0x10mm Sapphire NC at 18 ATM
- D1: re-wired. Dilated with 2.0mm Sapphire II Balloon at 10-12 ATM
- Final Kissing with “snuggle balloons”-Mini-Kiss: 3.5mNC Trek at LAD and 2.0mm Sapphire II at D1 at 5 ATM each

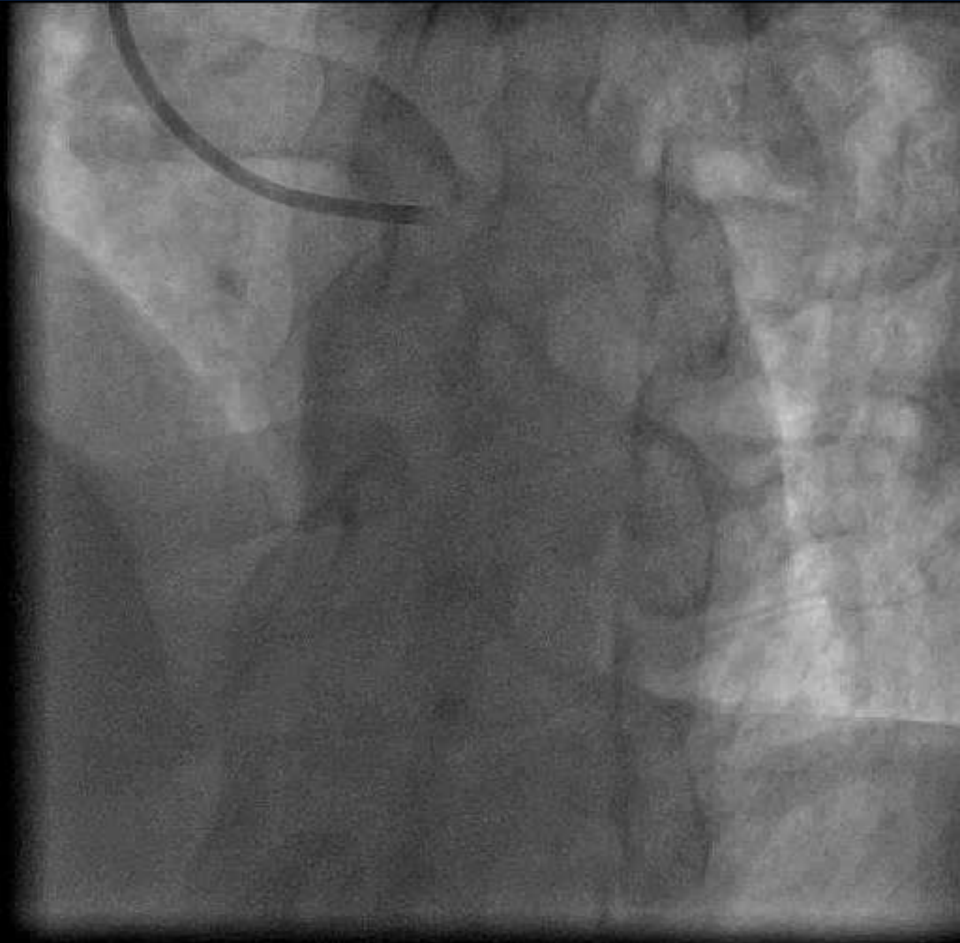
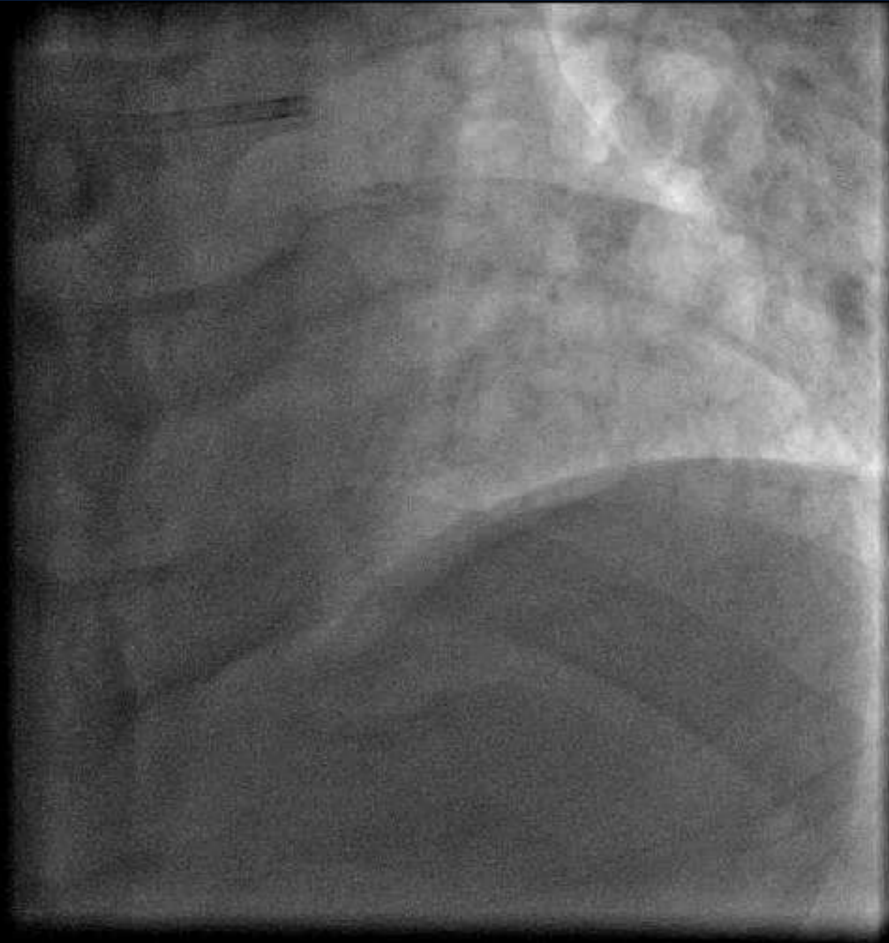
Kissing with snuggle balloons : 3.5mm and 2.0mm at 5 ATM



OCT



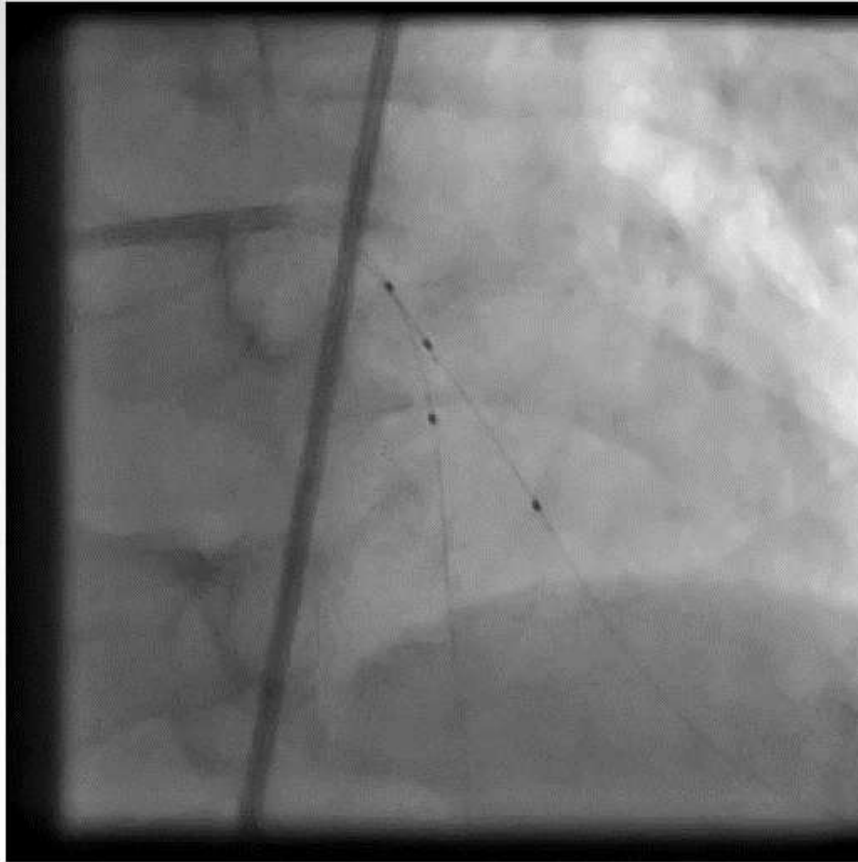
Final angiogram



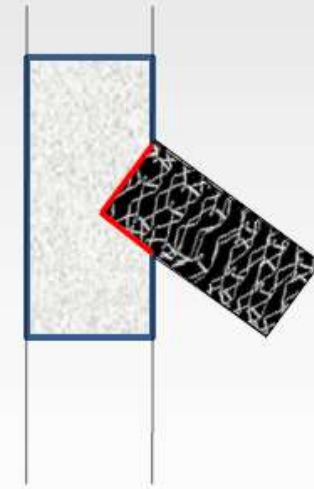
What if there's acute closure or dissection of the Diagonal?



Modified 'T' stenting or TAP technique



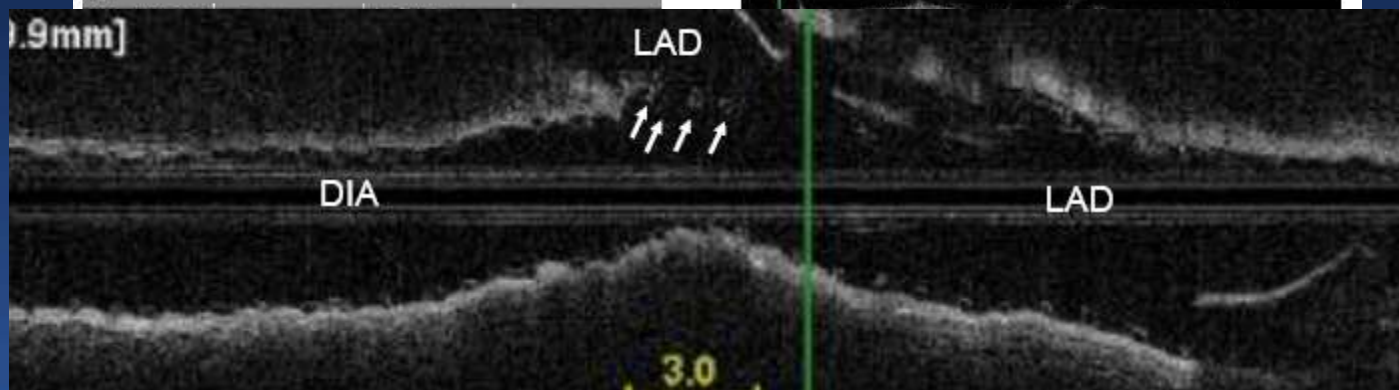
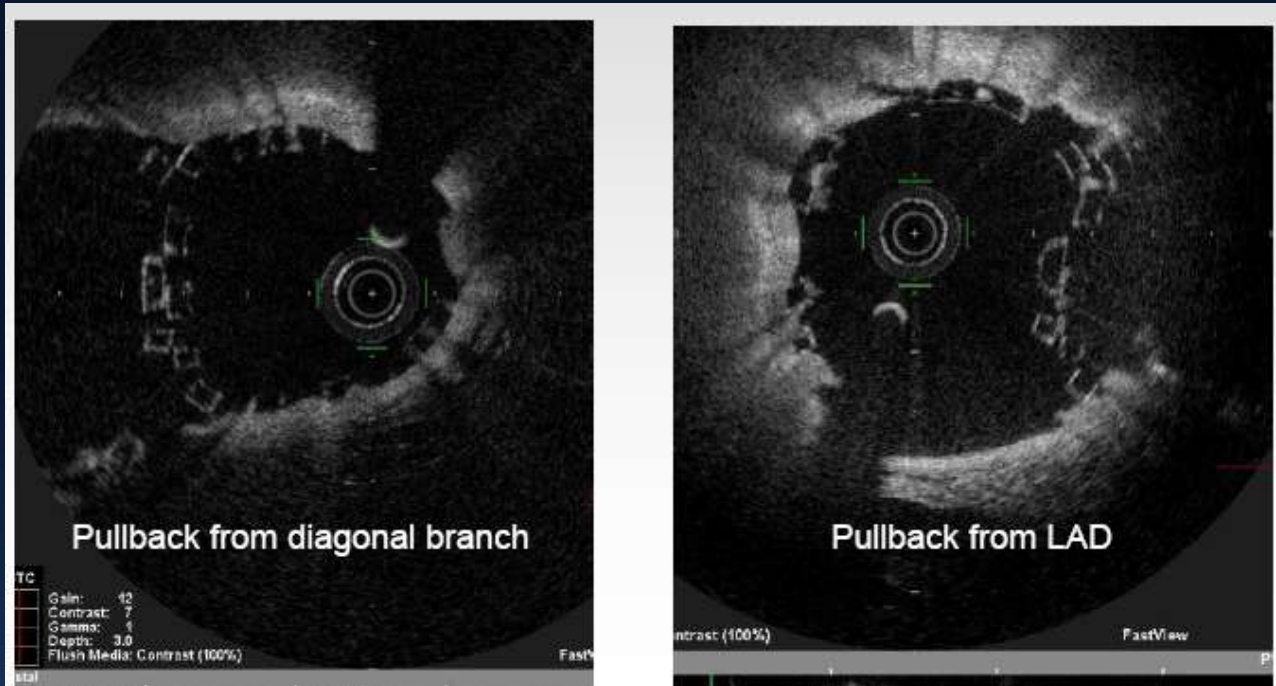
SB BVS positioning



TAP

TAP= T And Protrusion

OCT

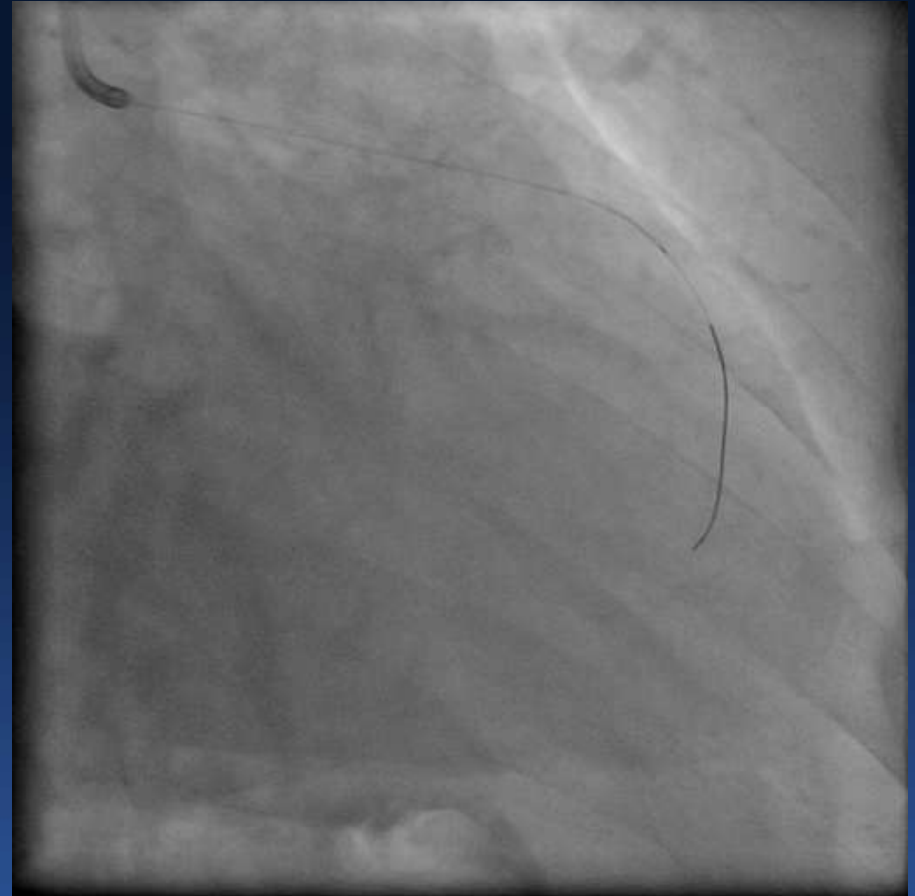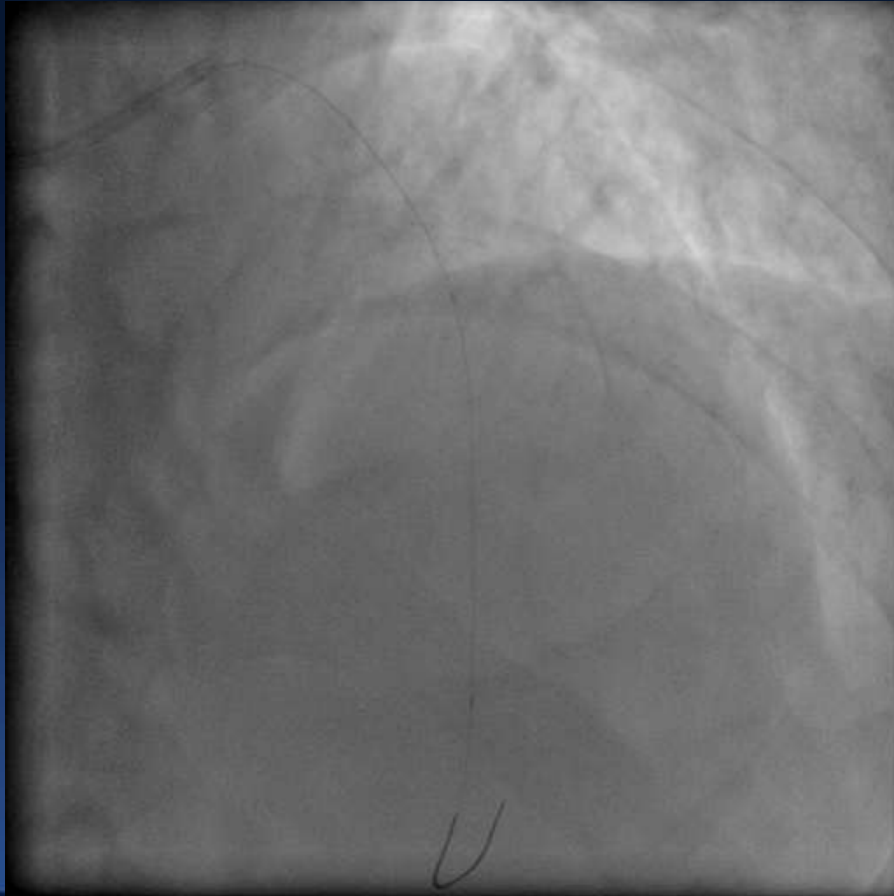


Neo-Carina

Case Study

- **62 year-old man, complaining of angina on exertion.**
- **High cholesterol. Hypertension. Family history of coronary artery disease.**
- **CT coronary angiogram showed multiple stenoses of left anterior descending artery. (LAD)**
- **Cardiac catheterization confirmed multiple lesions over LAD; Diseased diagonals; Normal RCA**

Multiple critical stenoses

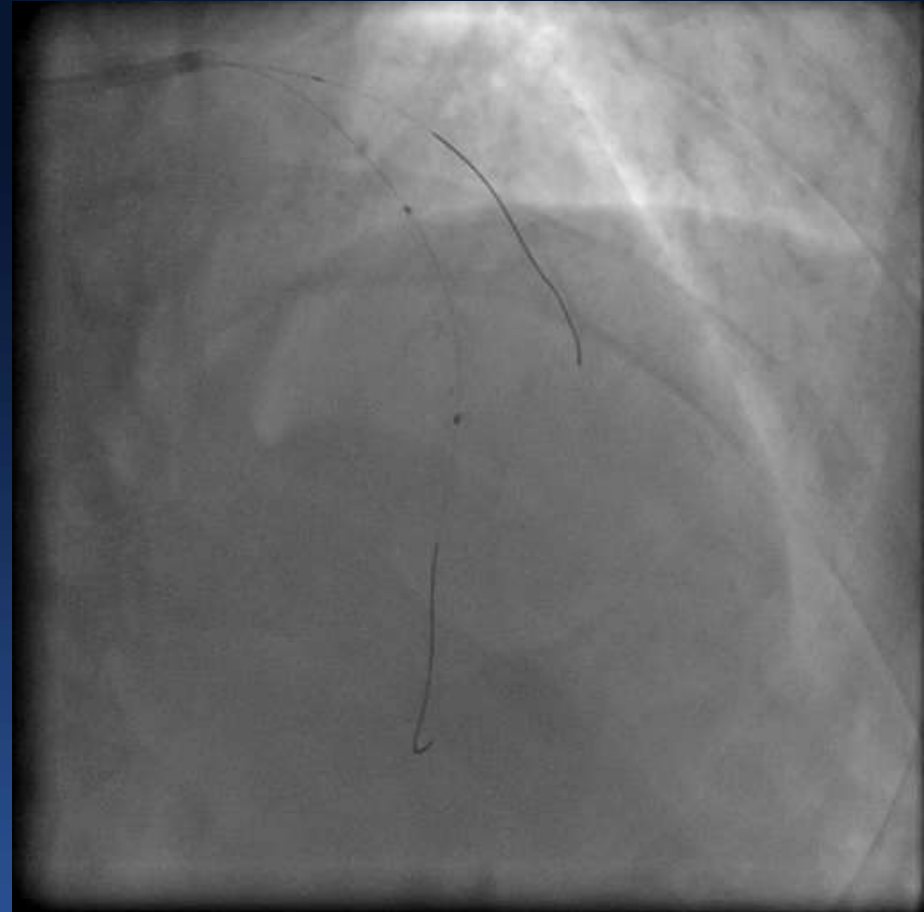
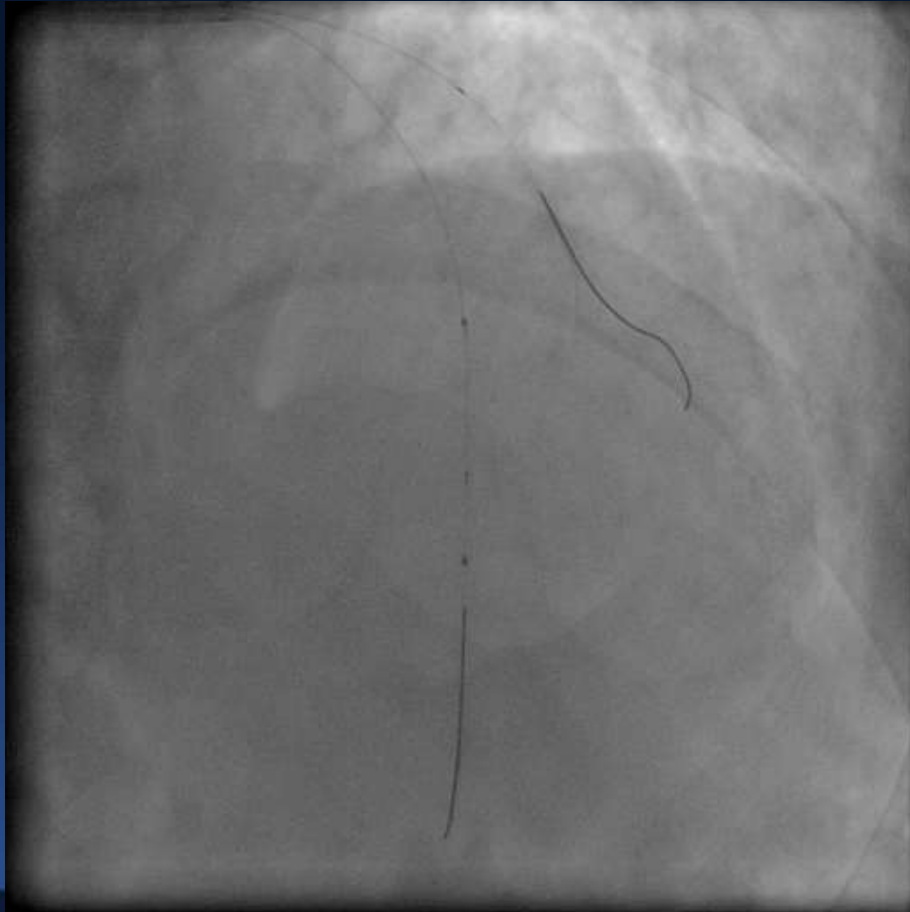


LAD: Pre-dilated with NC Trek 2.5x15mm up to 18 ATM

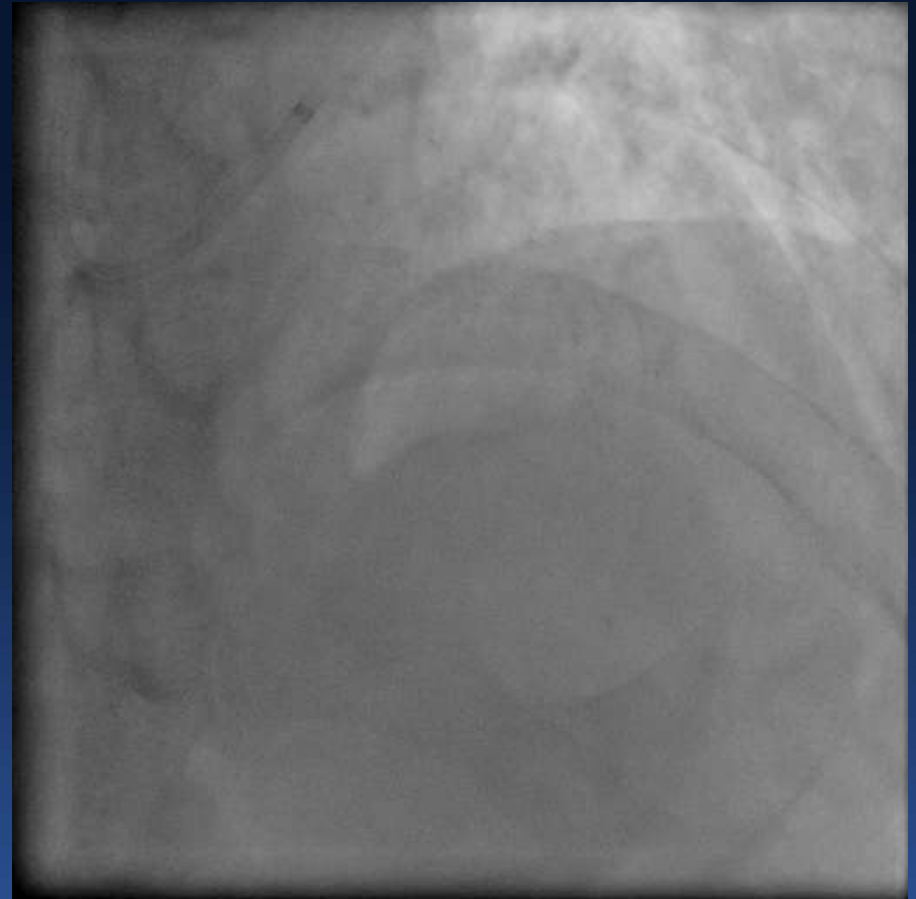
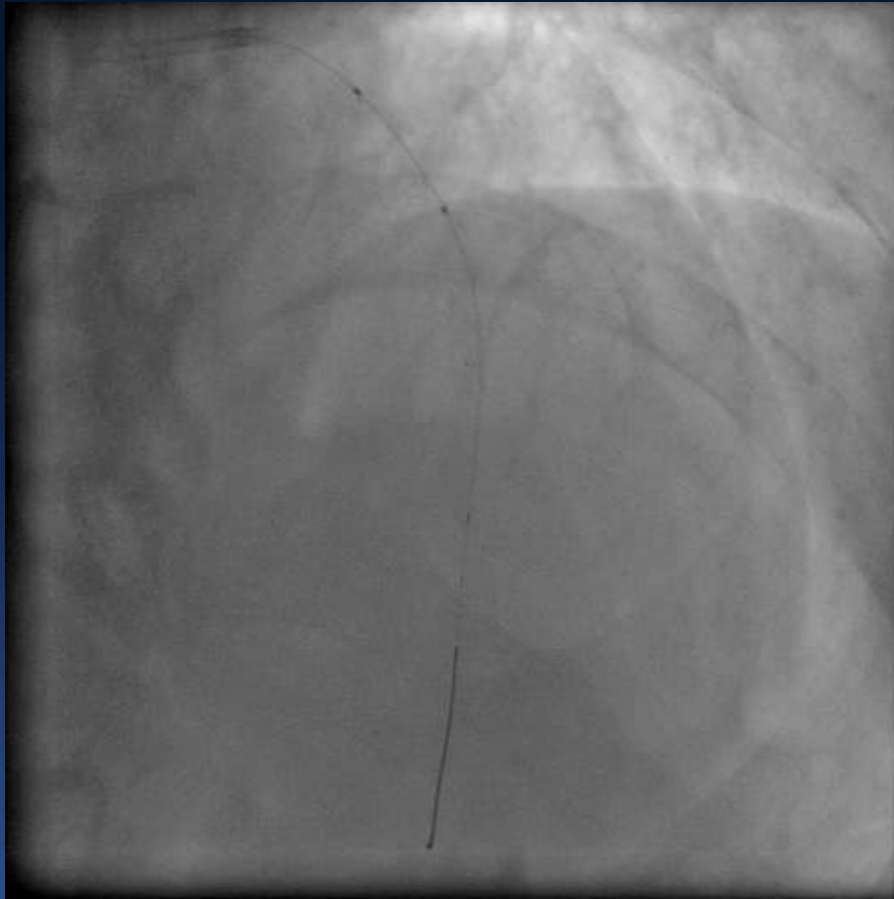
D1: POBA with 2.0mm Mini-Trek

Absorb BVS 2.5x28mm deployed distally

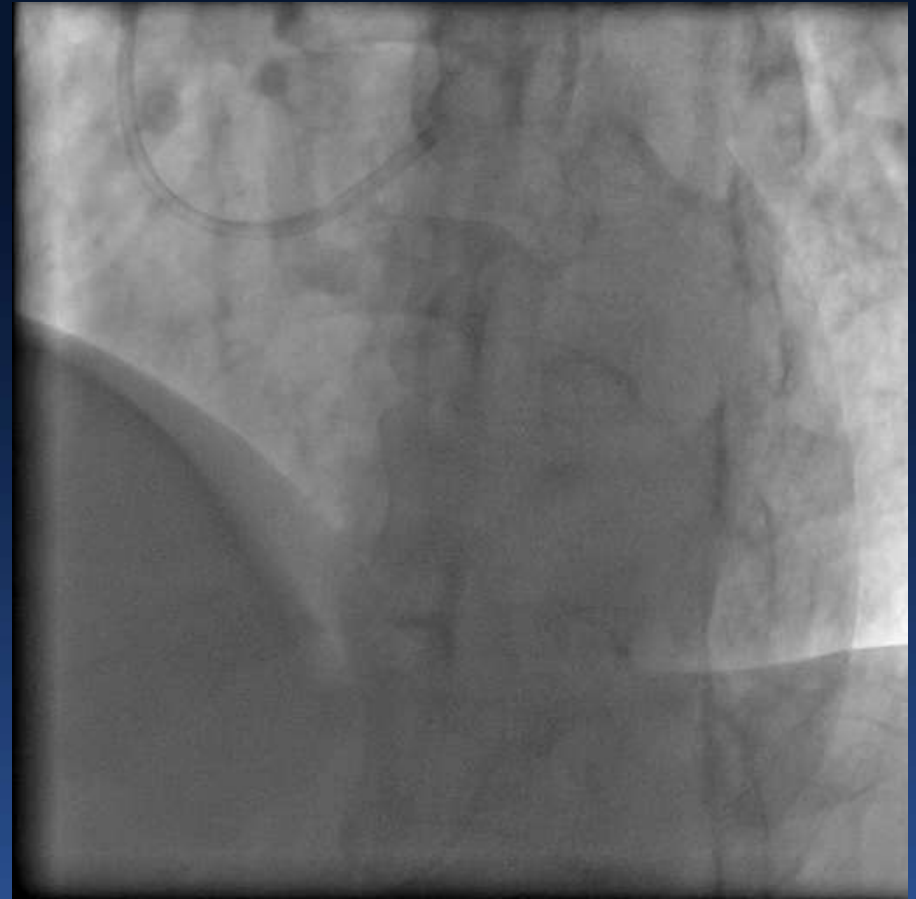
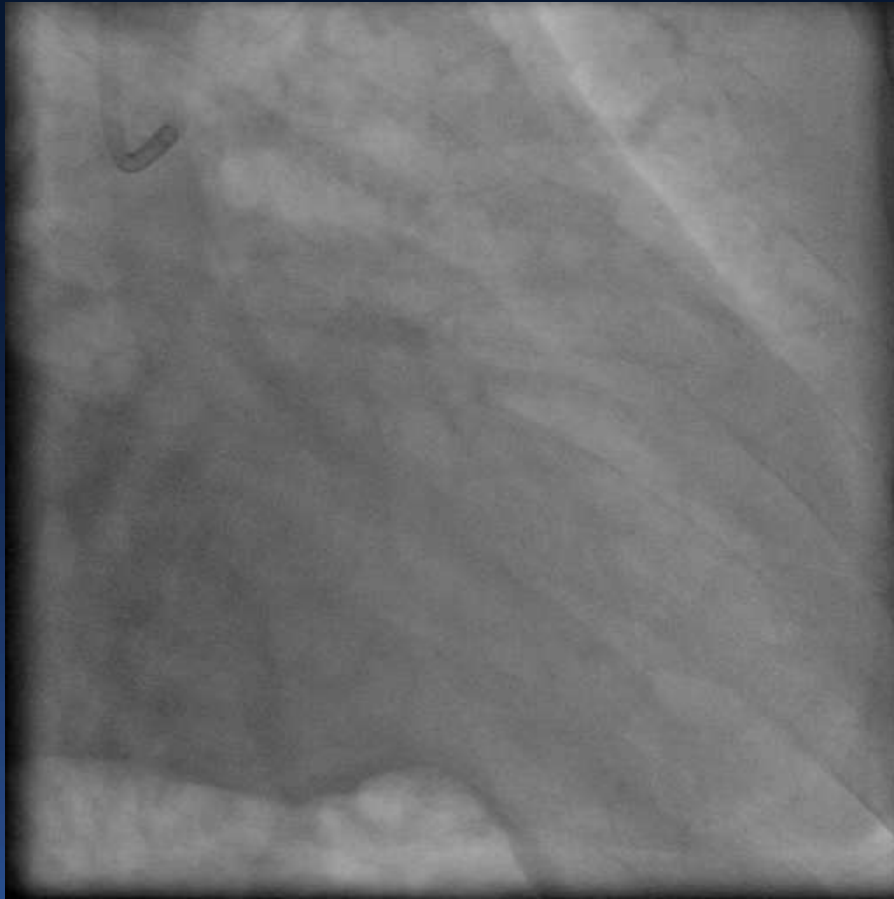
Absorb BVS 3.0x18mm deployed at mid segment

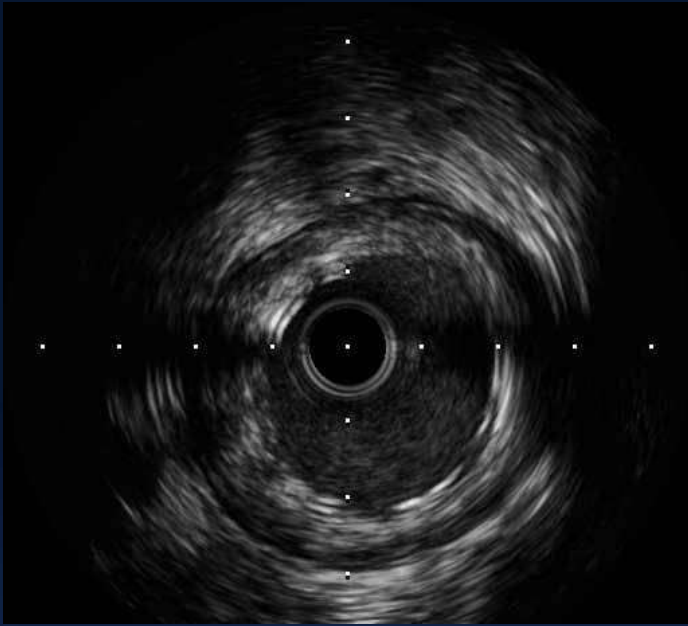


Absorb BVS 3.0x18mm deployed proximally
All BVS further expanded with 3.0 NC Trek up to 20ATM
Proximal BVS further expanded with 3.25mm NC Trek up to 20 ATM

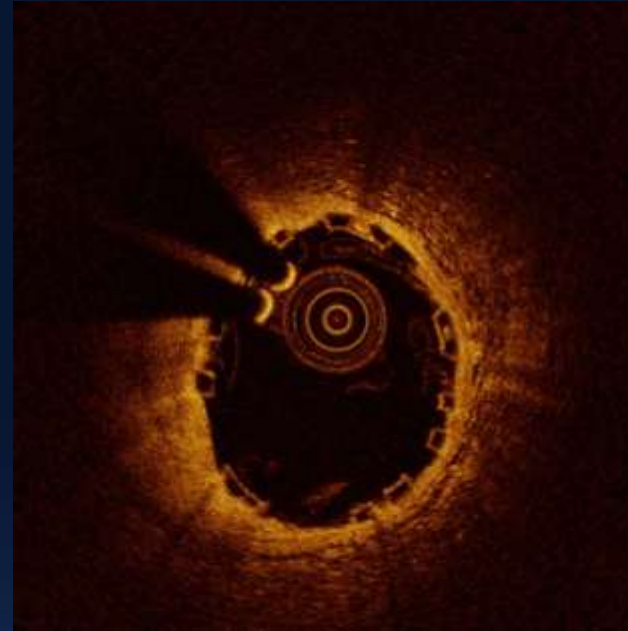


Multiple overlapping BVS

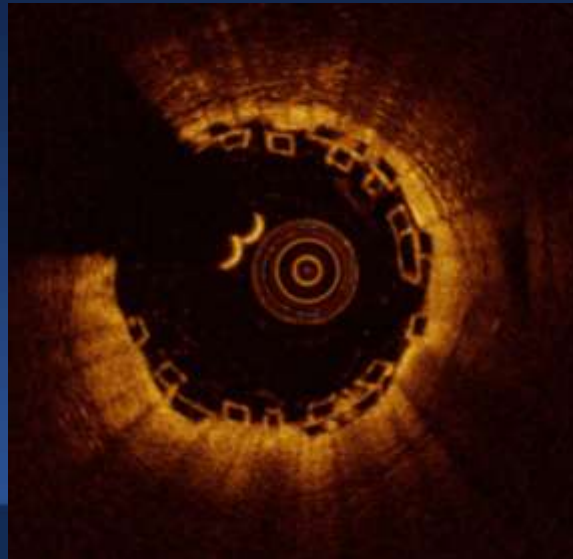




Intravascular ultrasound image of BVS



Optical Coherence Tomography image of BVS

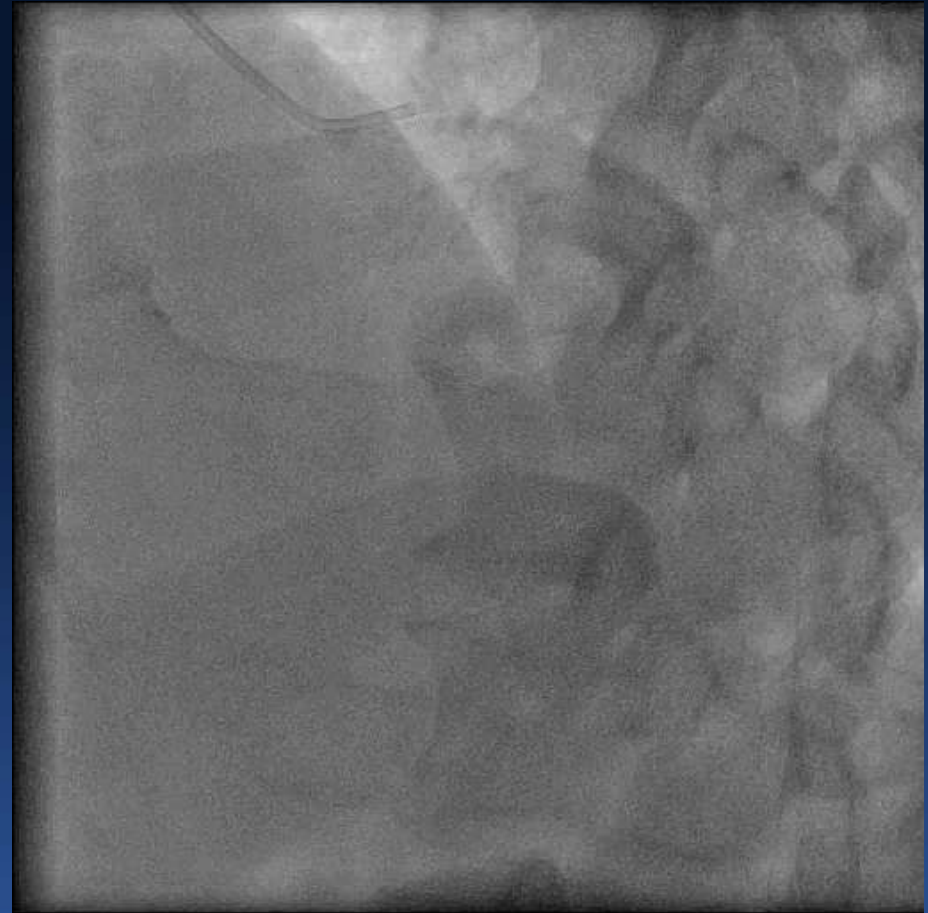
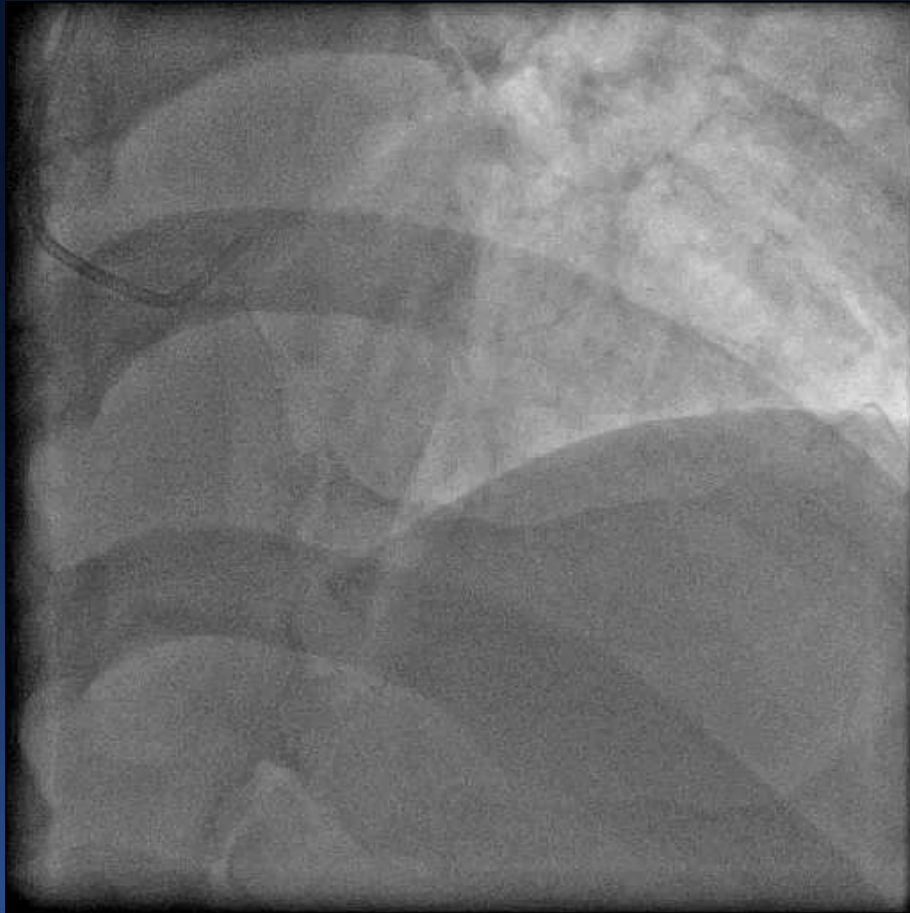

OCT image of BVS at overlapping segment

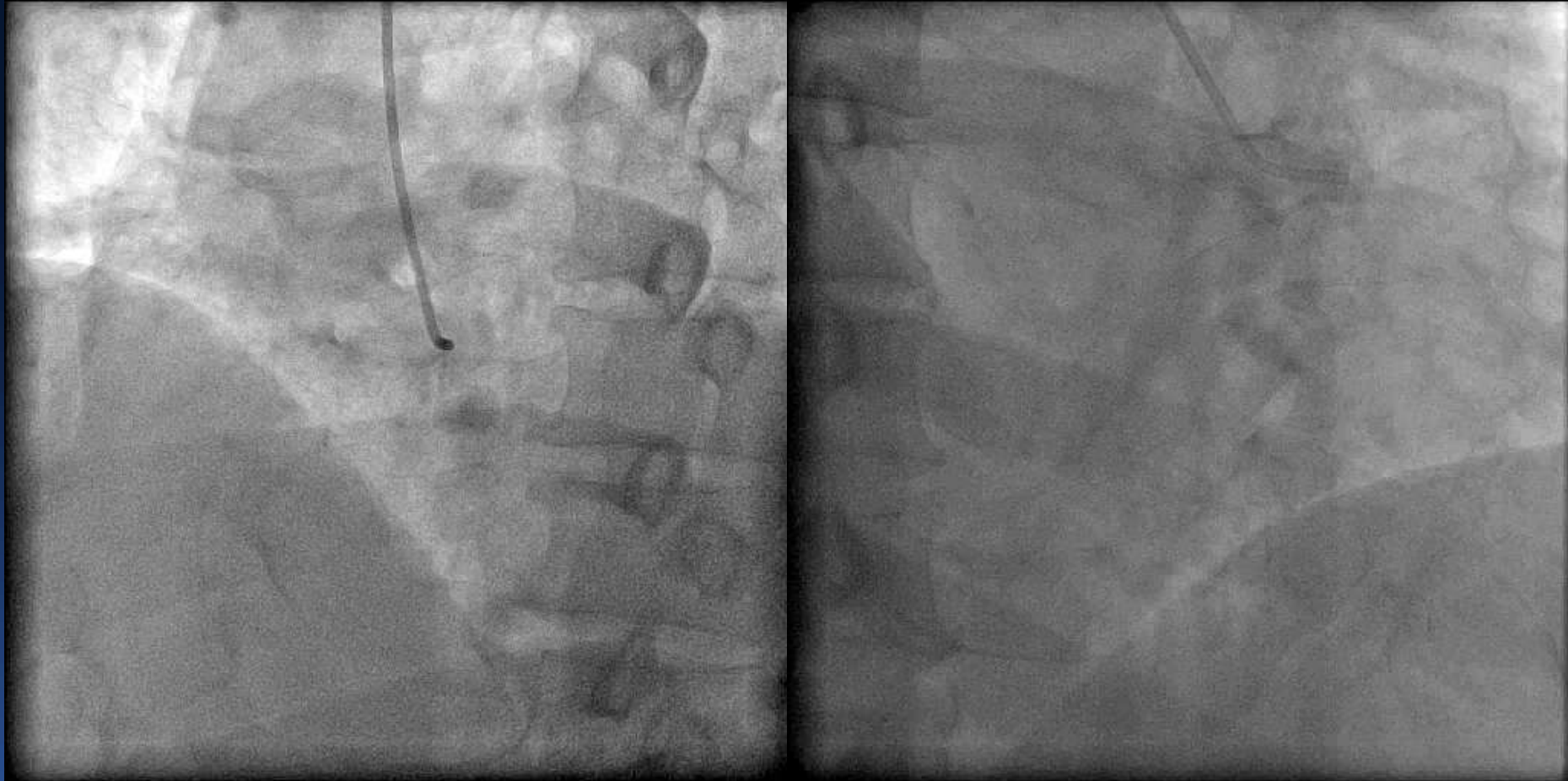Case Study

- 64 year-old man, presented with dyspnoea on exertion.
- Diabetes mellitus, overweight, high cholesterol
- CT coronary angiogram showed significant blockage of mid LAD with moderate calcification.
- Anomalous origin of RCA from left aortic sinus. Significant blockage at proximal and distal segment

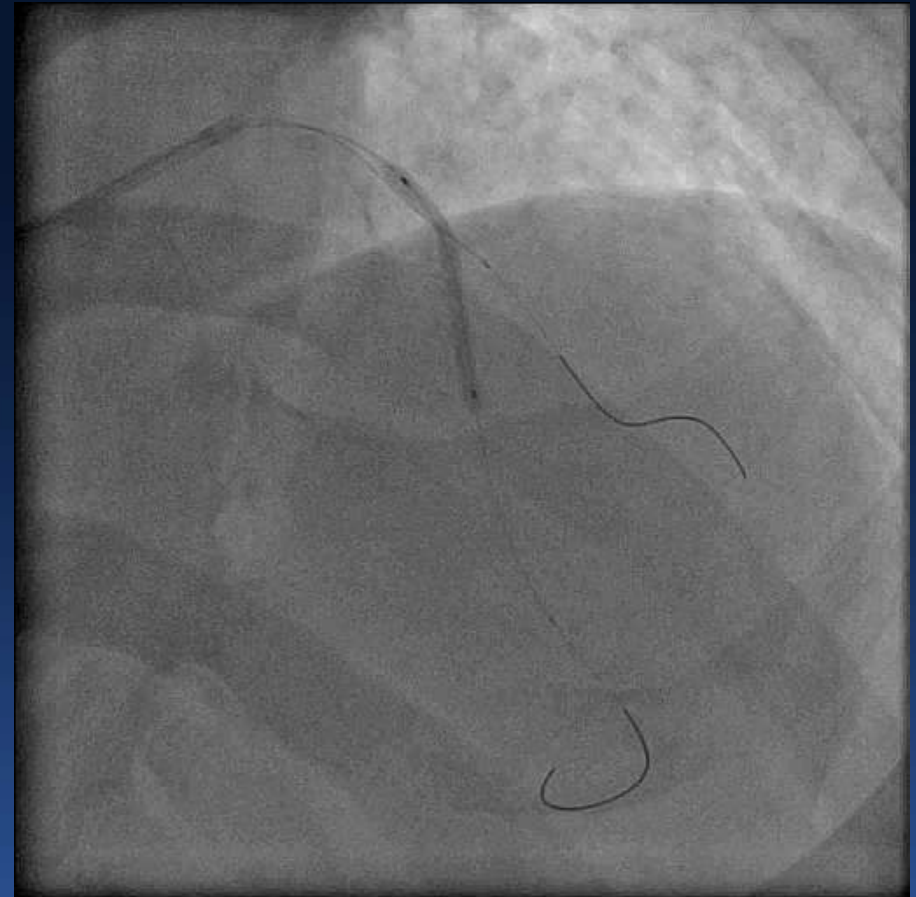
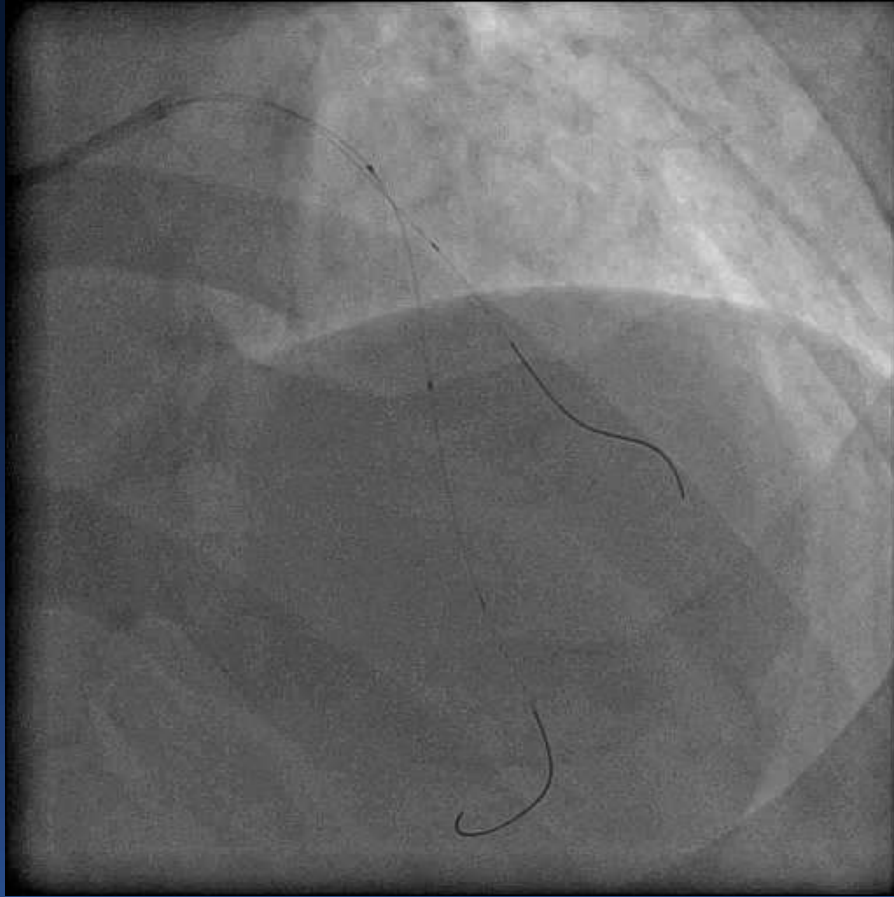
Bifurcation lesion at LAD/D1



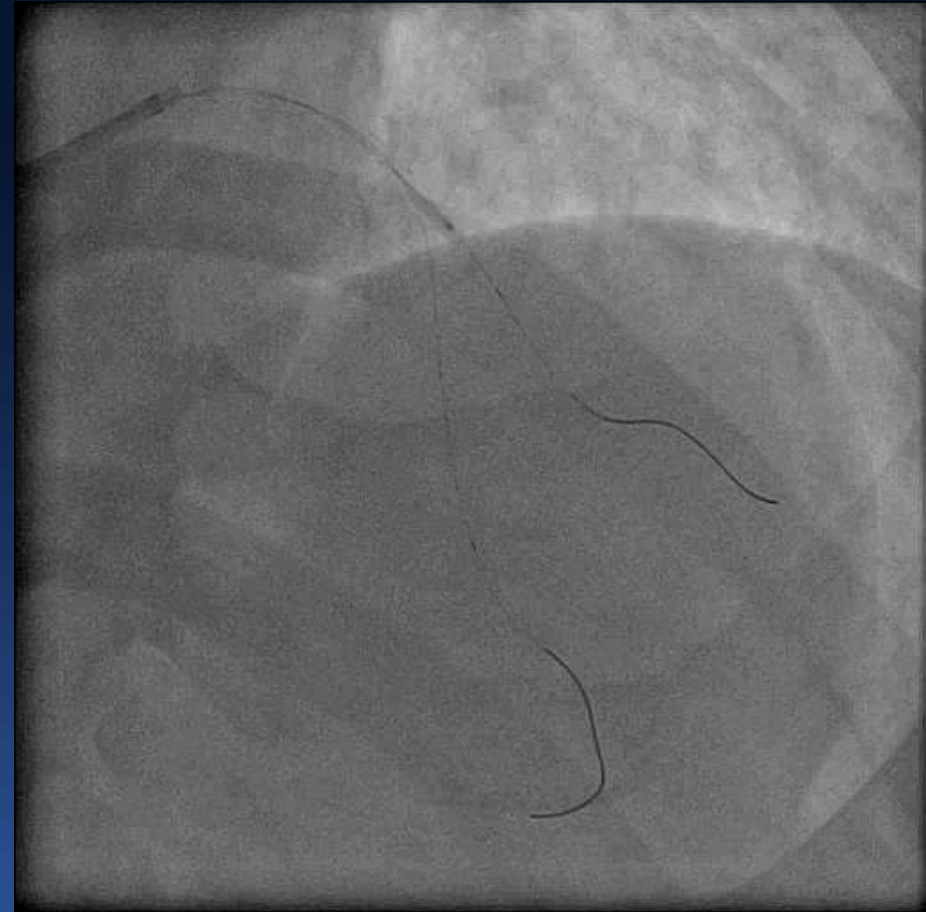
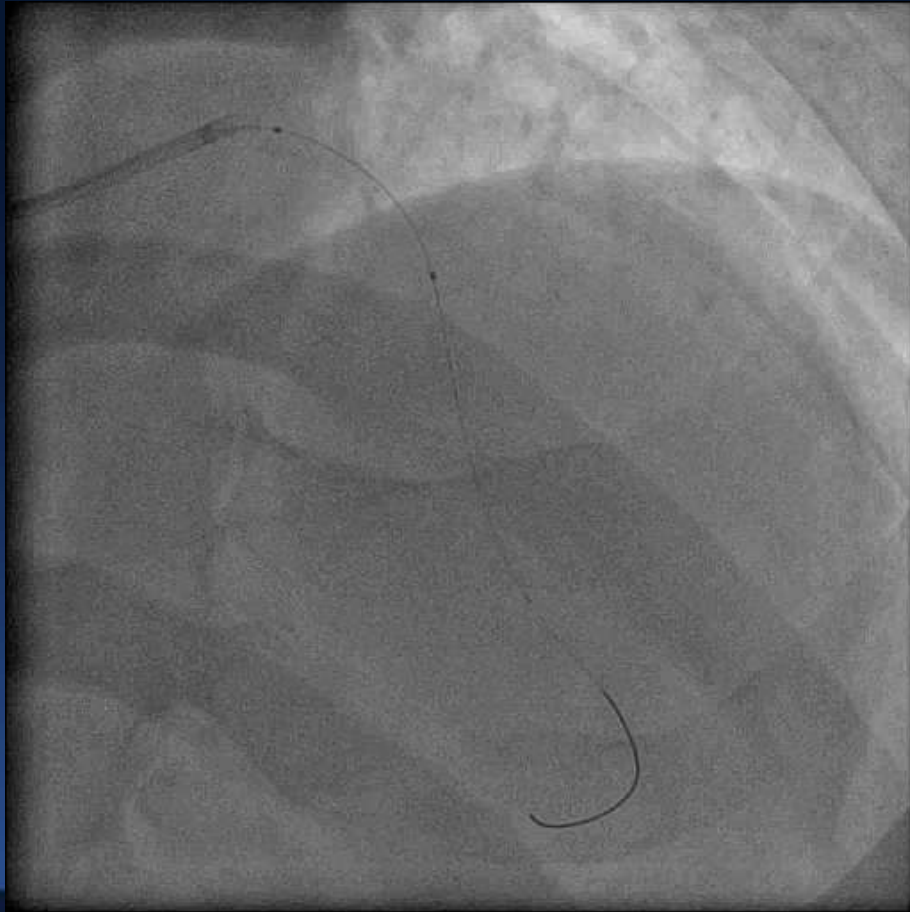
Anomalous origin of RCA with proximal and distal lesions



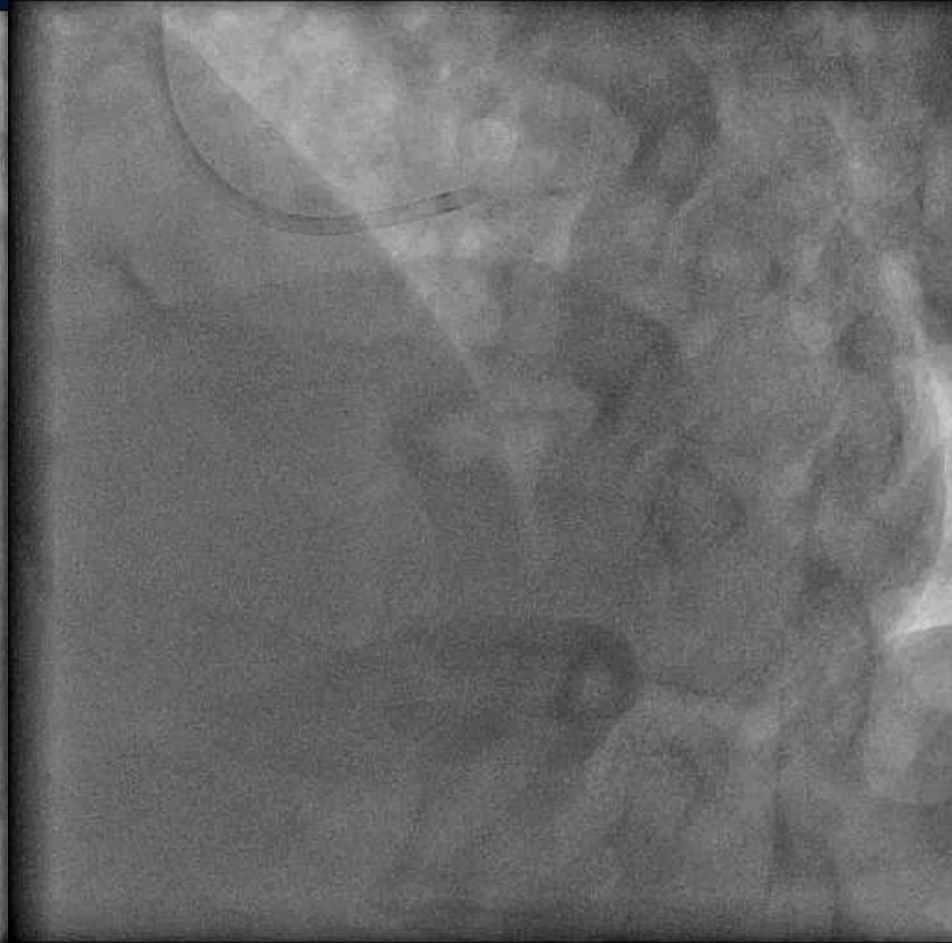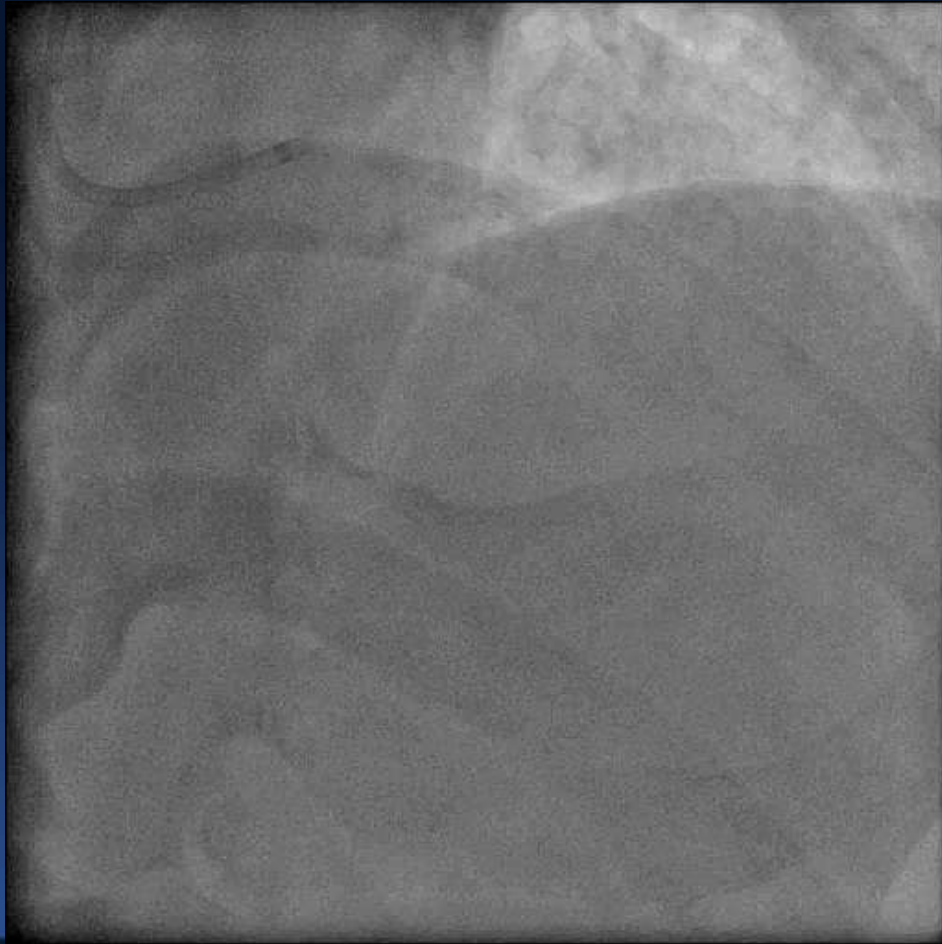Predilation with 2.5mm balloon 2.5x28mm Absorb BVS was deployed



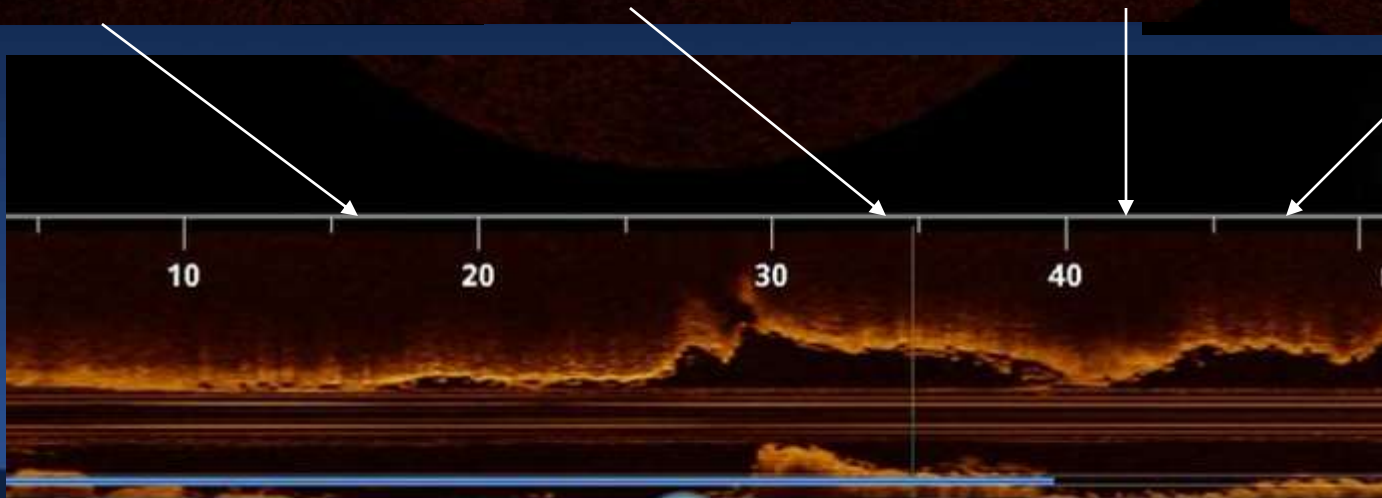
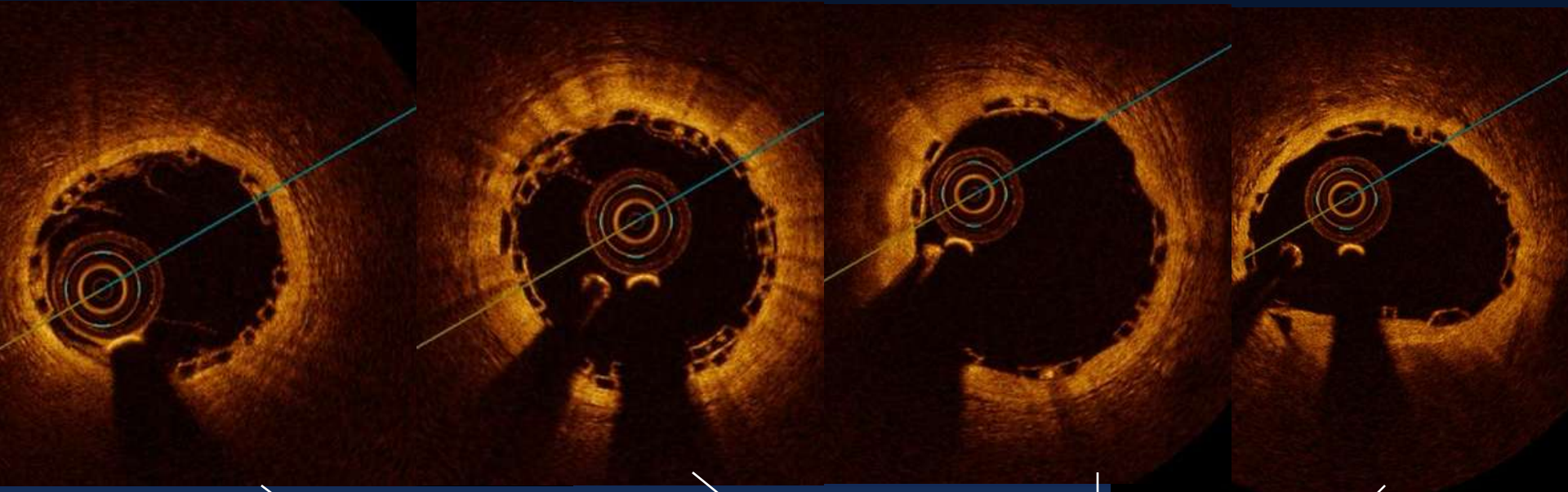
**3.0x28mm Absorb BVS deployed at proximal LAD
POBA D2 with 2.0mm balloon
BVS further expanded with 3.5/3.25/3.0/2.75mm NC
balloons with OCT guide**



Final angiogram



OCT images of LAD (post-BVS)



6Fr AL.75 guiding catheter

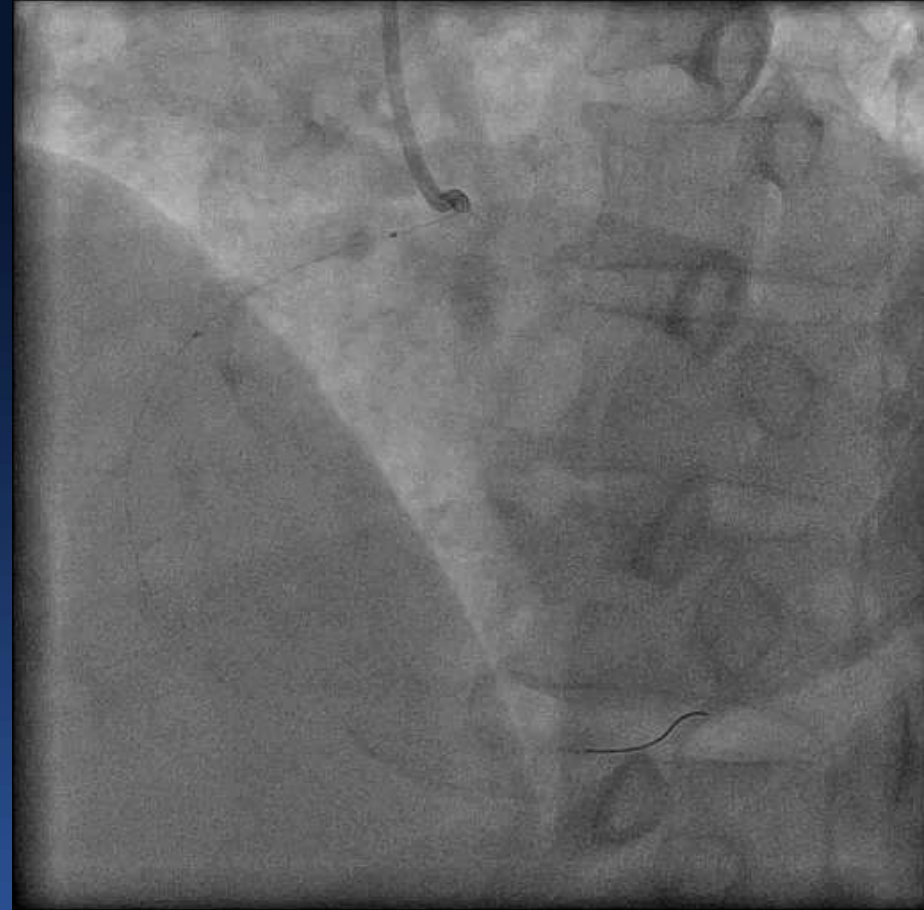
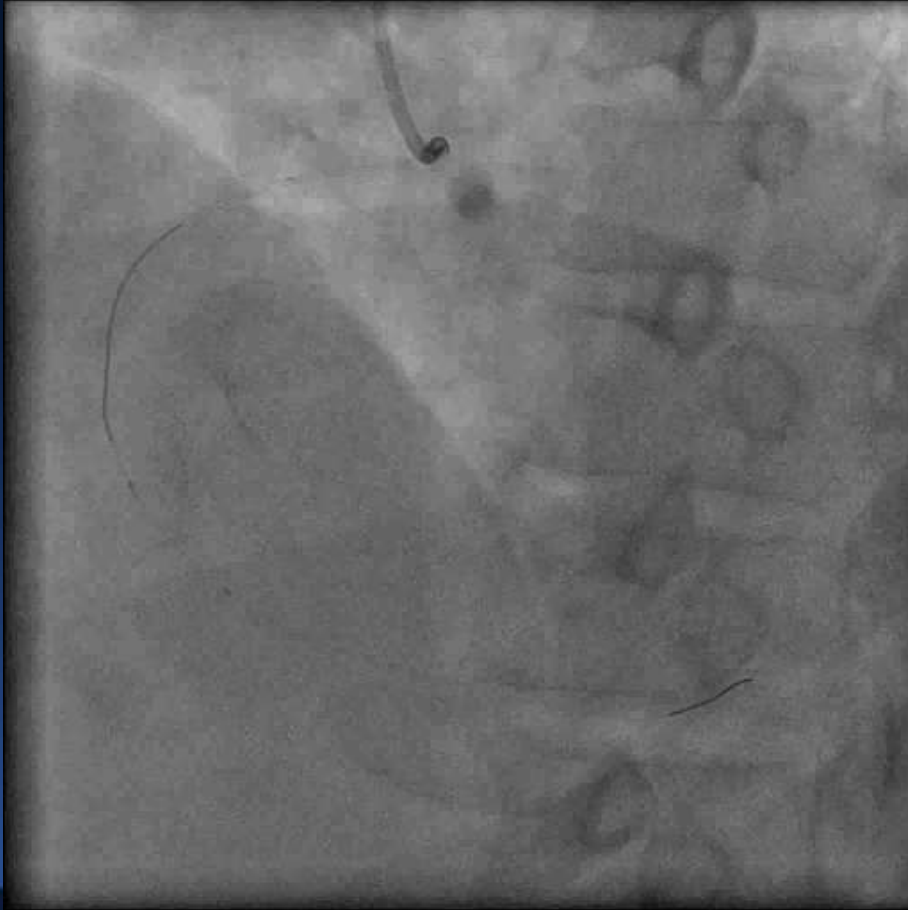0.014" BMW and Runthrough wires

Predilated with 2.5mm balloon

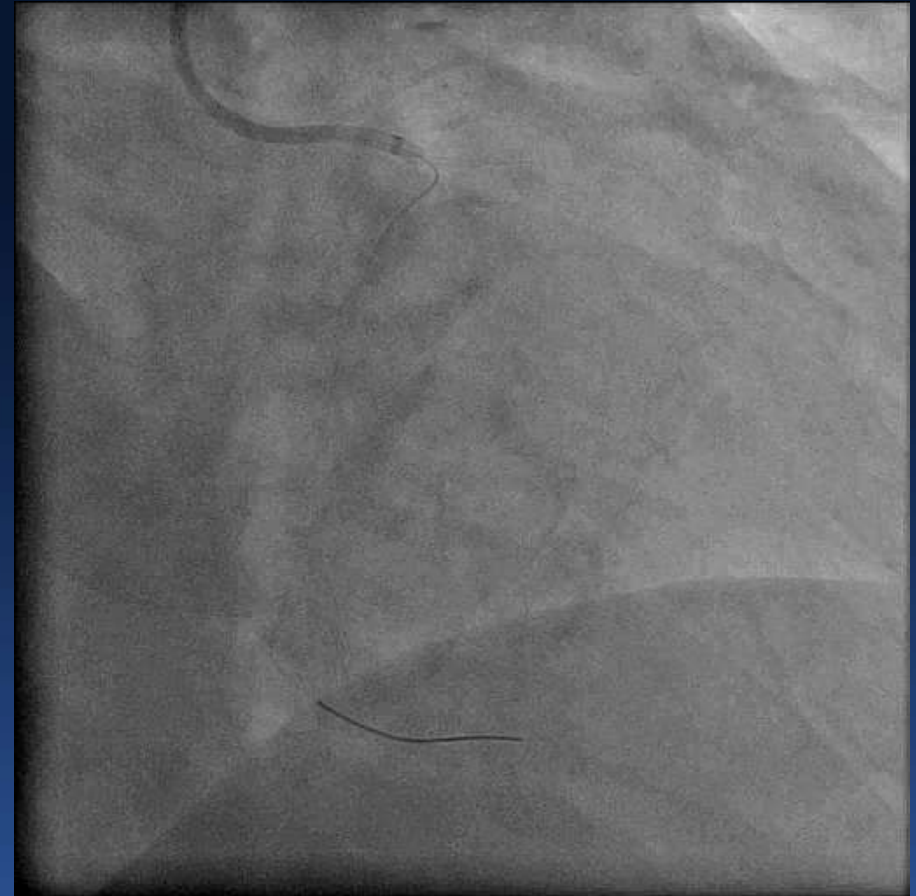
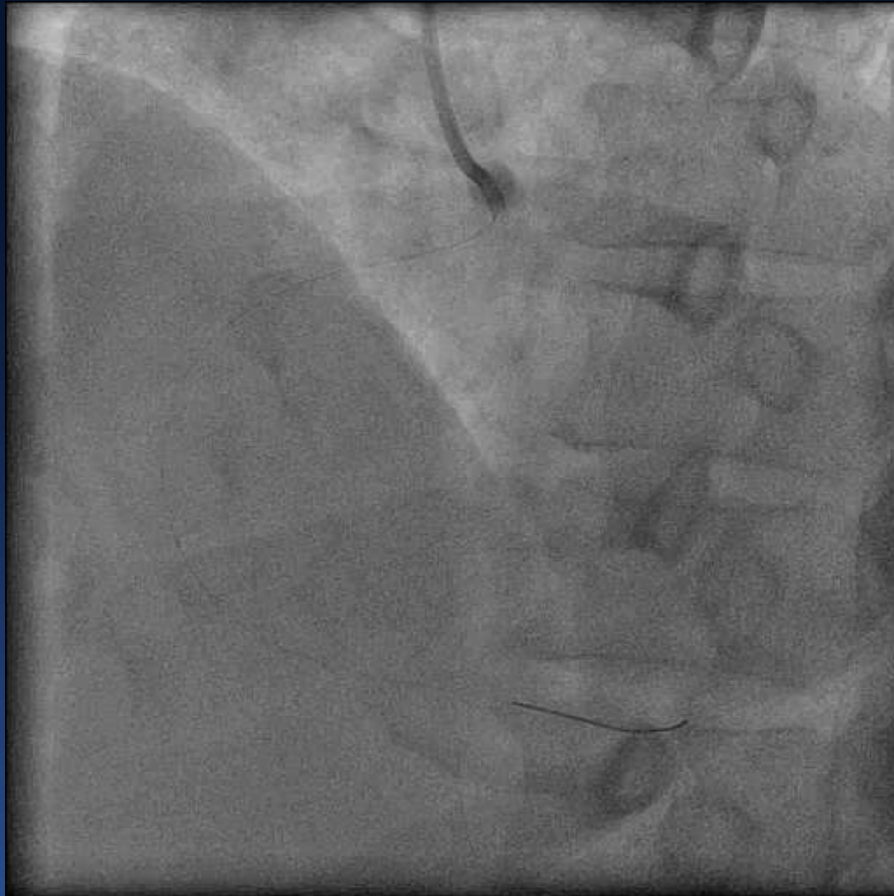2.5x18mm BVS deployed distally

2.5x28mm BVS deployed proximally

BVS were further expanded with 3.0mm NC balloons with IVUS guide



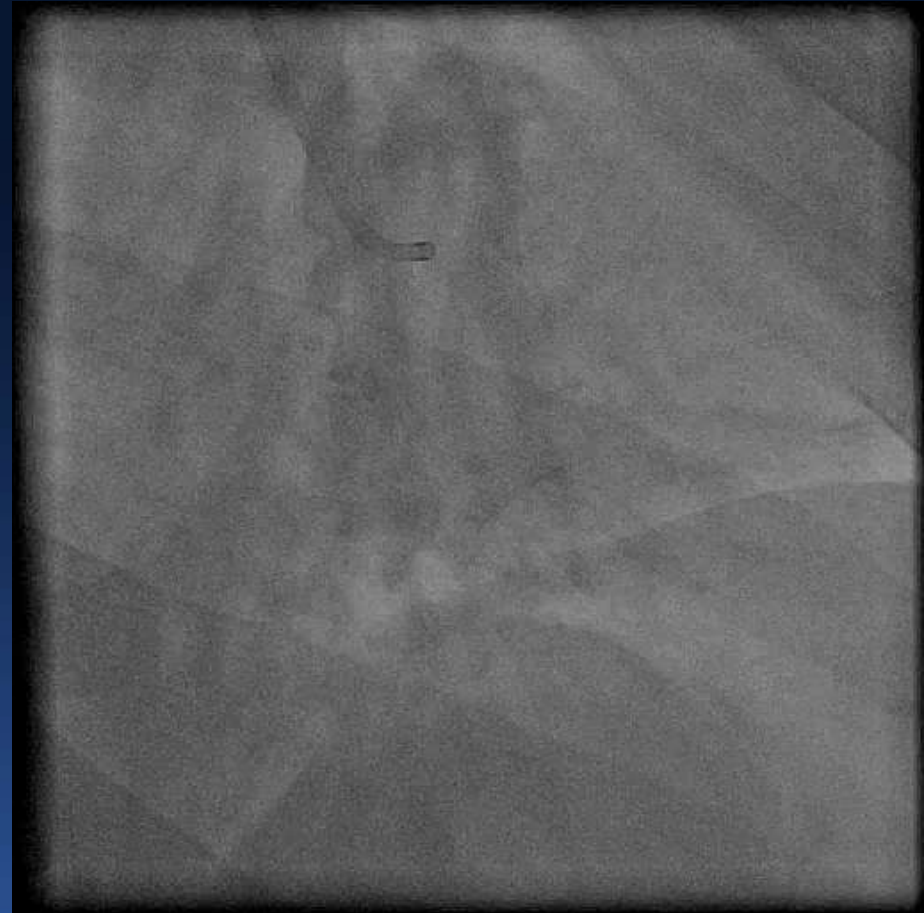
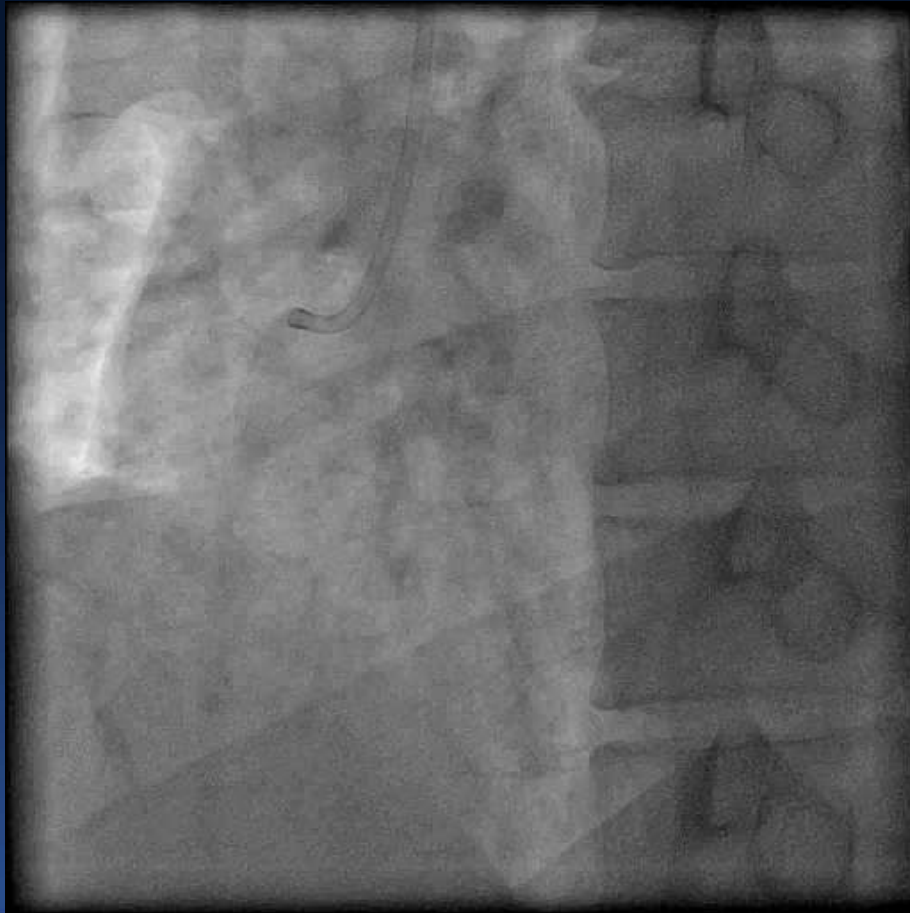Final Angiogram



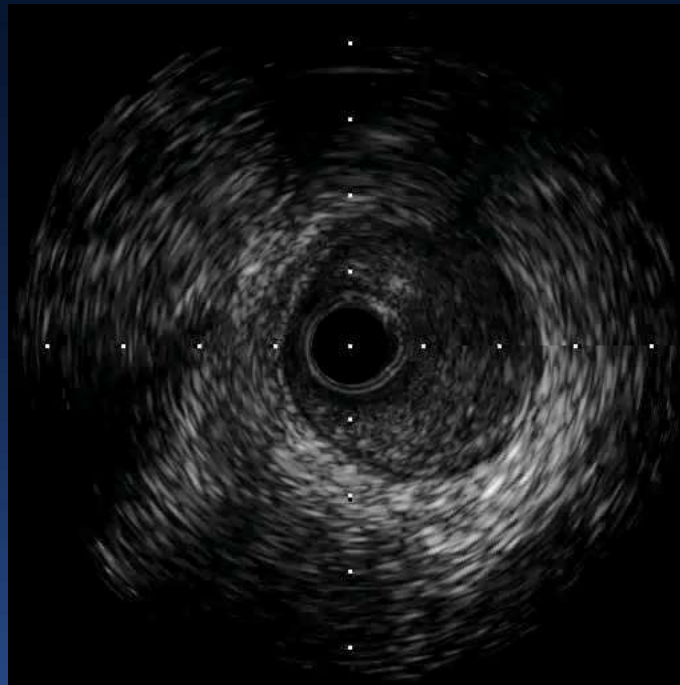
Case Study

- 36 year-old man, suffered from acute inferior myocardial infarction (STEMI) in China.
- He was treated with thrombolytic in a local hospital.
- He was then transferred to Nanjing Hospital for cardiac catheterization, which confirmed critical stenoses at proximal RCA and also left circumflex artery.
- The patient refused DES implant. Only simple balloon angioplasty was performed at the proximal RCA.
- He then came to Hong Kong for treatment

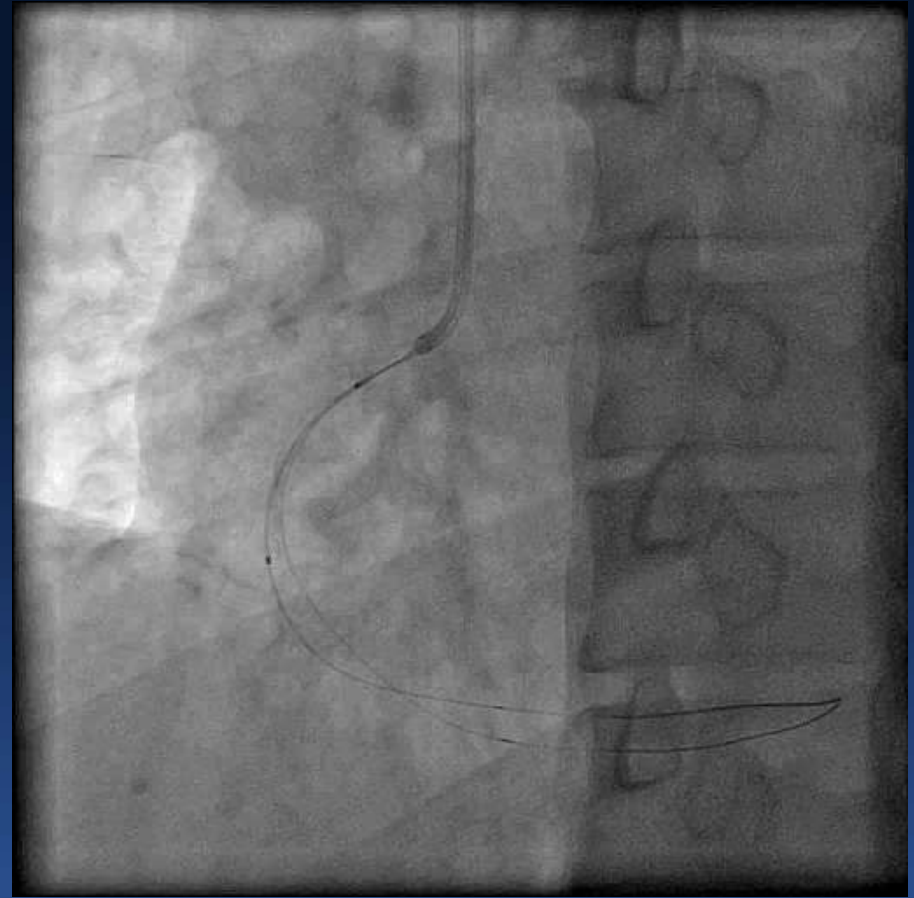
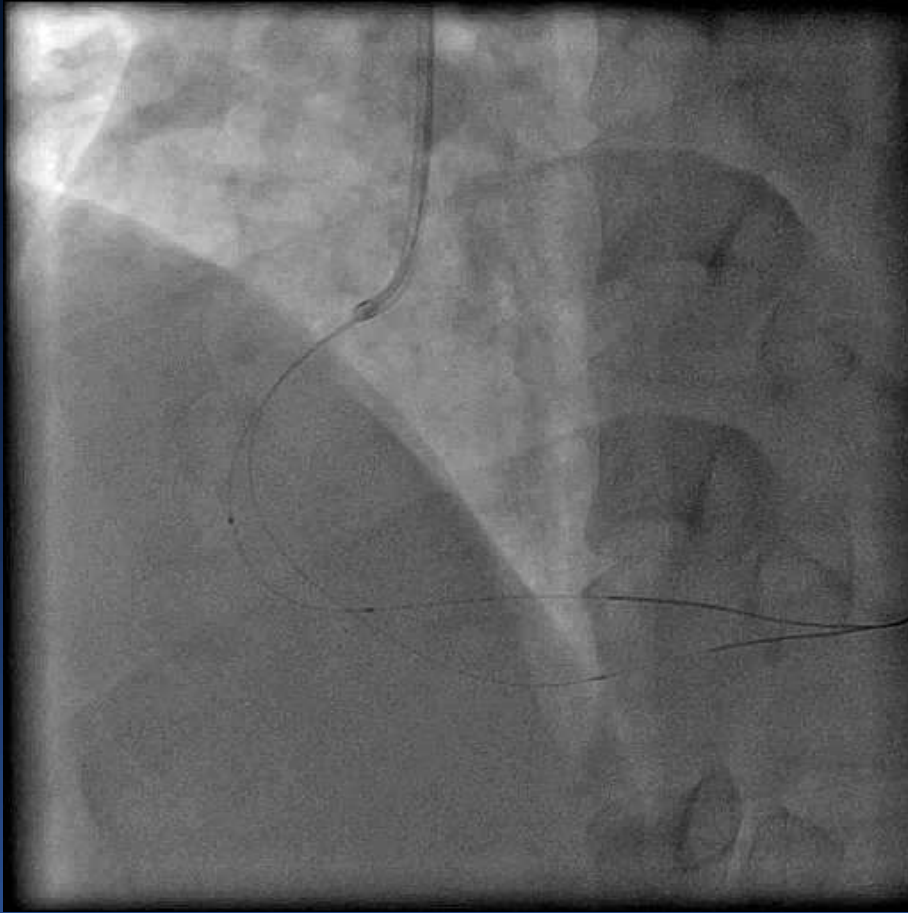
Coronary angiogram



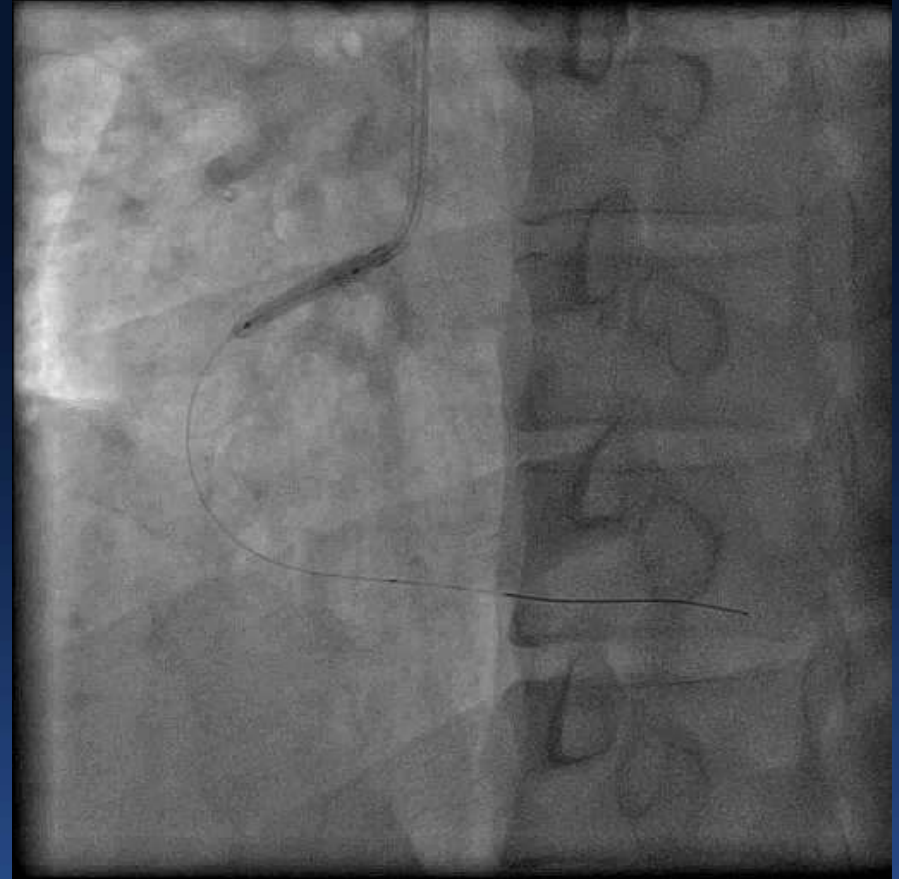
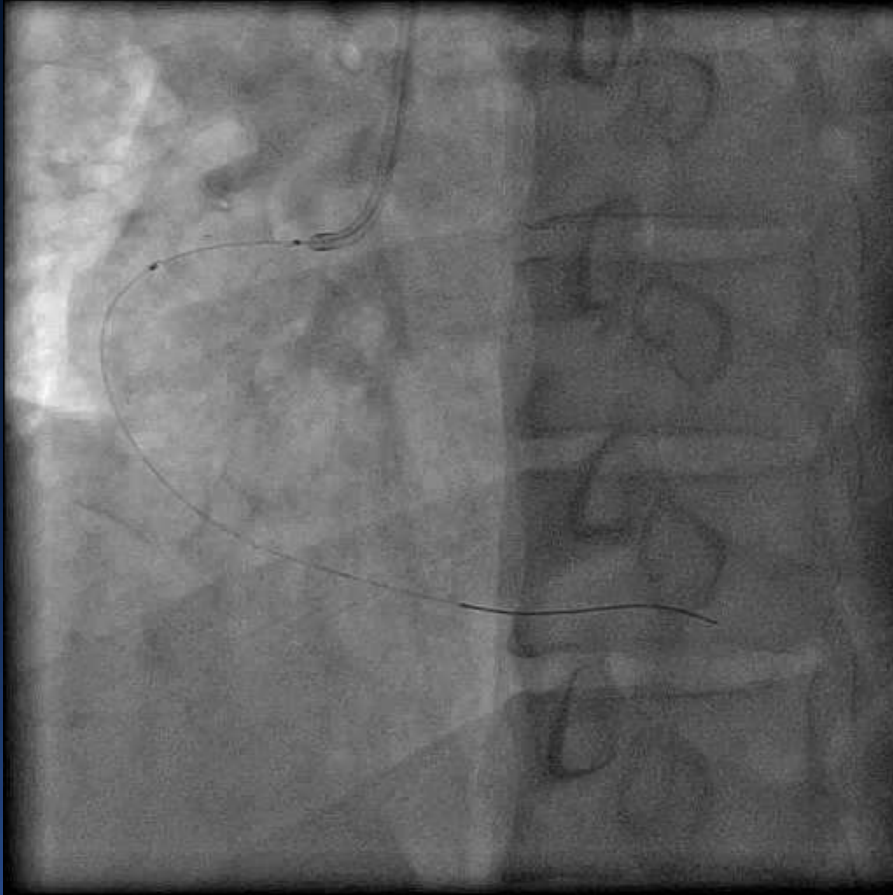
IVUS of RCA showed diffuse disease and ruptured plaque proximally



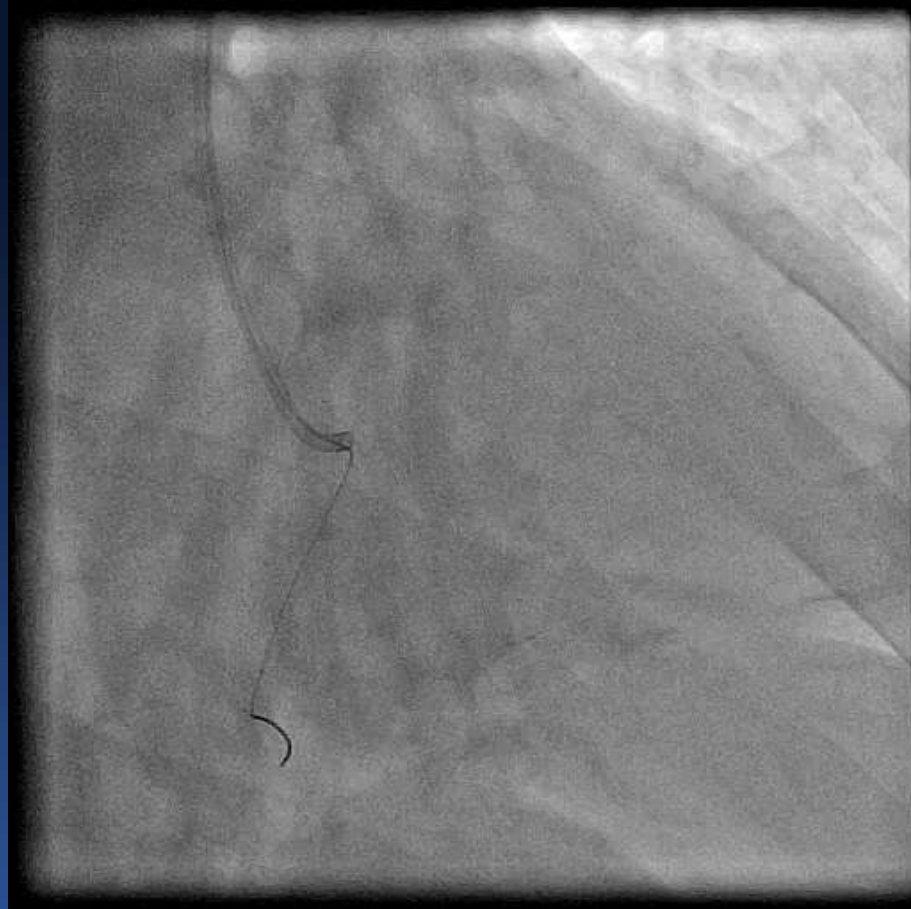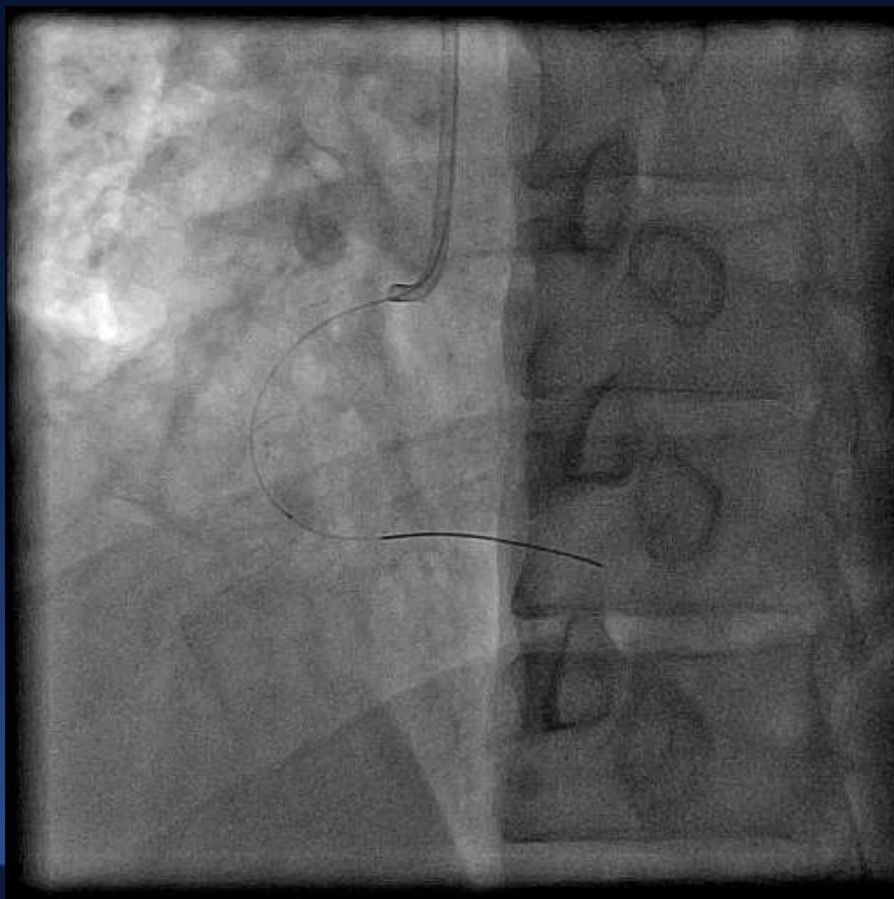
**Predilation with 2.75 mm NC balloon
2.5x28mm BVS was implanted distally
3.0x28mm BVS was implanted at mid RCA**



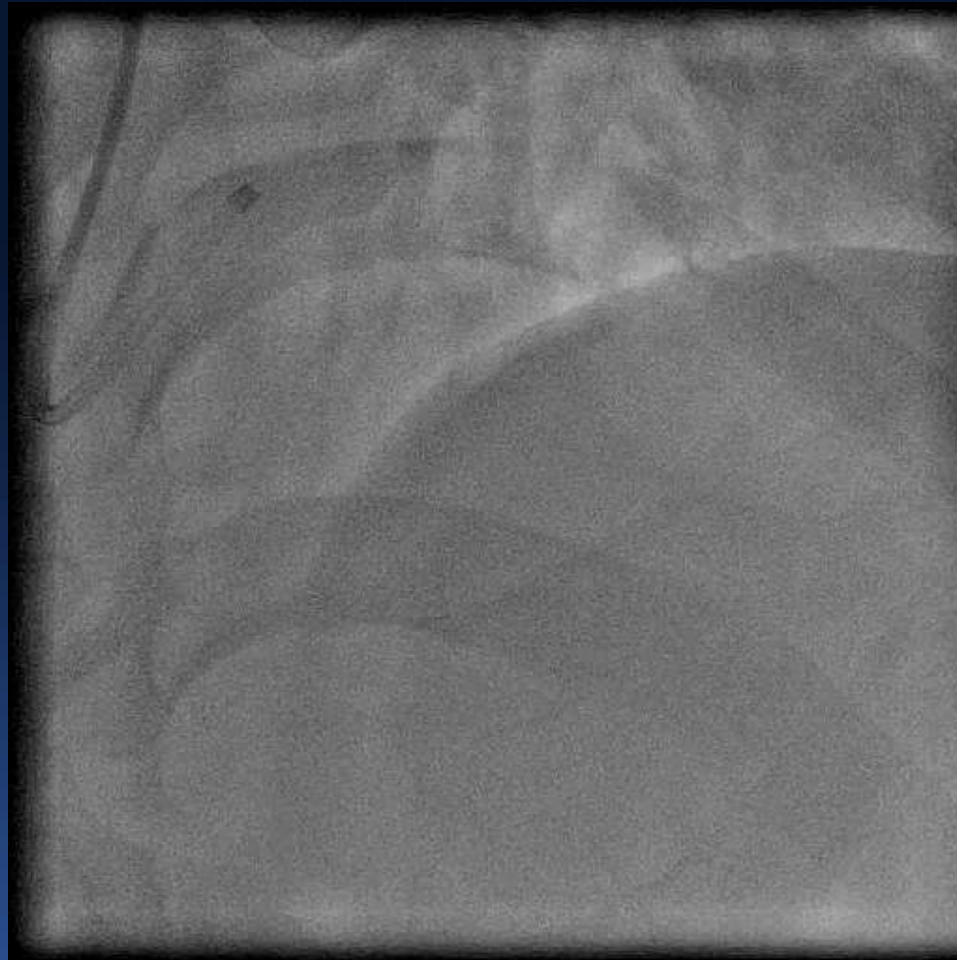3.0x18mm BVS was deployed at proximal RCA



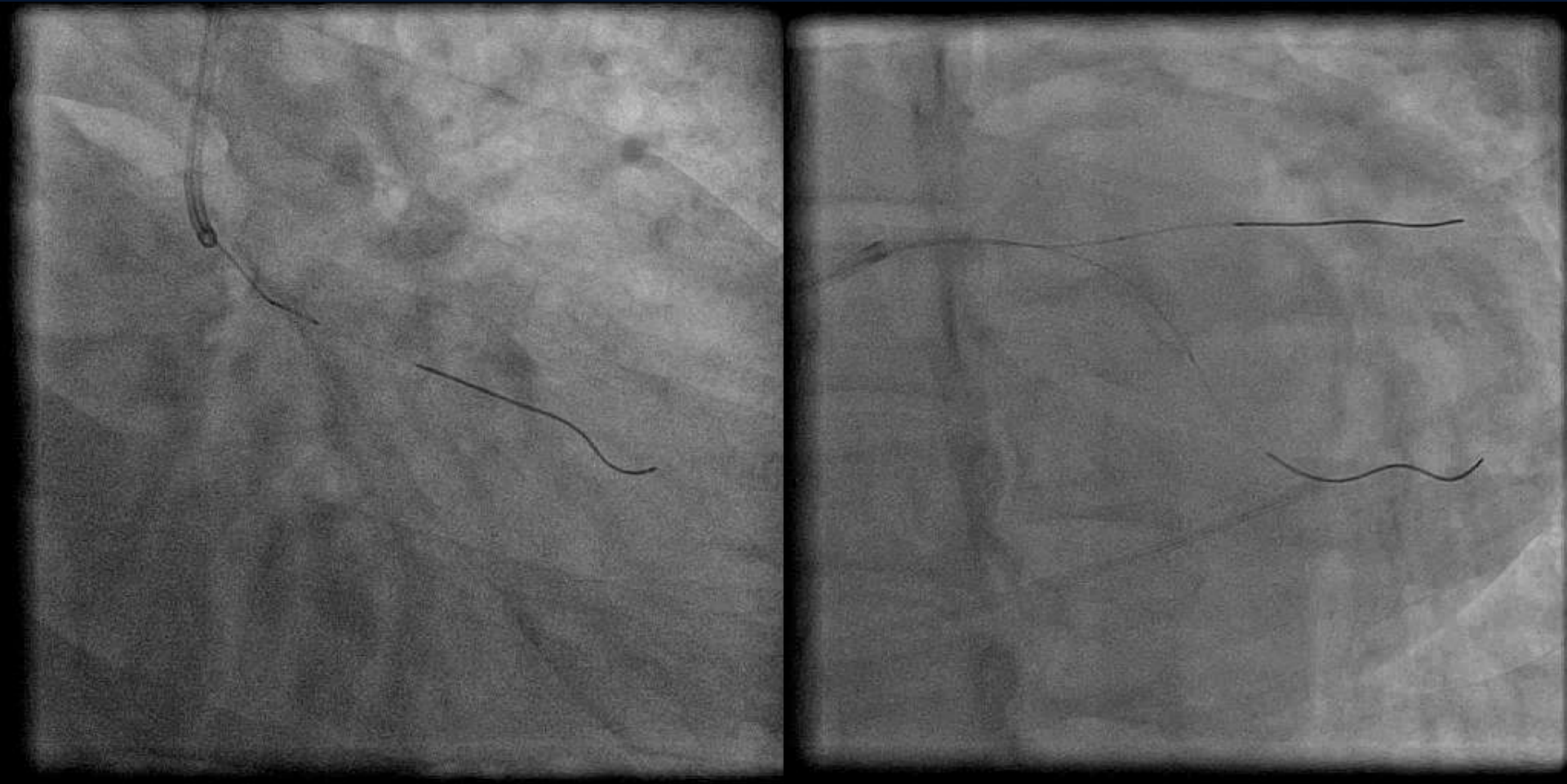
**Post-dilated with 3.0 & 3.5mm NC balloons with IVUS
guide
POBA acute marginal with 2.0mm balloon after re-
wiring**



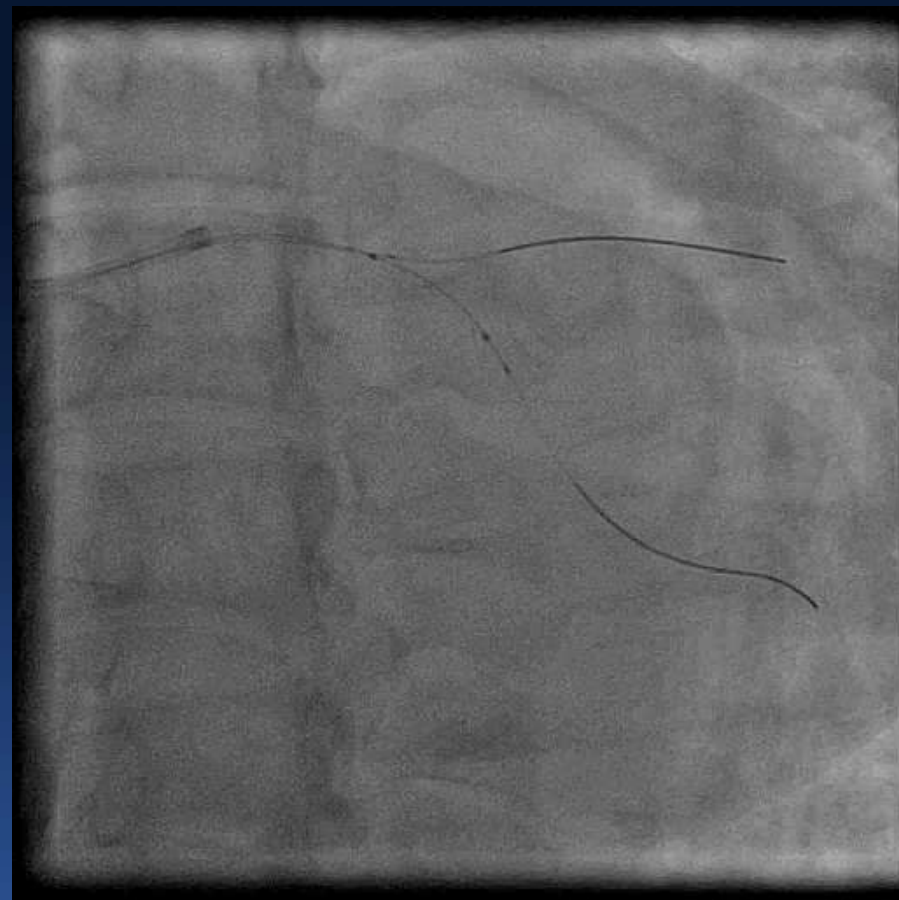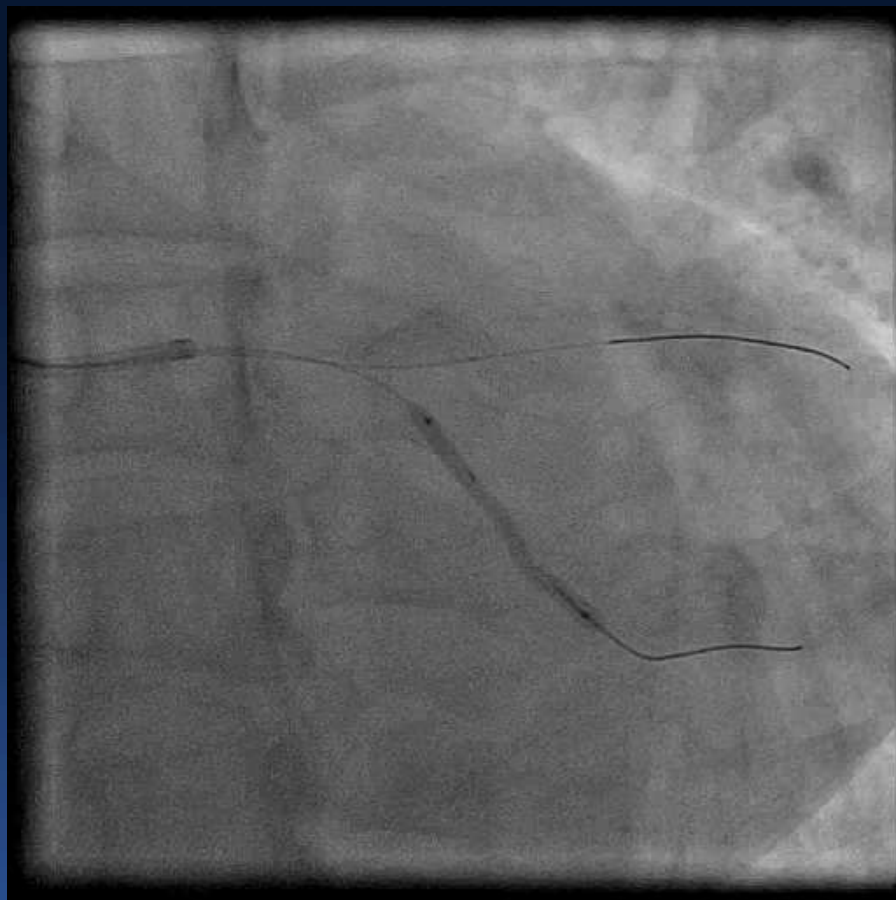
LAD: Minor disease



LCx Coronary Angiogram



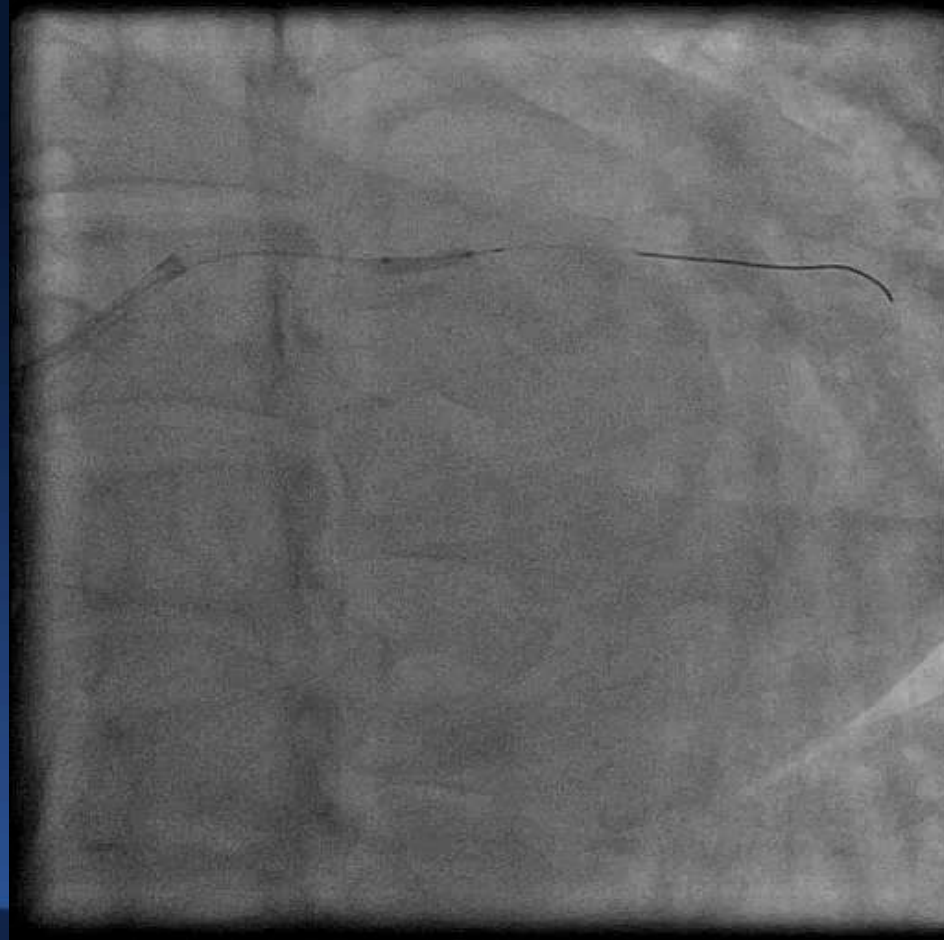
**Predilated with 2.5mm balloon
2.5x28mm BVS implanted at distal LCX-last OM
2.5x18mm BVS deployed at mid LCx**



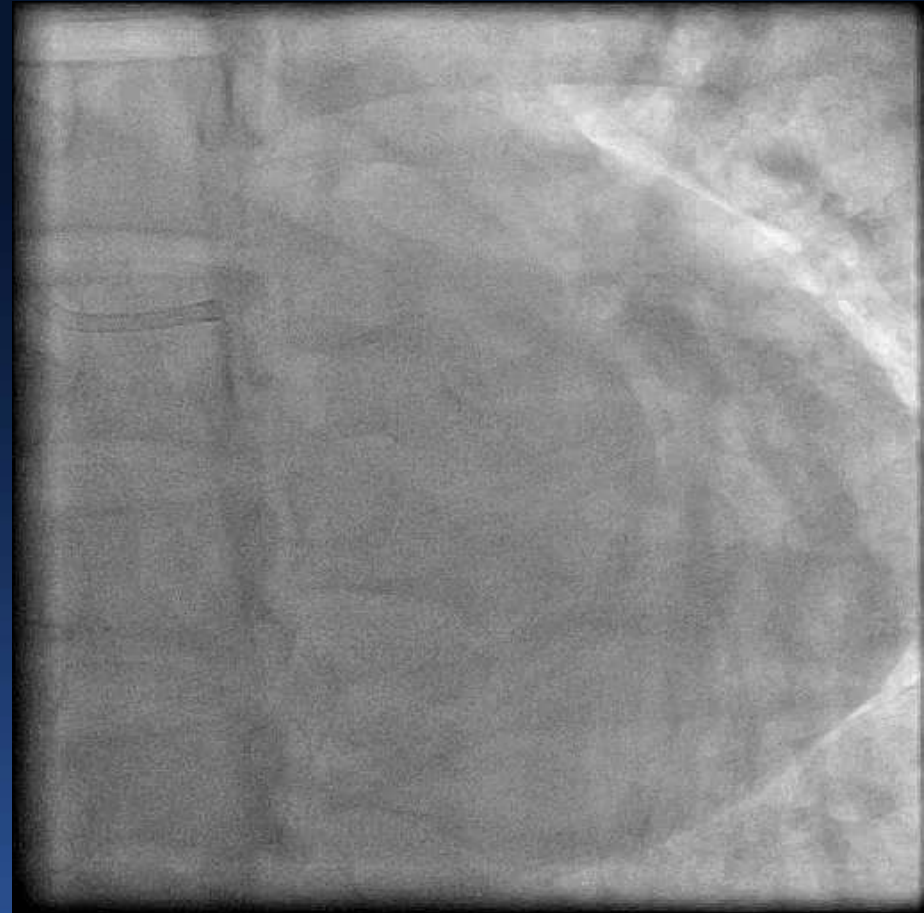
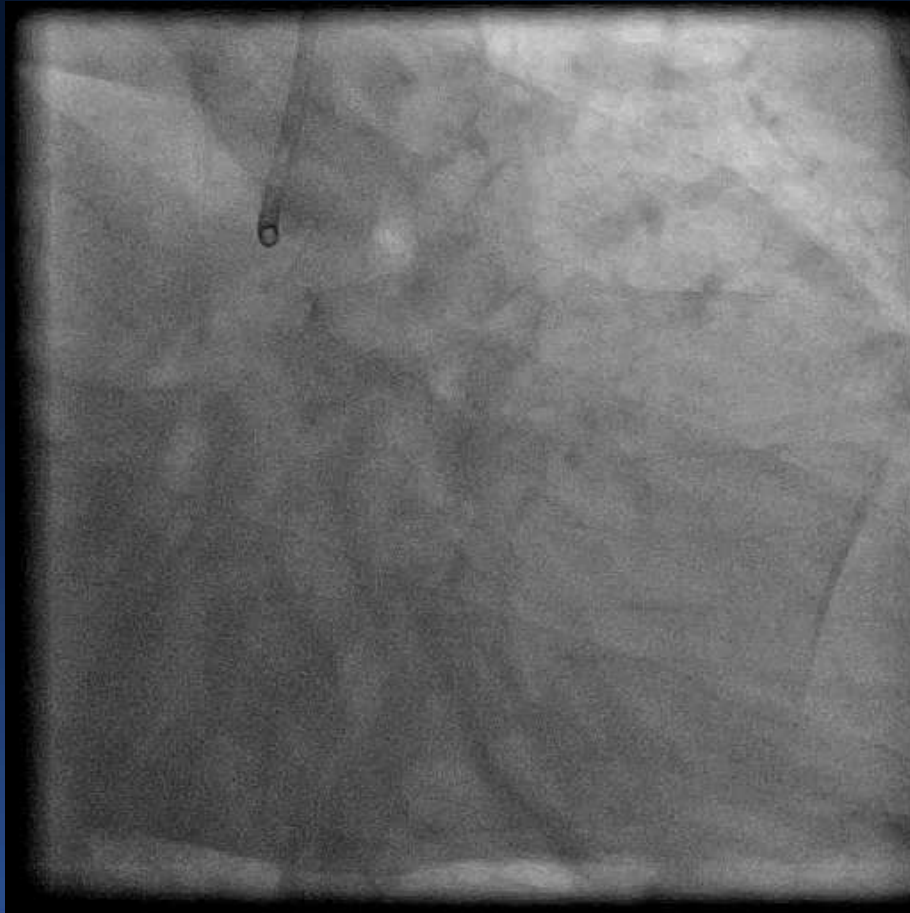
**The BVS were further post-dilated with 2.5 & 2.75mm
NC balloons**

OM1 was re-wired

POBA OM1 with 2.0mm balloon



Final angiogram



Case #2

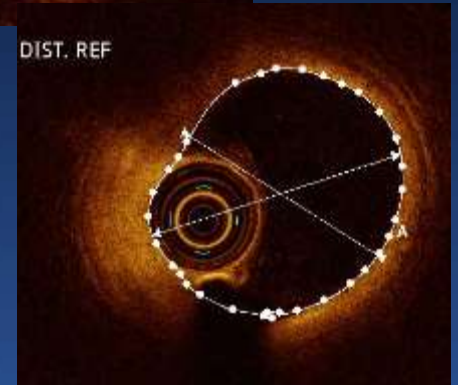
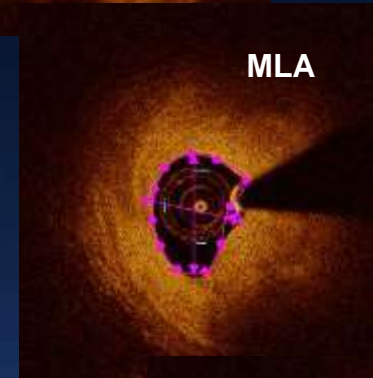
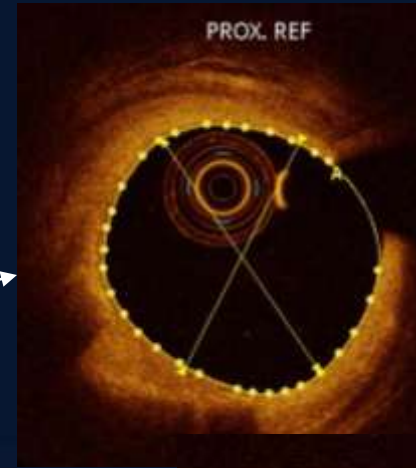
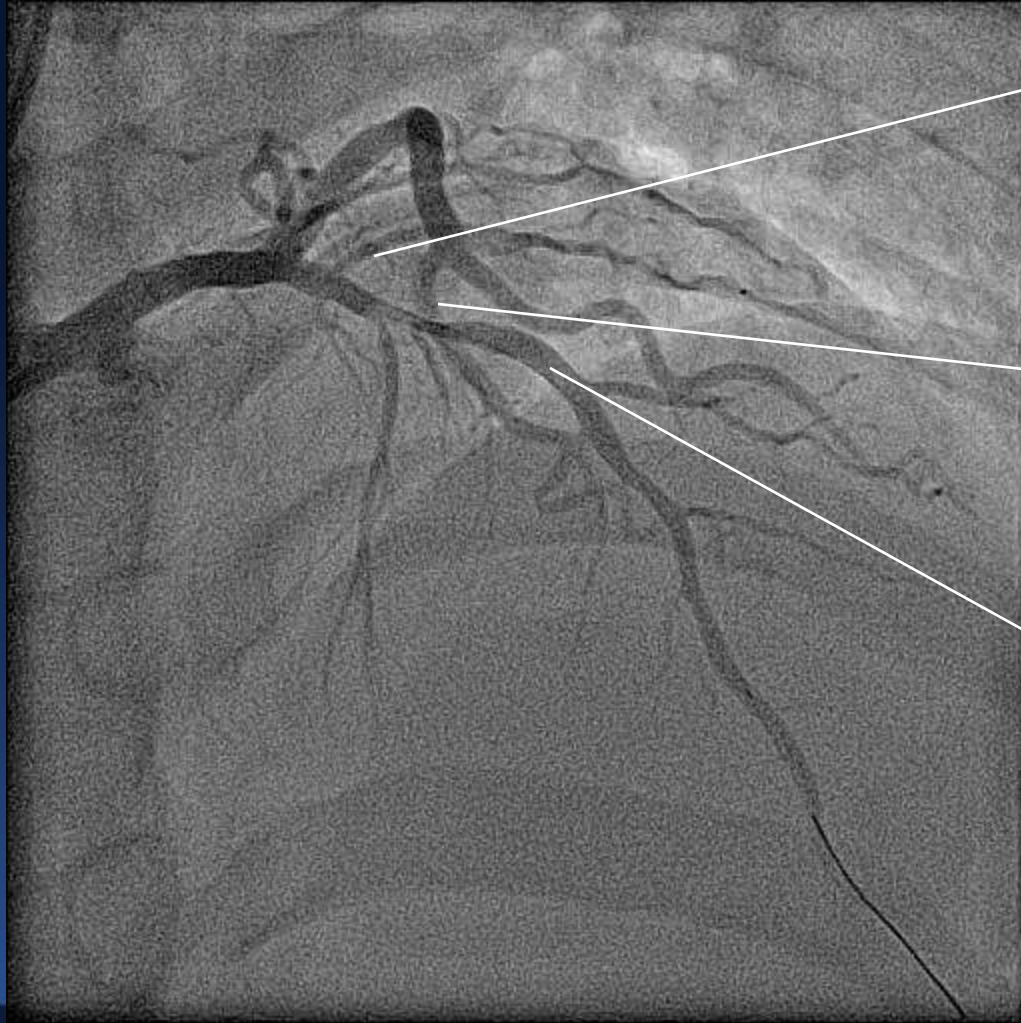
M/36

Philippine origin

**Hypertension, high cholesterol, overweight
c/o angina on exertion**

CTA: 80% proximal LAD stenosis

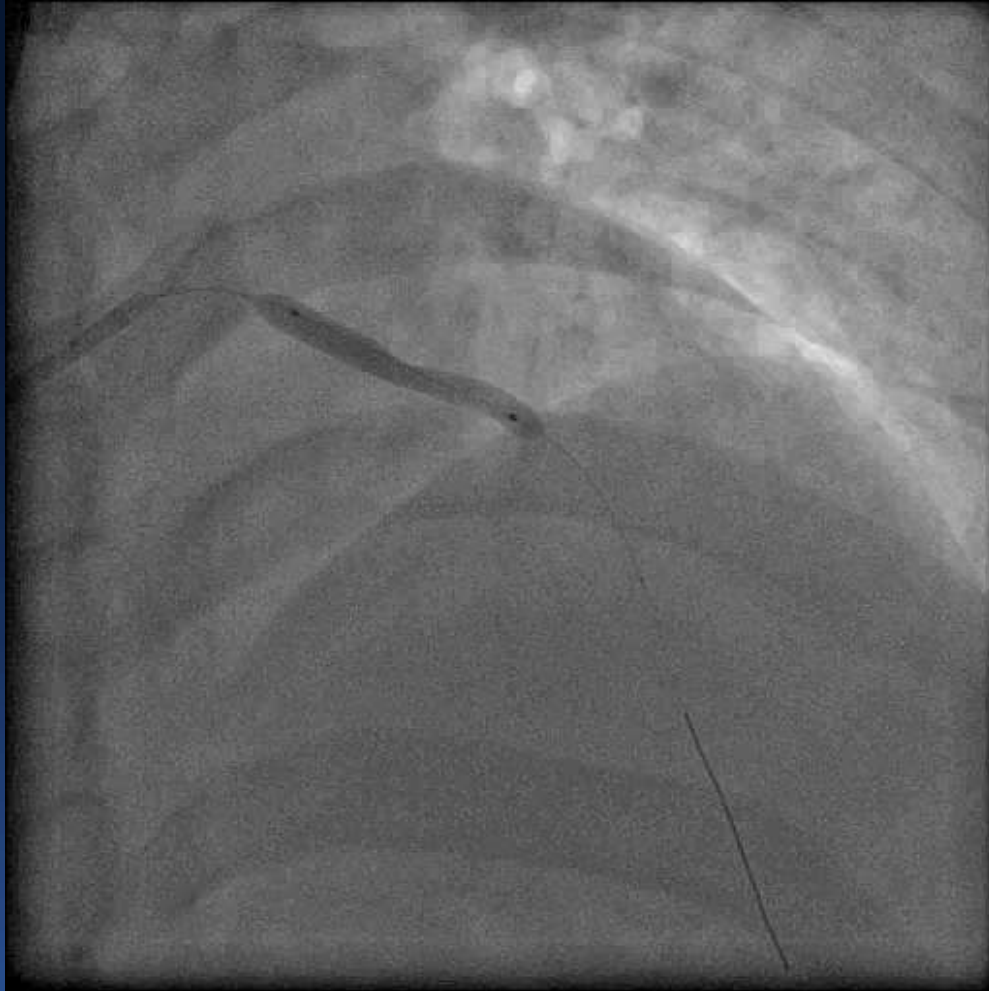
LAD angiogram



How to treat?

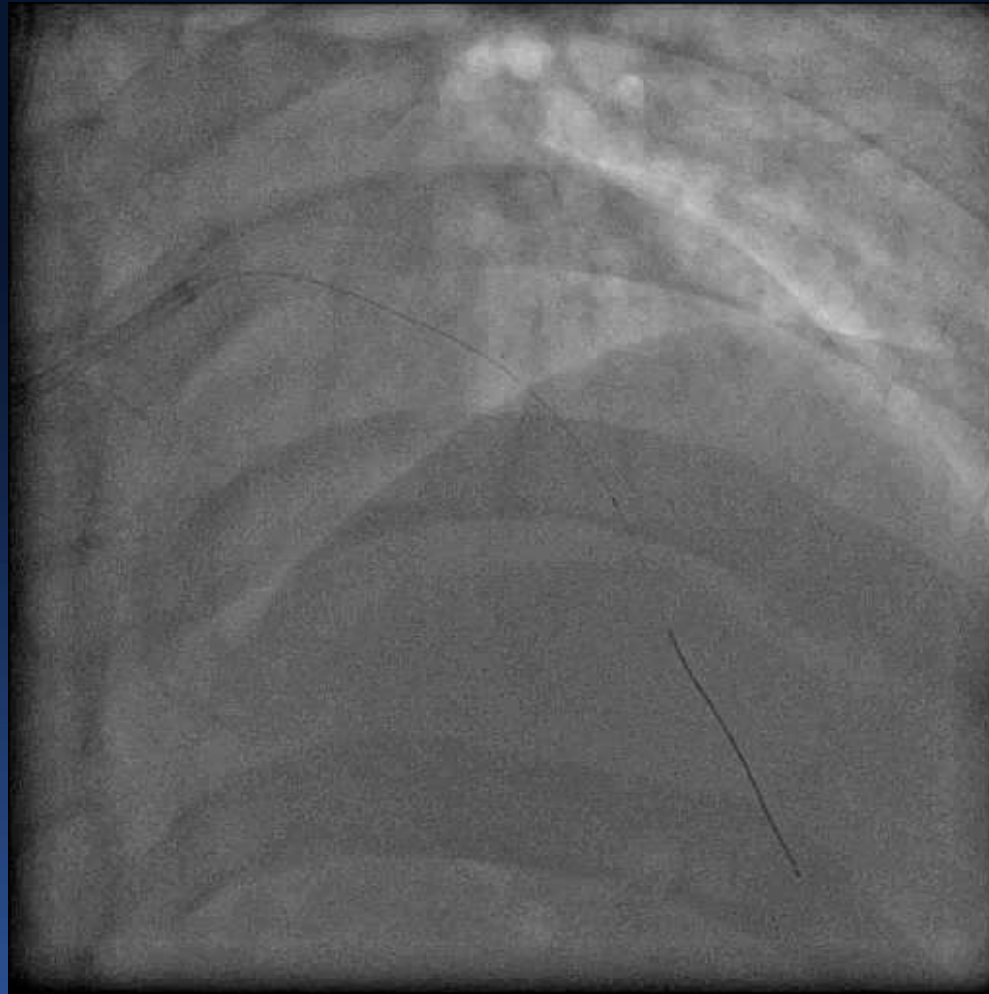
- **DES or BVS**
- **Predilation or Direct stenting?**
- **Cutting balloon?**
- **IVUS or OCT?**

3.5x28mm BVS at 14 ATM

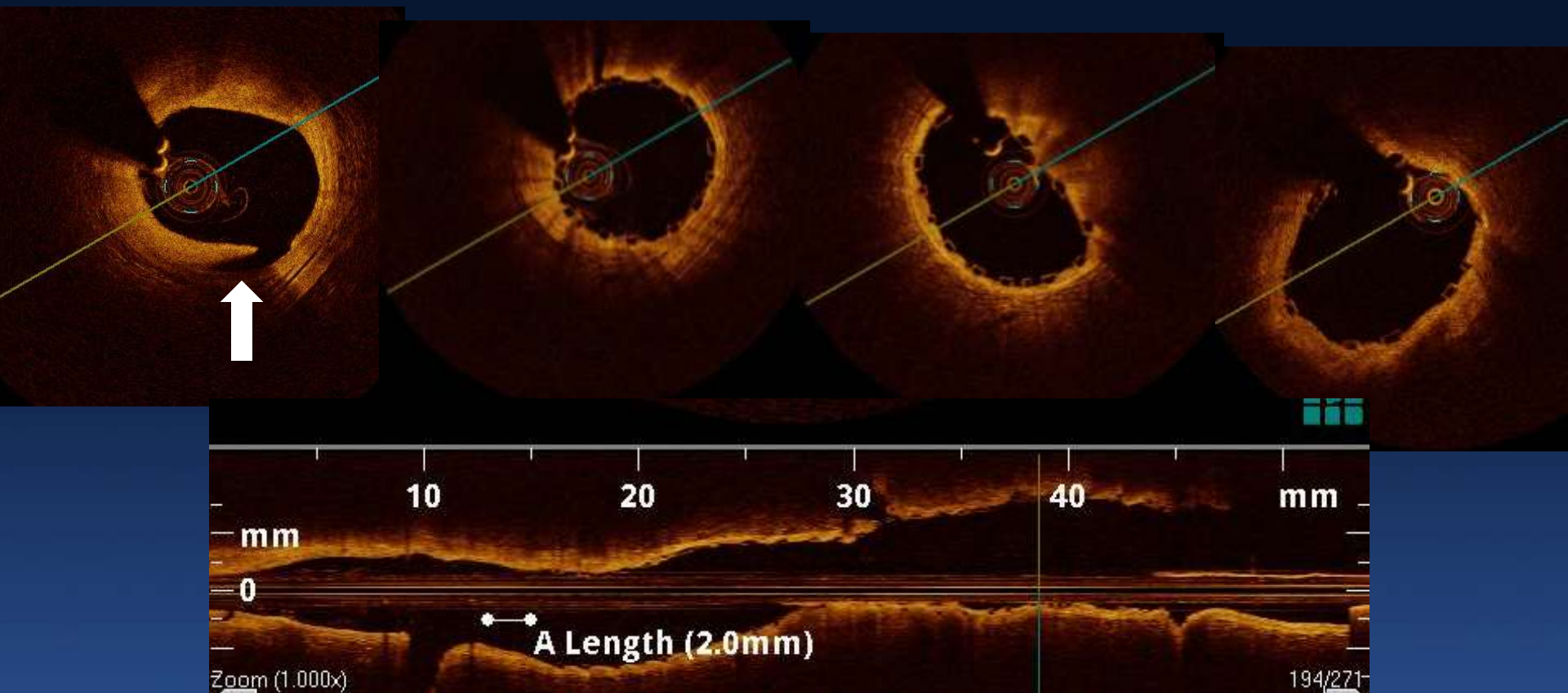


ATM	kPa	↔
6 (NOM)	608	3.50 mm
7	709	3.59 mm
8	811	3.66 mm
9	912	3.73 mm
10	1013	3.78 mm
11	1115	3.83 mm
12	1216	3.87 mm
13	1317	3.91 mm
14	1419	3.94 mm
15	1520	3.98 mm
16 (RBP)	1621	4.01 mm

Need more post-dilation



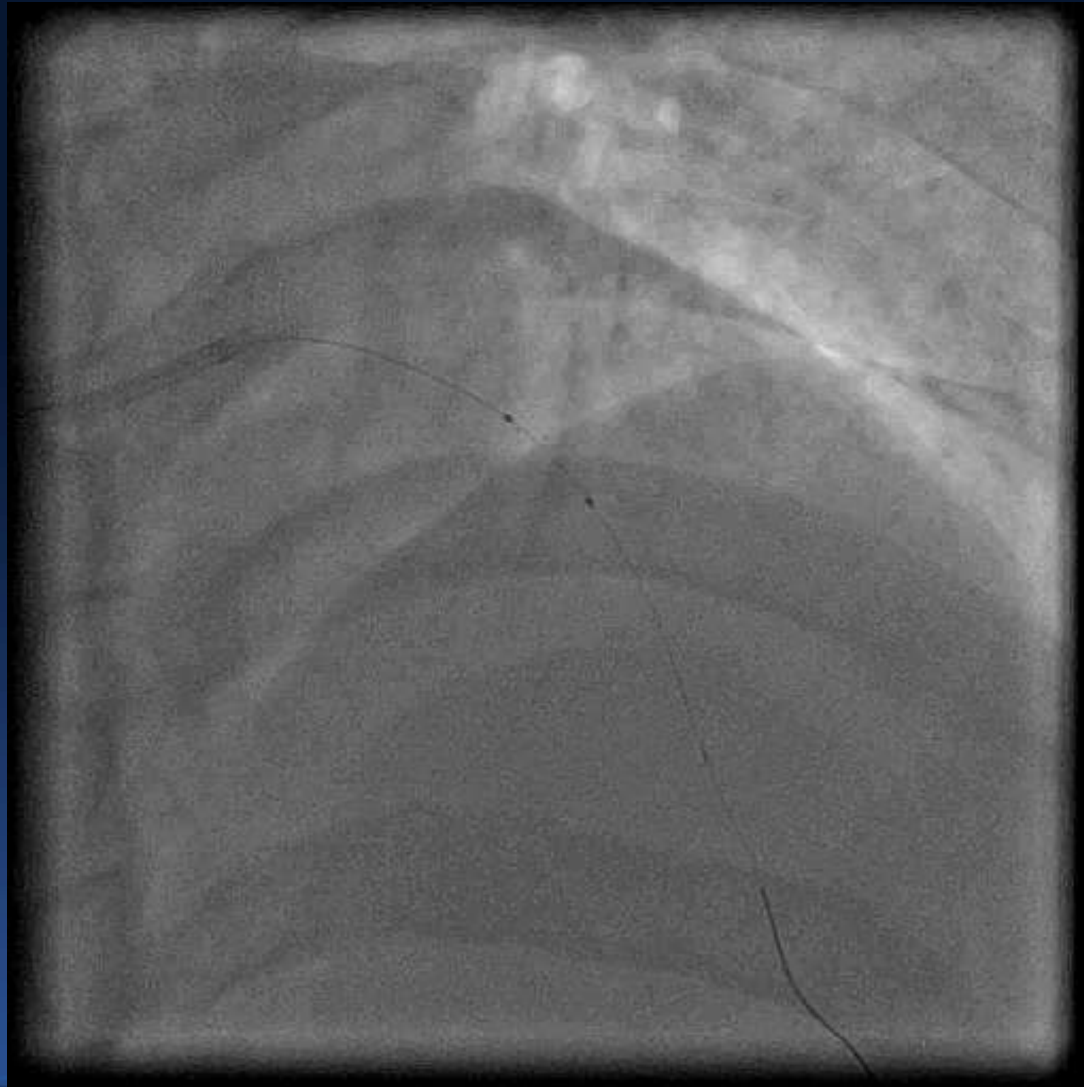
OCT



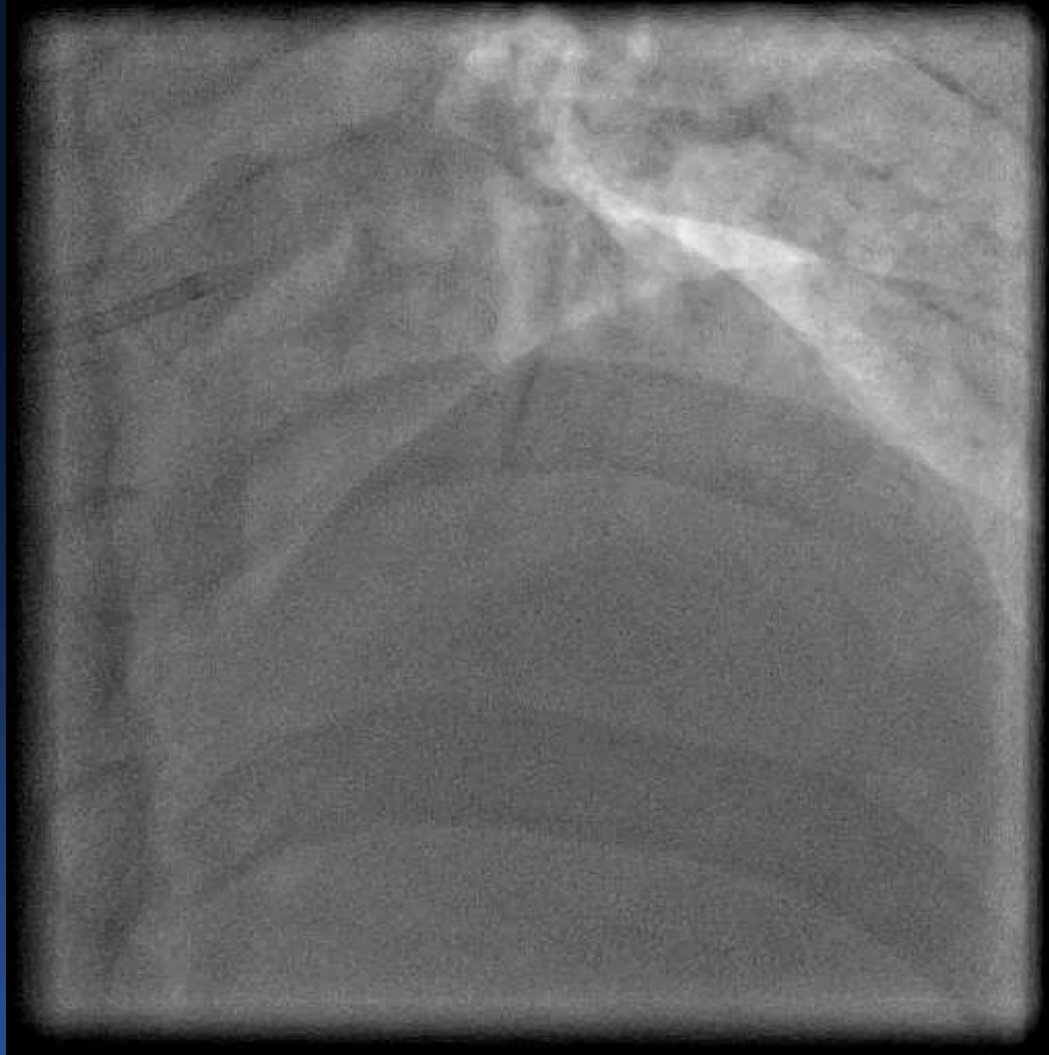How to treat?

- **Distal edge dissection**
- **Buddy wire**
- **Advance another 3.0x18mm BVS through the previous BVS**
- **Not easy...limited size and length of BVS...do not want another edge tear and keep chasing distally**
- **Post-dilated with 4.0 NC balloon proximally and 3.5mm distally**

Advancing the second BVS



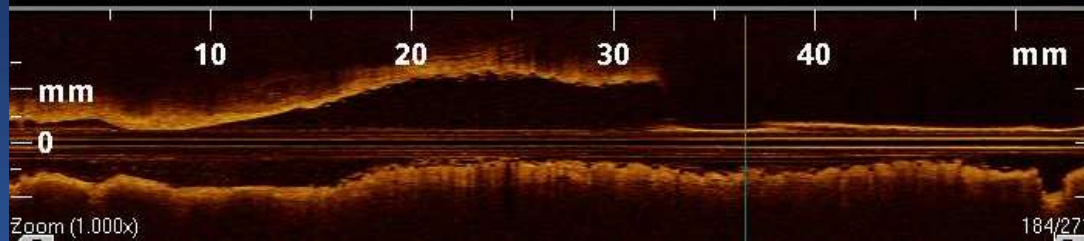
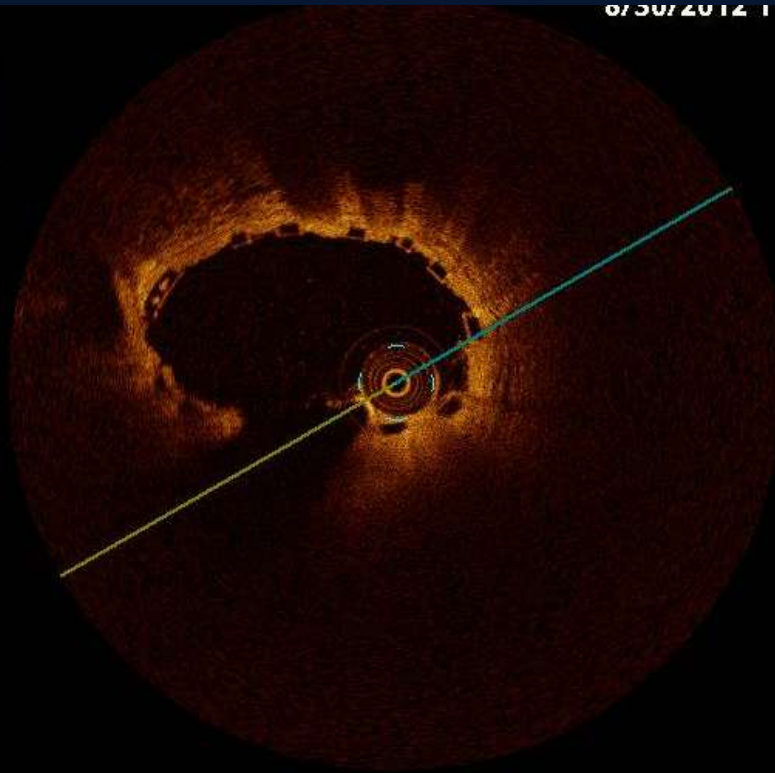
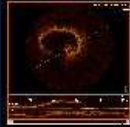Final angiogram



Final OCT

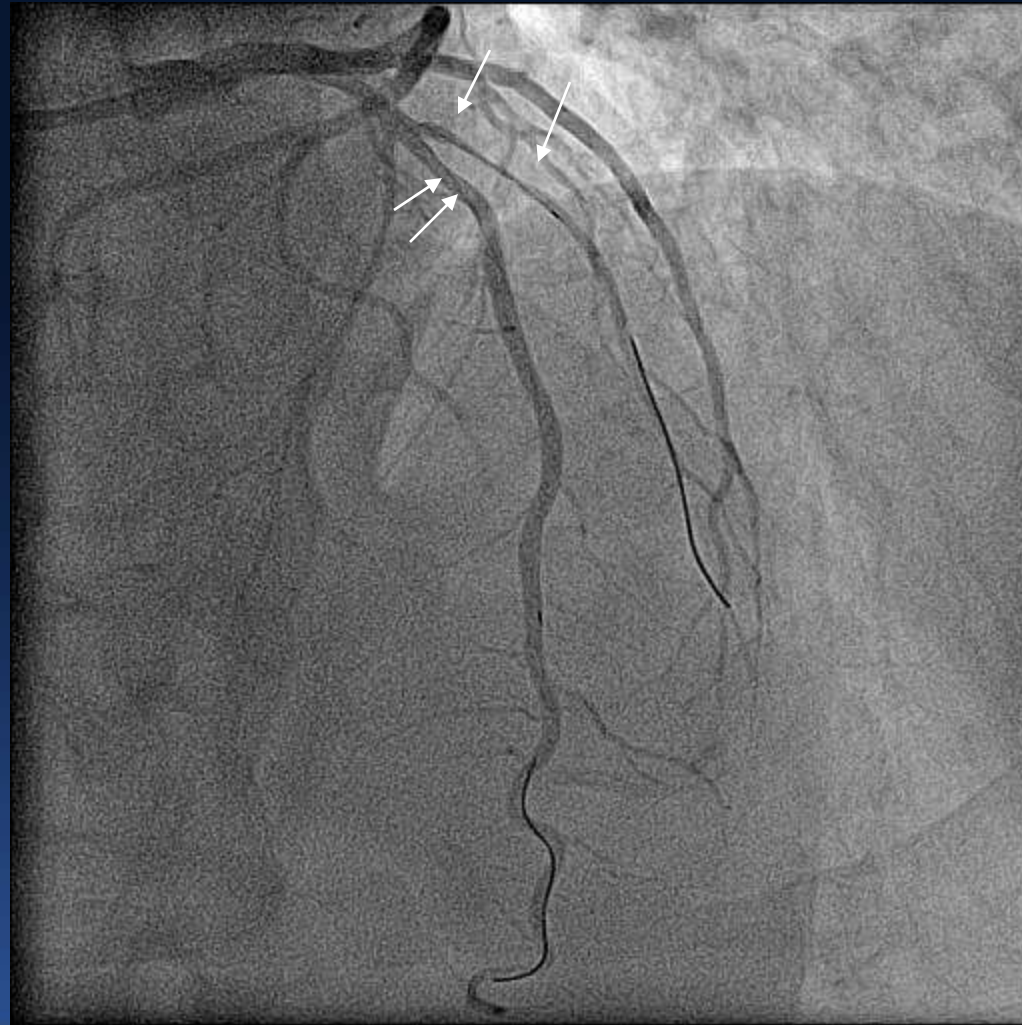
30 Aug 2012
R810848

07/30/2012 11:19:48 AM
30 Aug 2012
0184



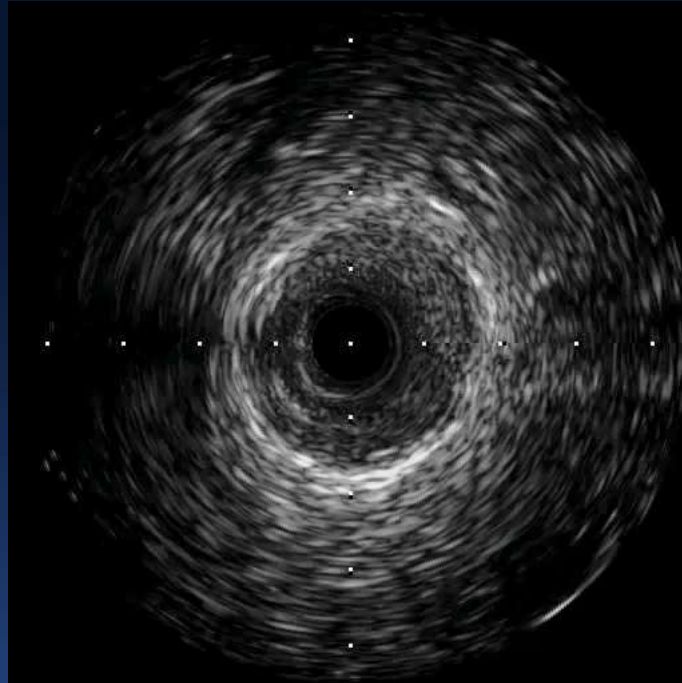
Case #3

- **M/65**
- **COPD; smoker**
- **Chest pain**
- **CTA: 70% proximal LAD stenosis**
- **Underwent PCI with BVS in LAD; Xience in D1 ; on Plavix + Aspirin**

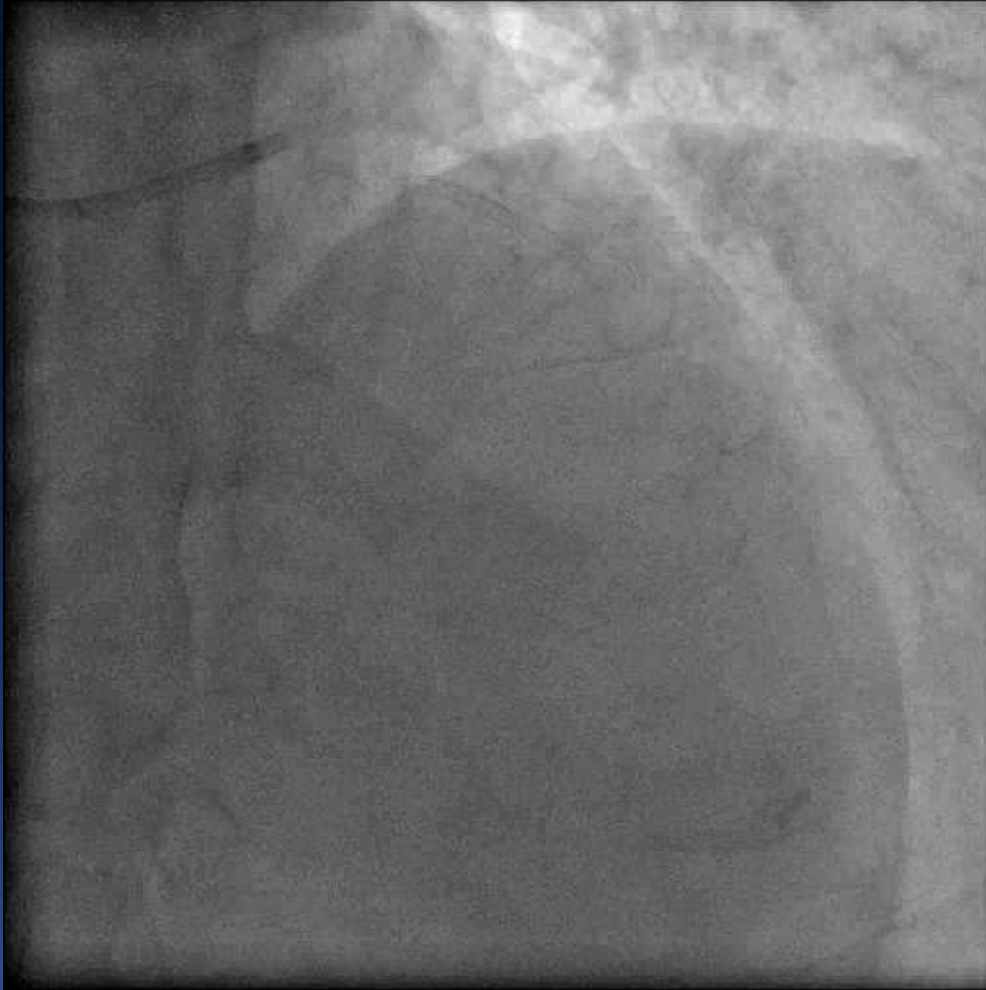


LAD and D1 disease

Pre-procedure IVUS



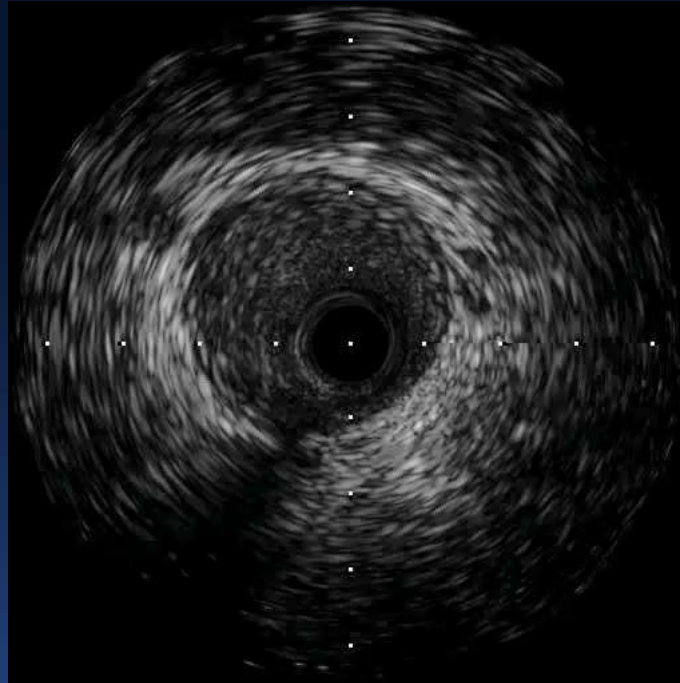
Final angiogram



*2.25x23mm Xience V to
D1, sparing the ostium*

*3.0x28mm BVS to LAD,
dilated up to 3.5mm under
IVUS guide*

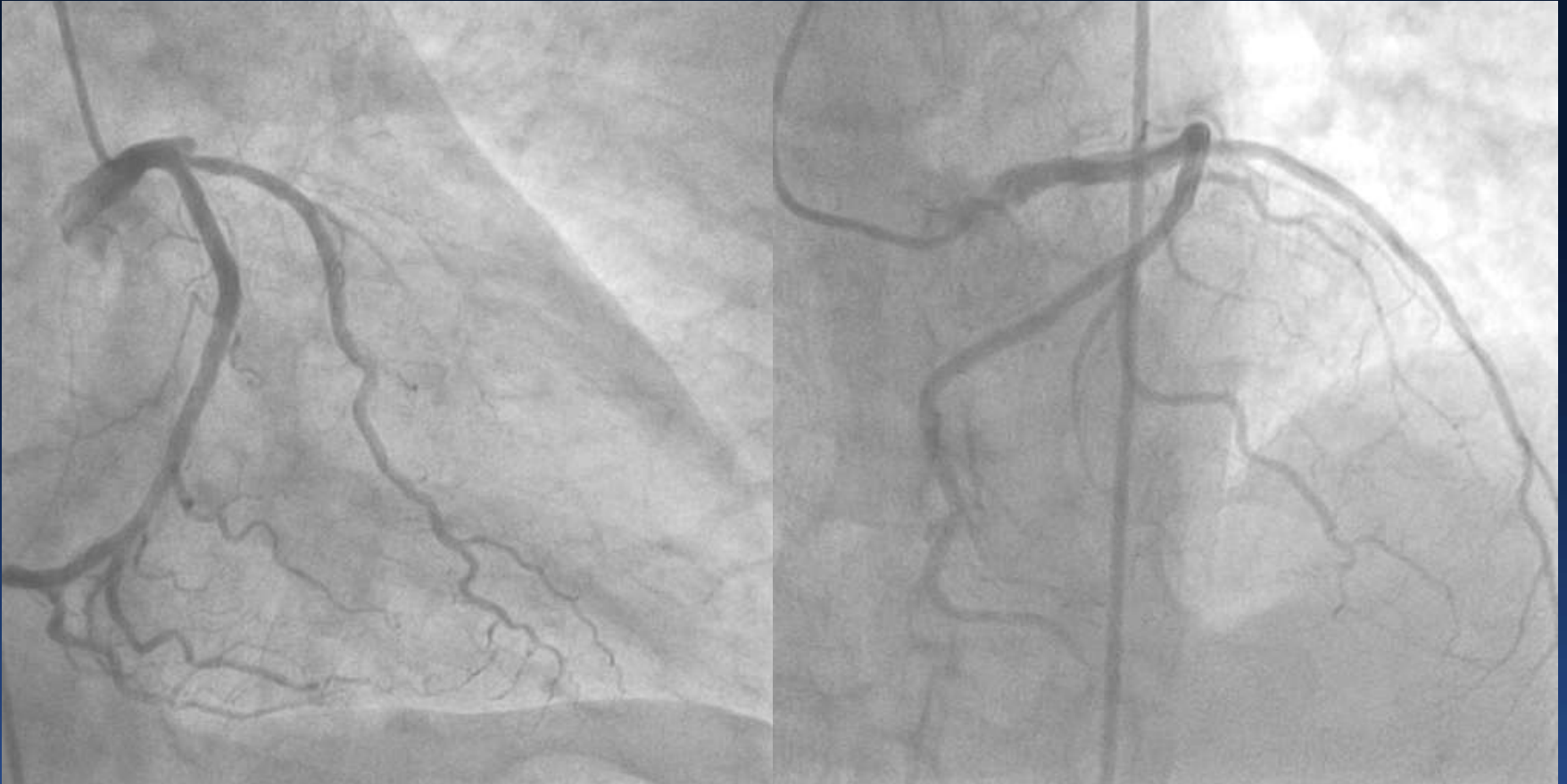Post-procedure IVUS



Progress

- **3 days after discharge (during Easter Holiday), he went to the peak for a walk**
- **Sudden onset Chest pain, sweating and SOB**
- **Called ambulance and transferred to Queen Mary Hospital**

Subacute BVS thrombosis



Courtesy of Dr. YM Lam, QMH

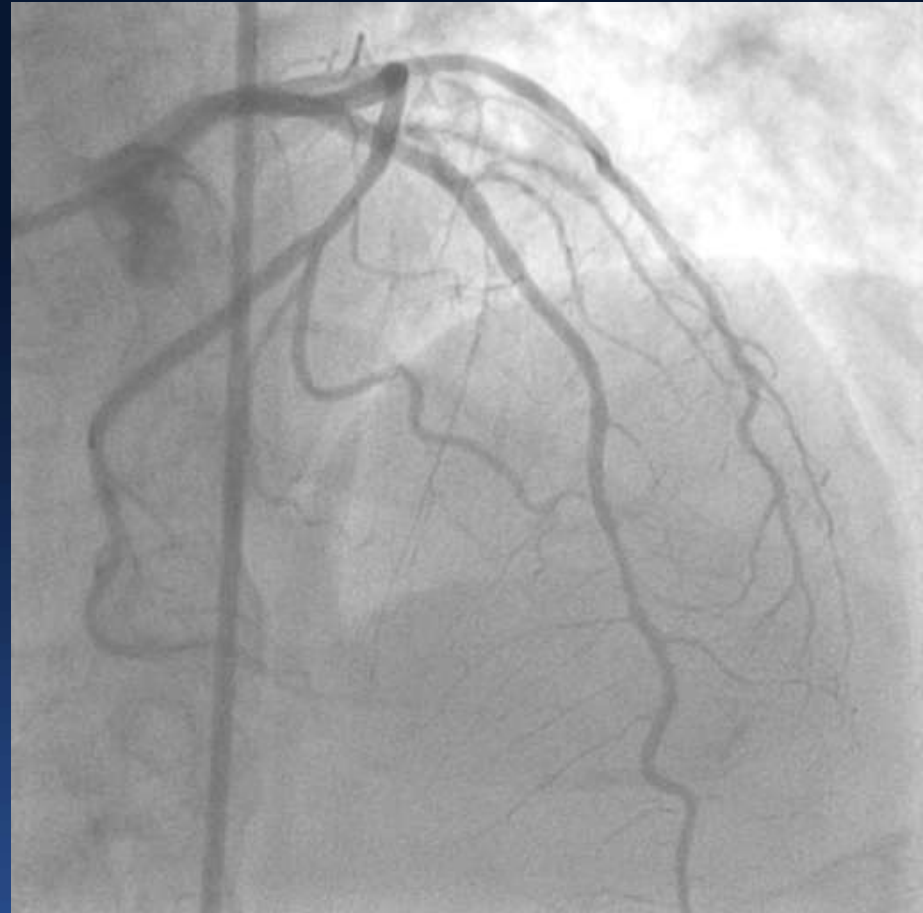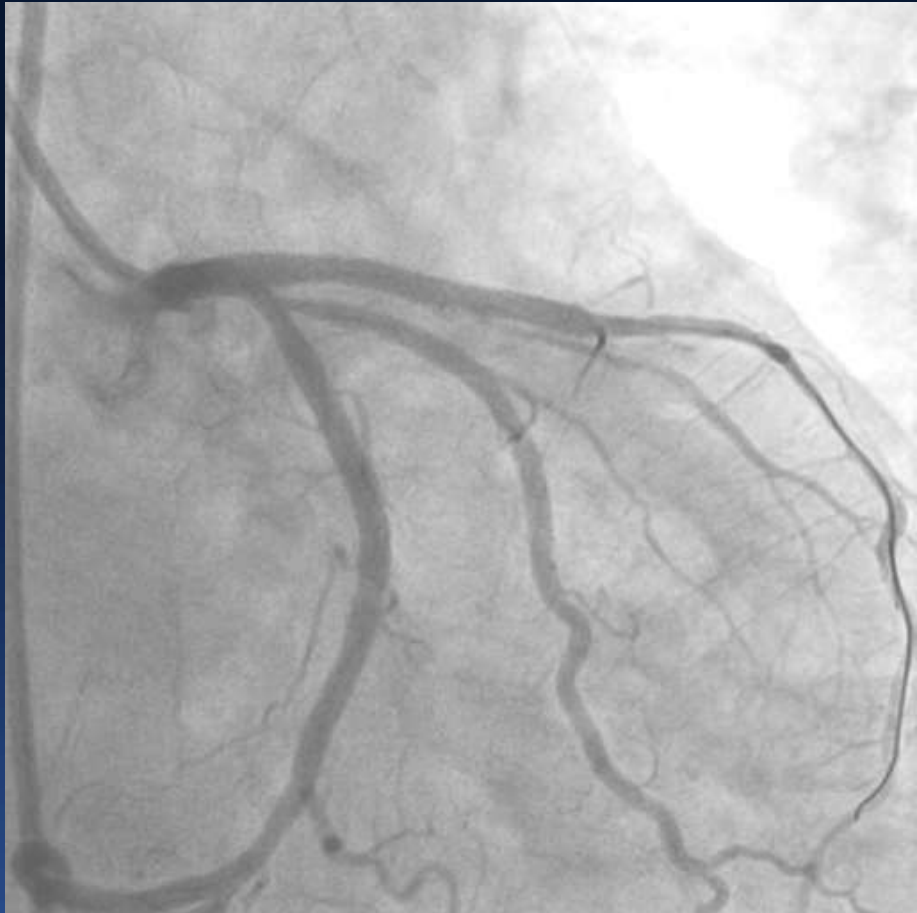How to treat?

- **Emergency thrombectomy...**
- **GpIIb/IIIa inhibitor?**
- **IVUS or OCT?**
- **Put in another BVS, DES, BMS, or EPC-coated stent?**
- **Would you change the dual anti-platelet regimen?**
- **Would you check the platelet reactivity?**

Emergency Primary PCI

- Emergency PCI with thrombus aspiration+
Genous stent implant
- Switch to Ticagrelor

Final angiogram after Genous Stent



Courtesy of Dr. YM Lam, QMH

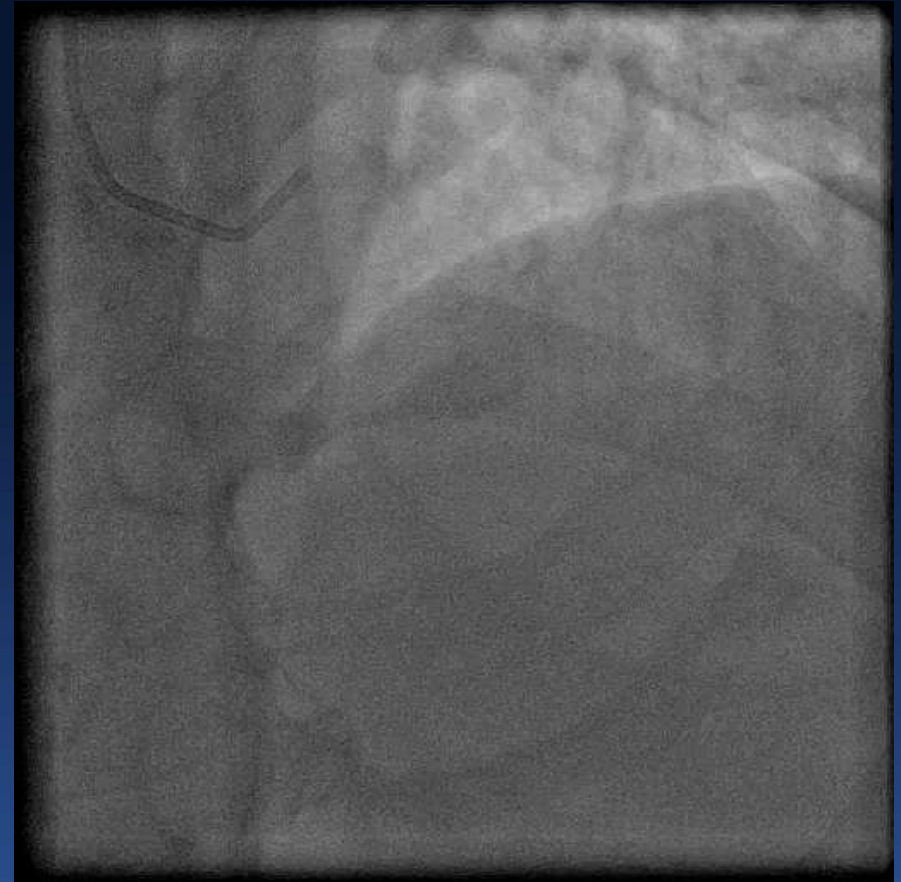
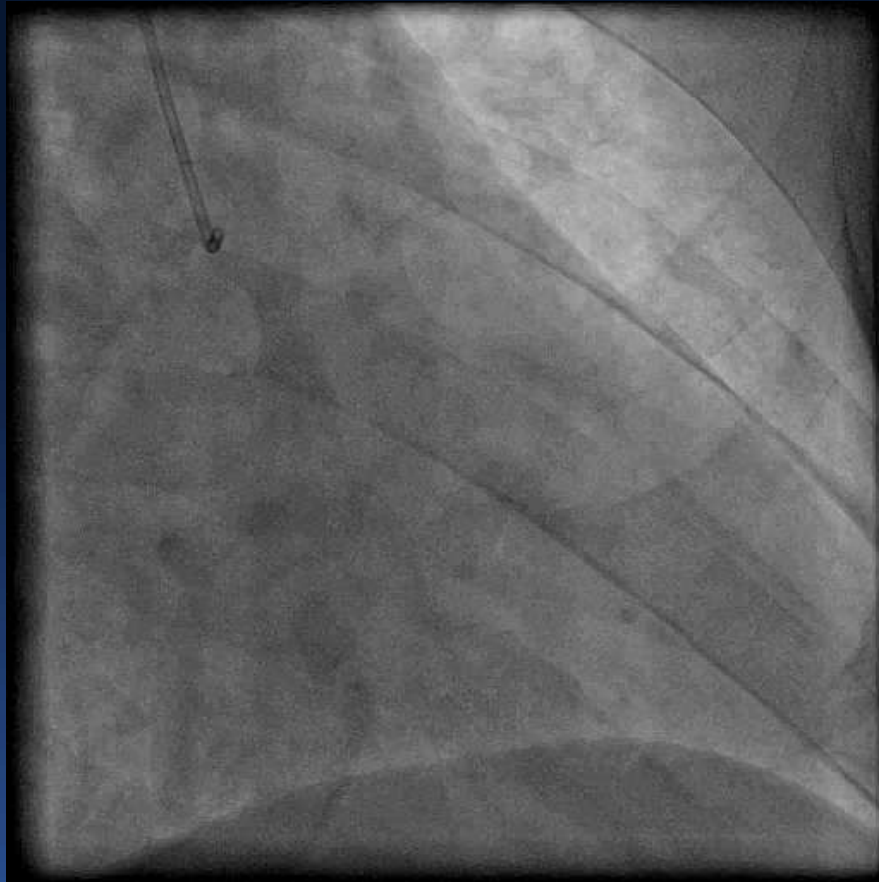Progress

- c/o Dyspnoea
- Mild CHF; wheezy chest
- Switch to Prasugrel for 4 days; recheck VerifyNow (P2Y12): 276 PRU ; 0% platelet inhibition; PFA-100: 115 sec (normal closure time)
- Probably homozygous recessive for the CYP2C19 enzyme
- Switch back to Ticagrelor: repeat VerifyNow (P2Y12): 89 PRU, 70% platelet inhibition

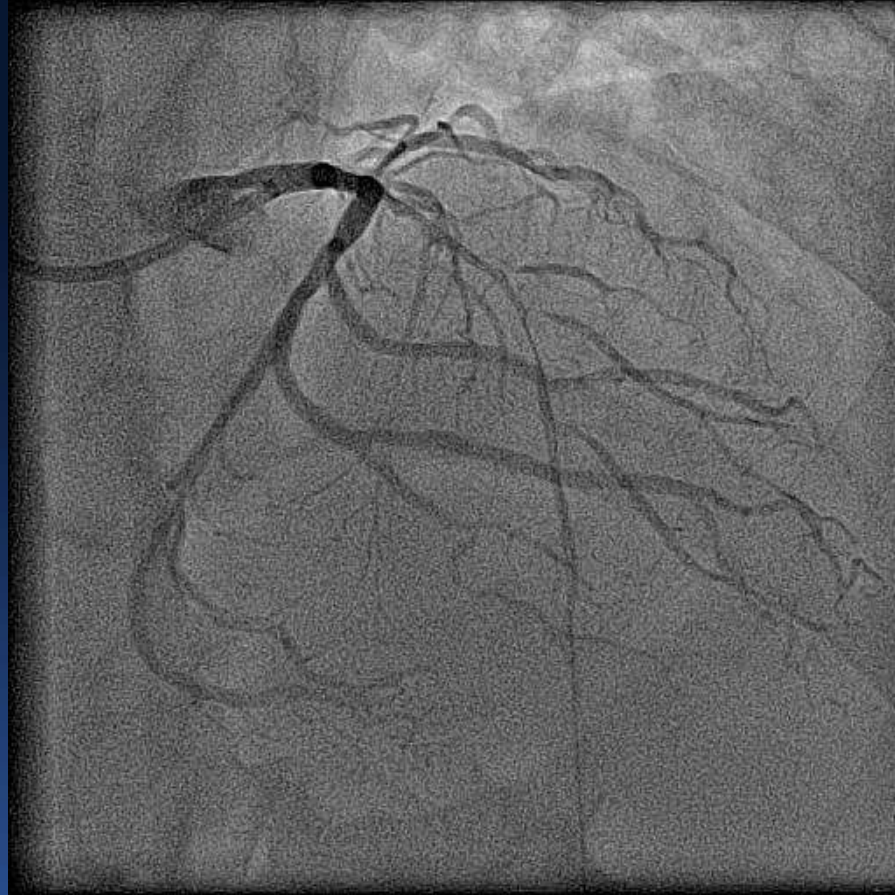
Case #4

- **40 year-old**
- **Smoker, high cholesterol, hypertension**
- **Acute STEMI (anterior)**
- **Admitted to Shanghai ZhongShan Hospital**
- **No Lytic; no Primary PCI; only LMWH for 3 days**
- **Residual chest pain**
- **Asked 2 drivers to drive him to Hong Kong**
- **16 hours!**

Coronary Angiogram



After predilation with 2.0mm balloon Diffusely diseased LAD

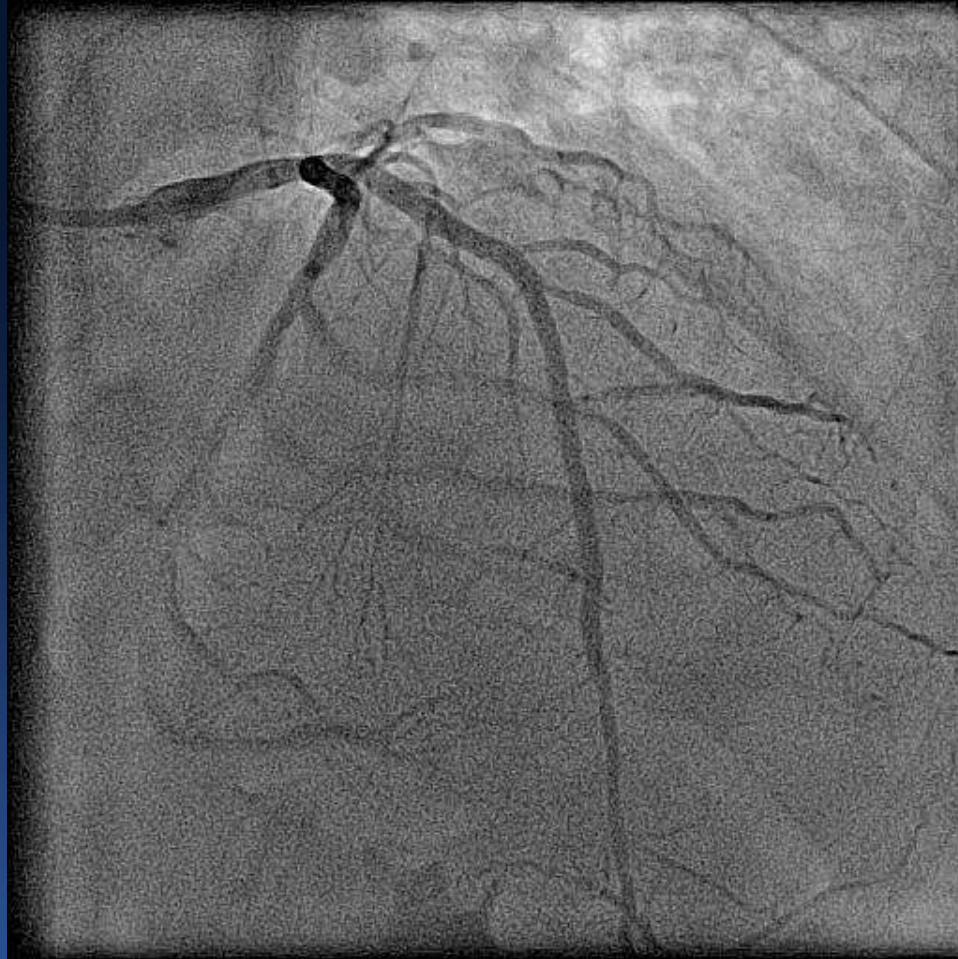


How to treat?

- **DES or BVS?**
- **IVUS or OCT?**

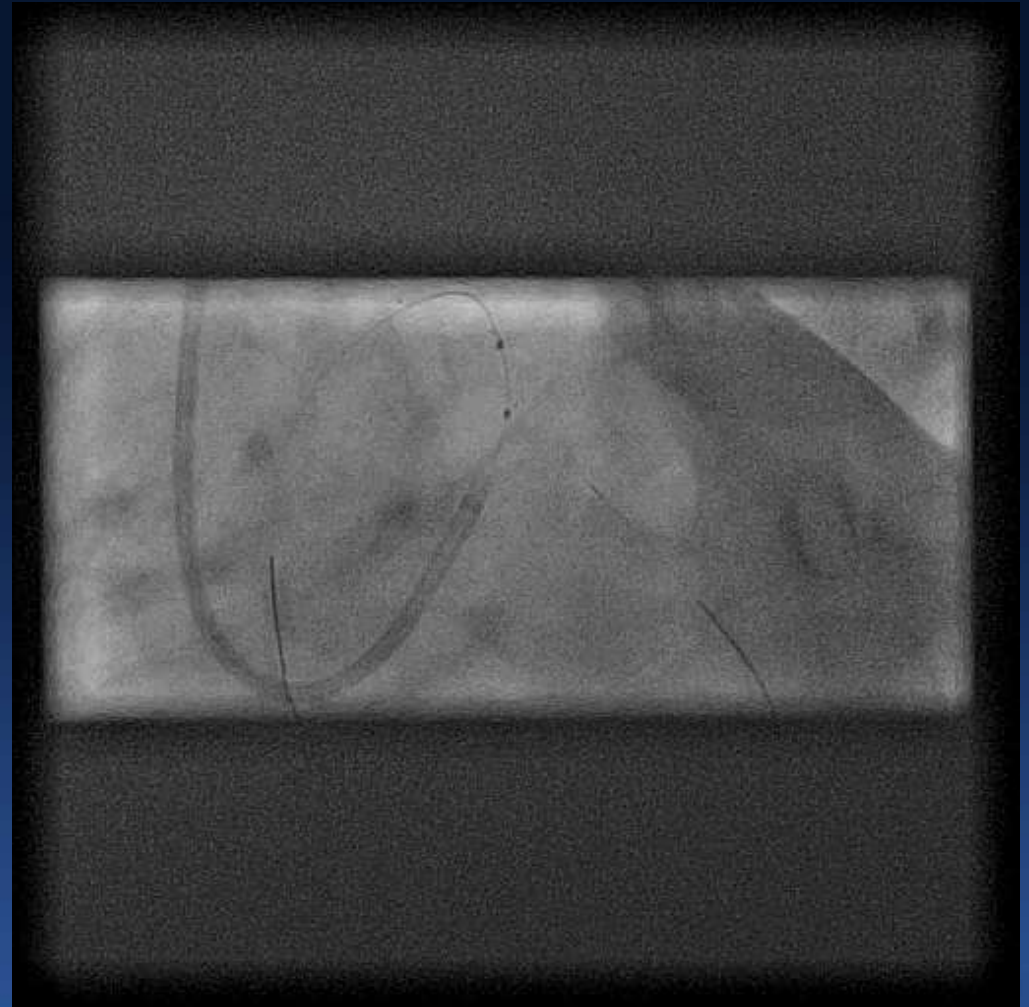
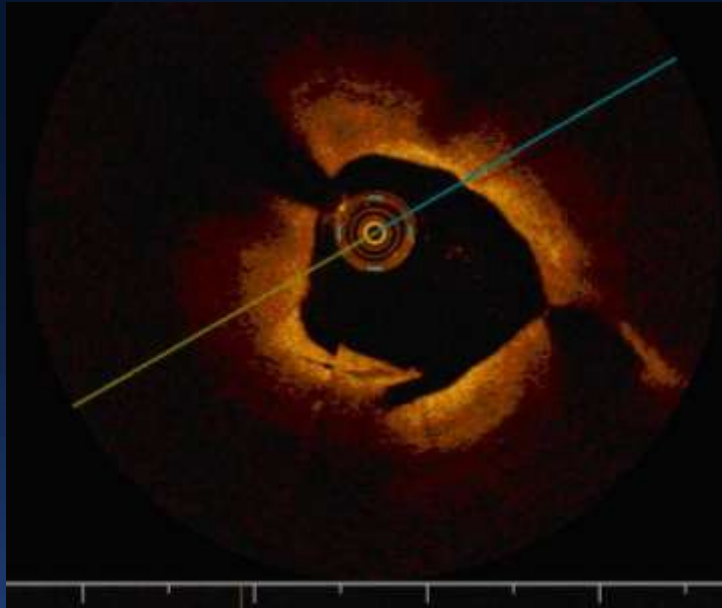
Diffuse LAD disease

Treated with full BVS jacket: 3.0x28mm + 2.5x28mm + 2.5x28mm, dilated up to 3.0/2.75mm with NC balloons. POBA diagonals with 2.0mm balloons

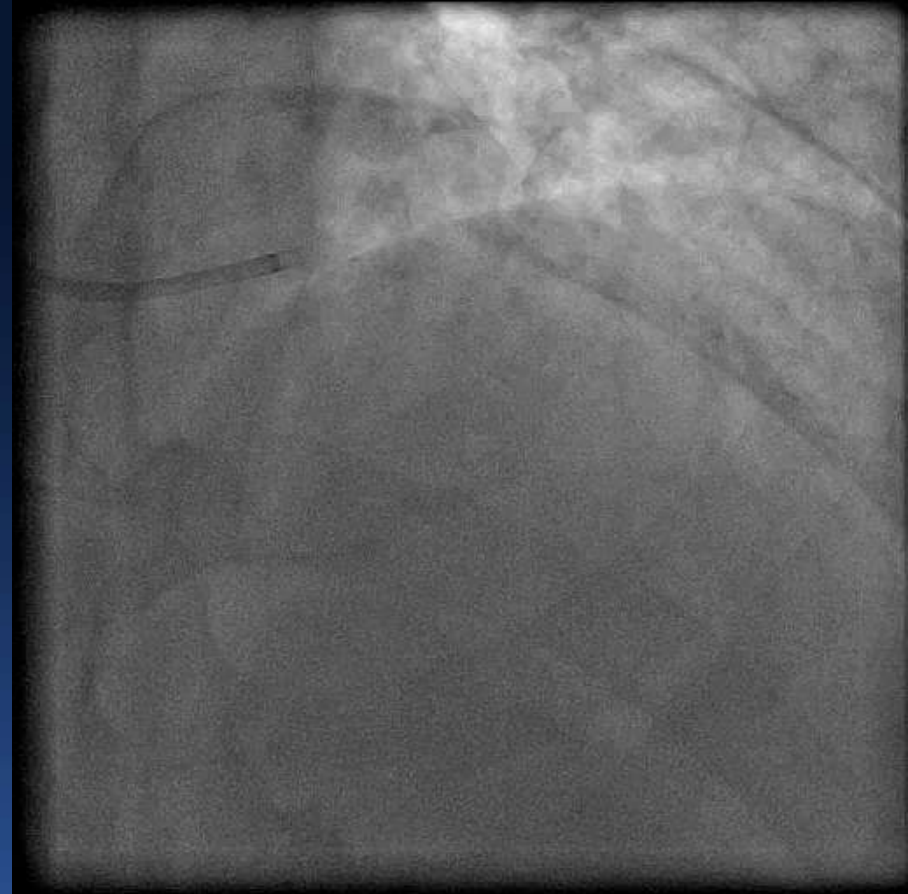
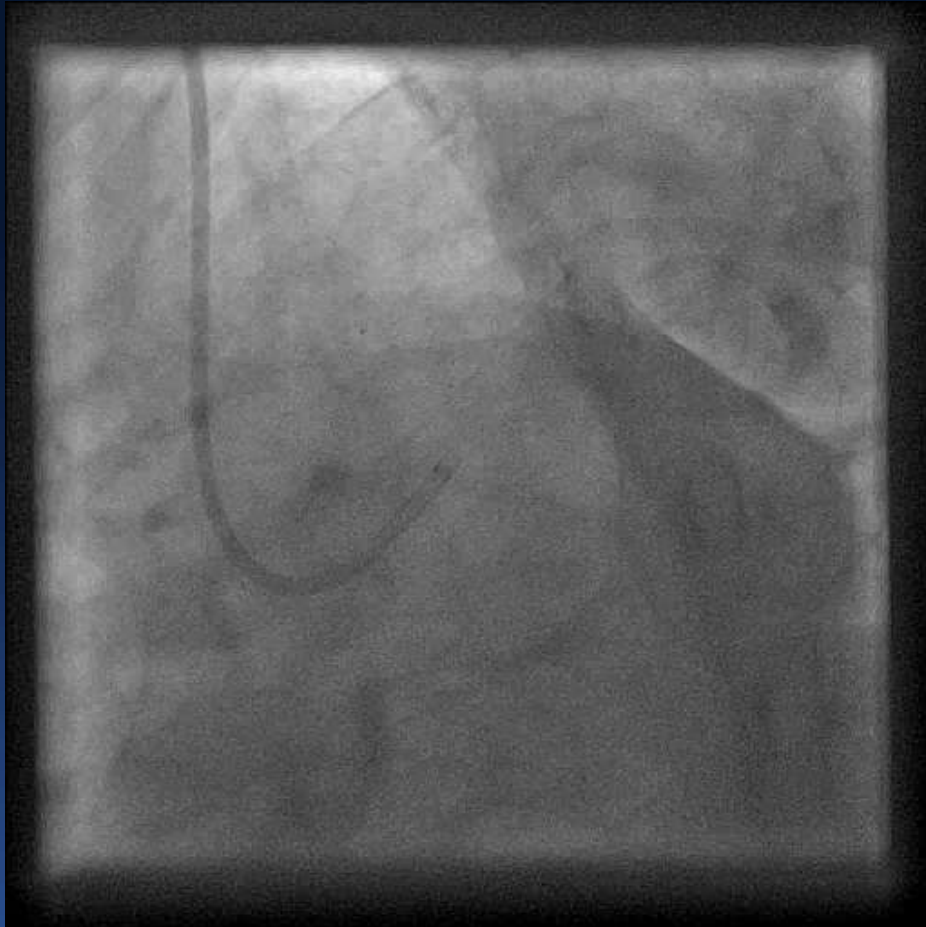


Ostial LAD dissection

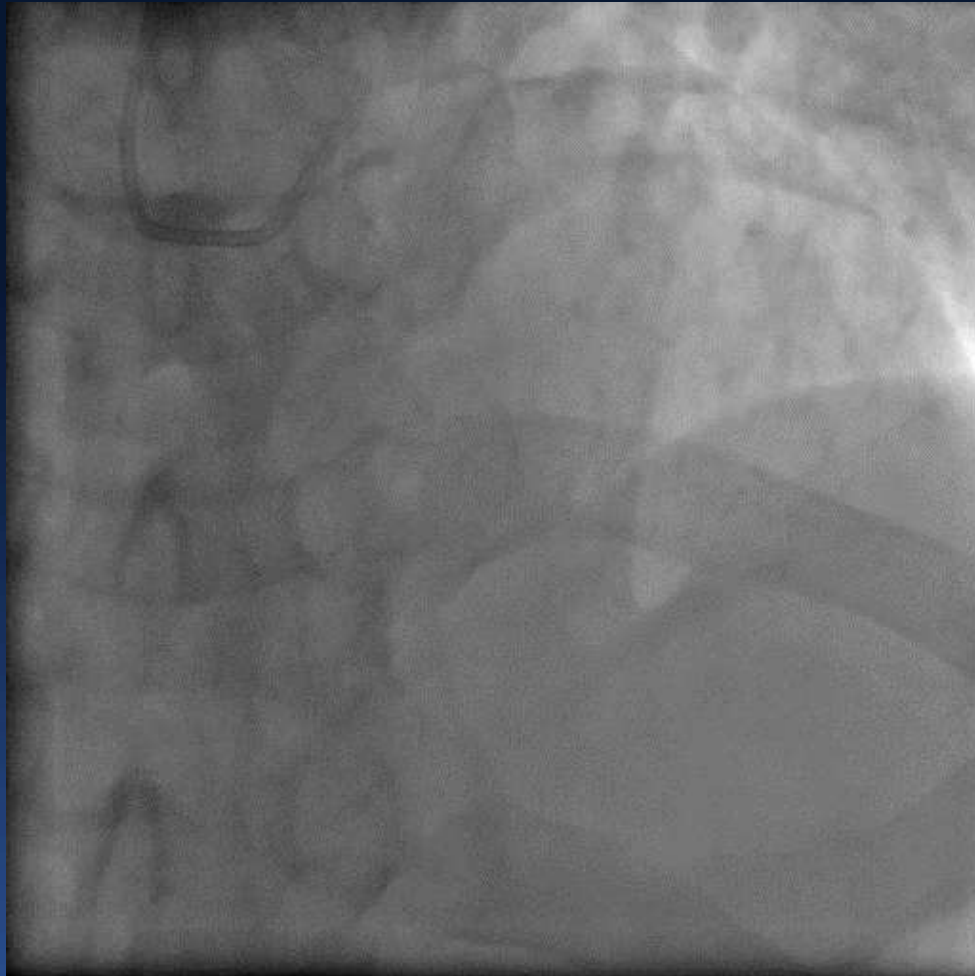
3.5x12mm BVS at the ostium



Final angiogram



Case #5



M/58 yrs

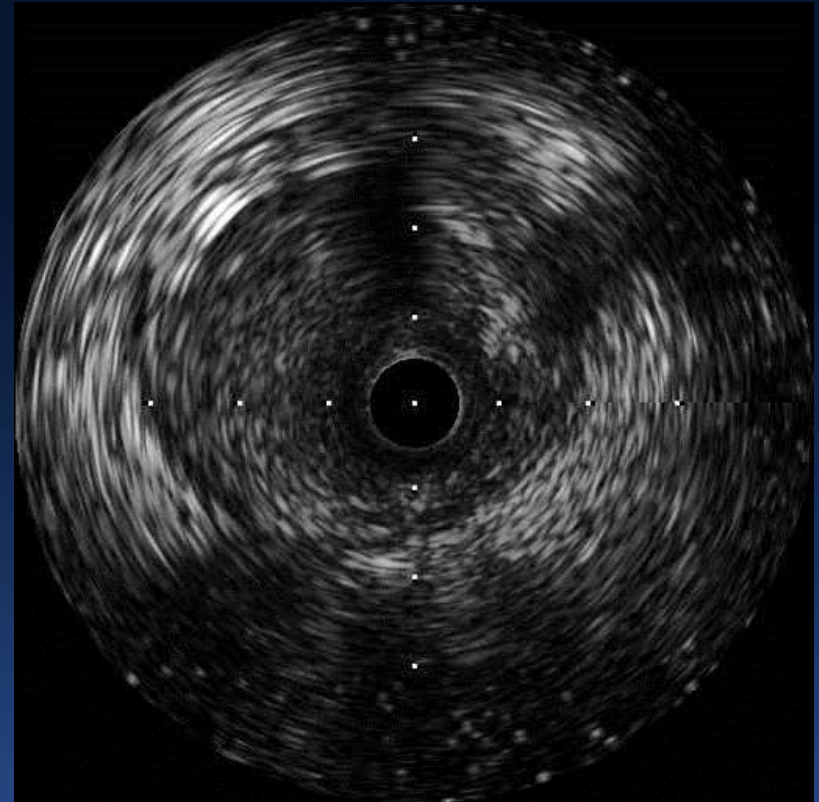
High cholesterol

Unstable angina

**CTA: severe proximal
LAD stenosis**

IVUS-guided PCI with BVS implant

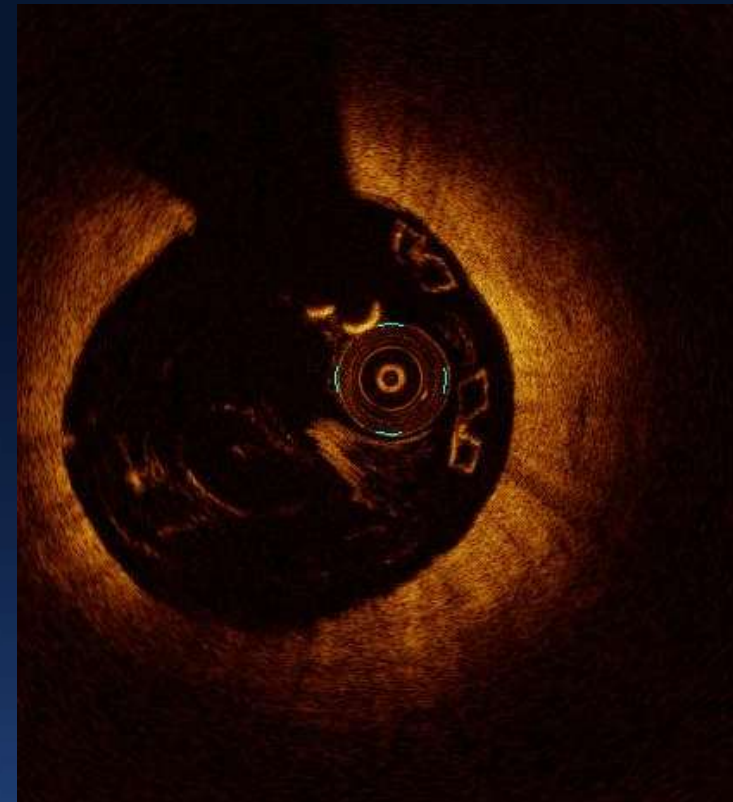
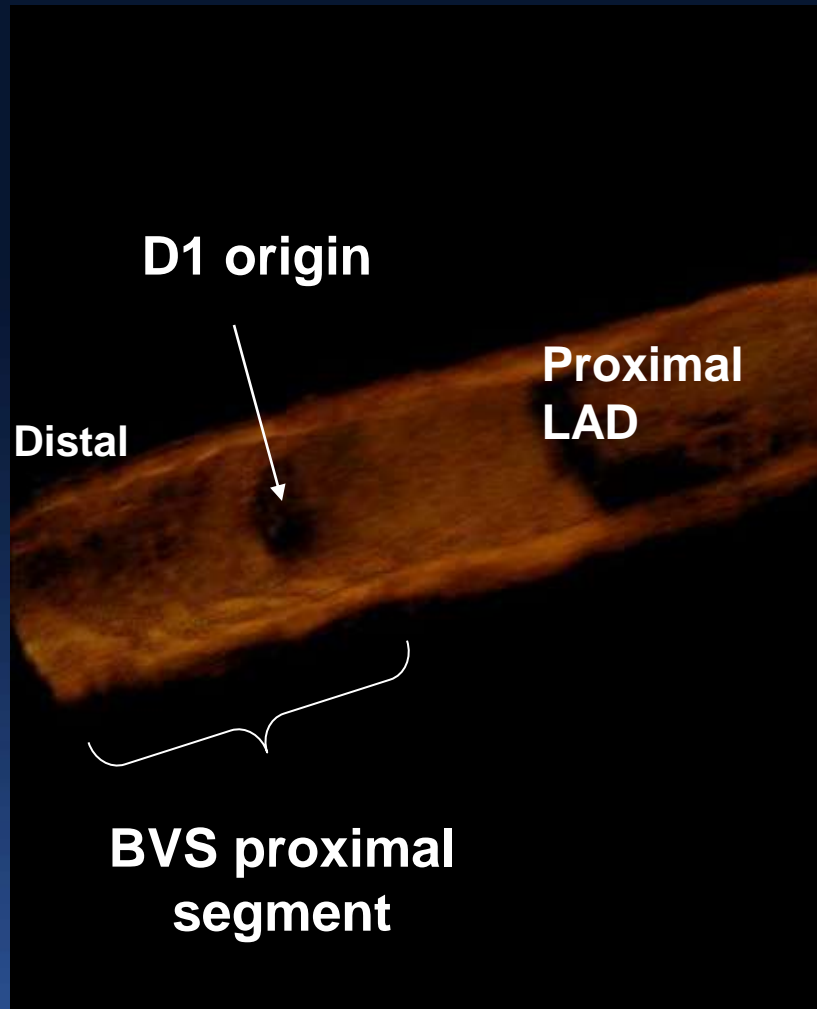
- BVS 3.5x18mm + 3.0x18mm
- Post-dilated with 3.75/3.5mm NC balloons
- IVUS showed some “anomaly” at 2o'clock



How to treat?

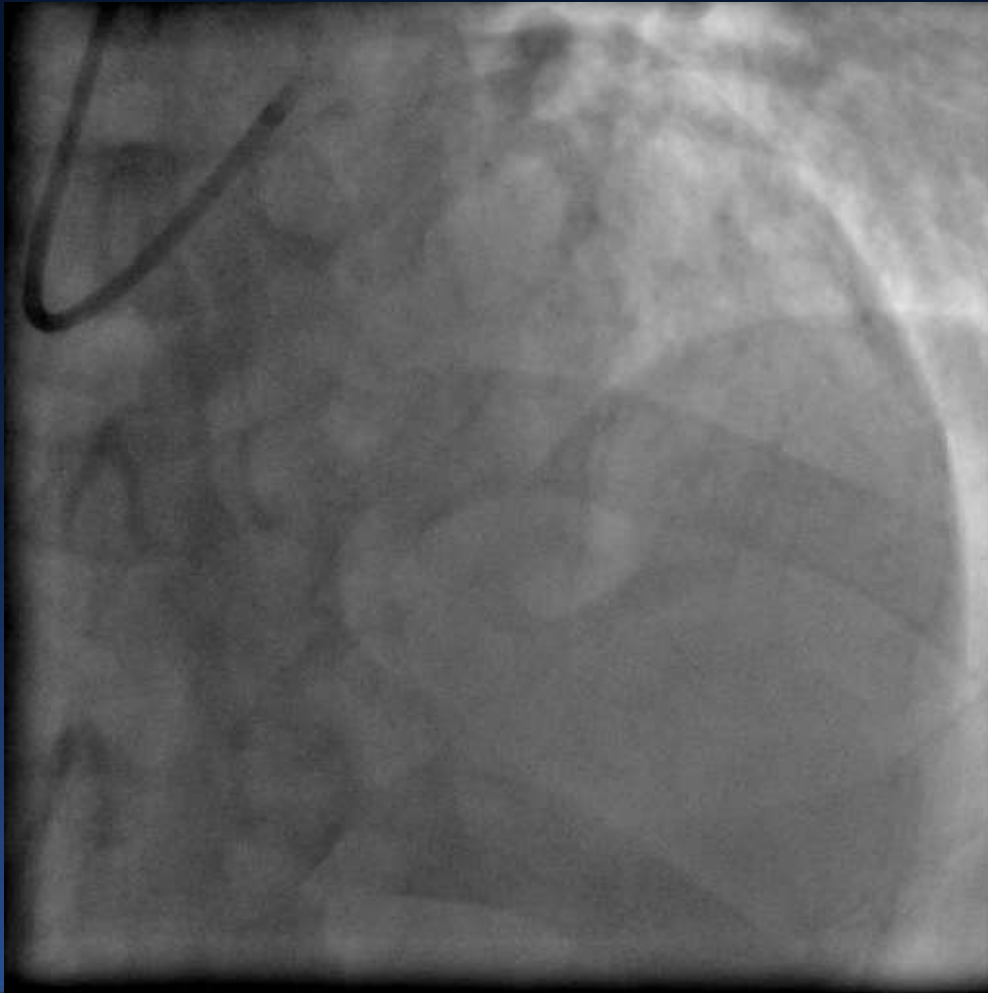
- **Dissection flap, plaque prolapse, BVS malapposition/fracture?**
- **OCT?**
- **Just put in another BVS?**

3D OCT

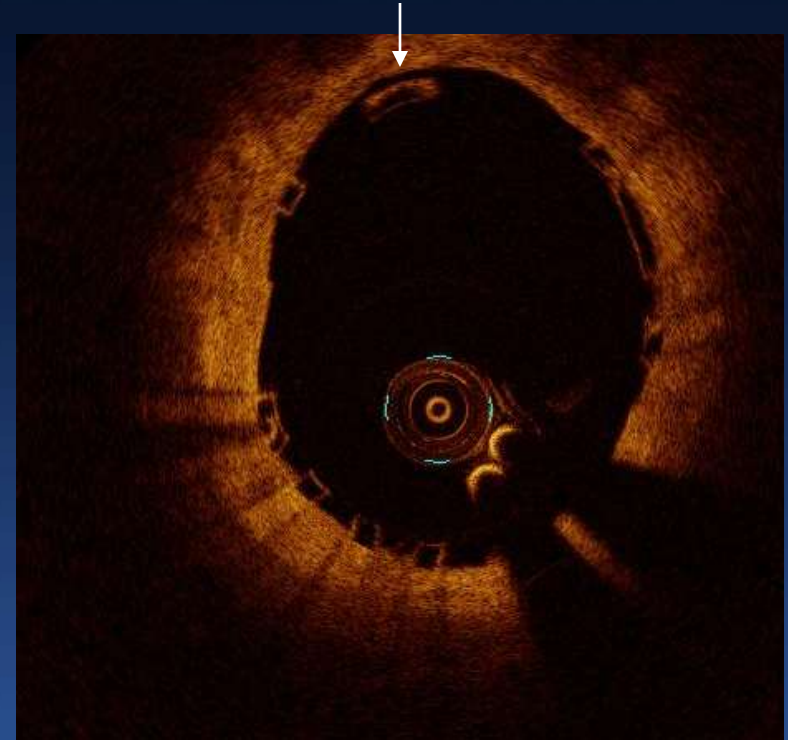


Under-expansion and mal-apposition

Further expanded with 4.0mm NC balloon at 18 ATM

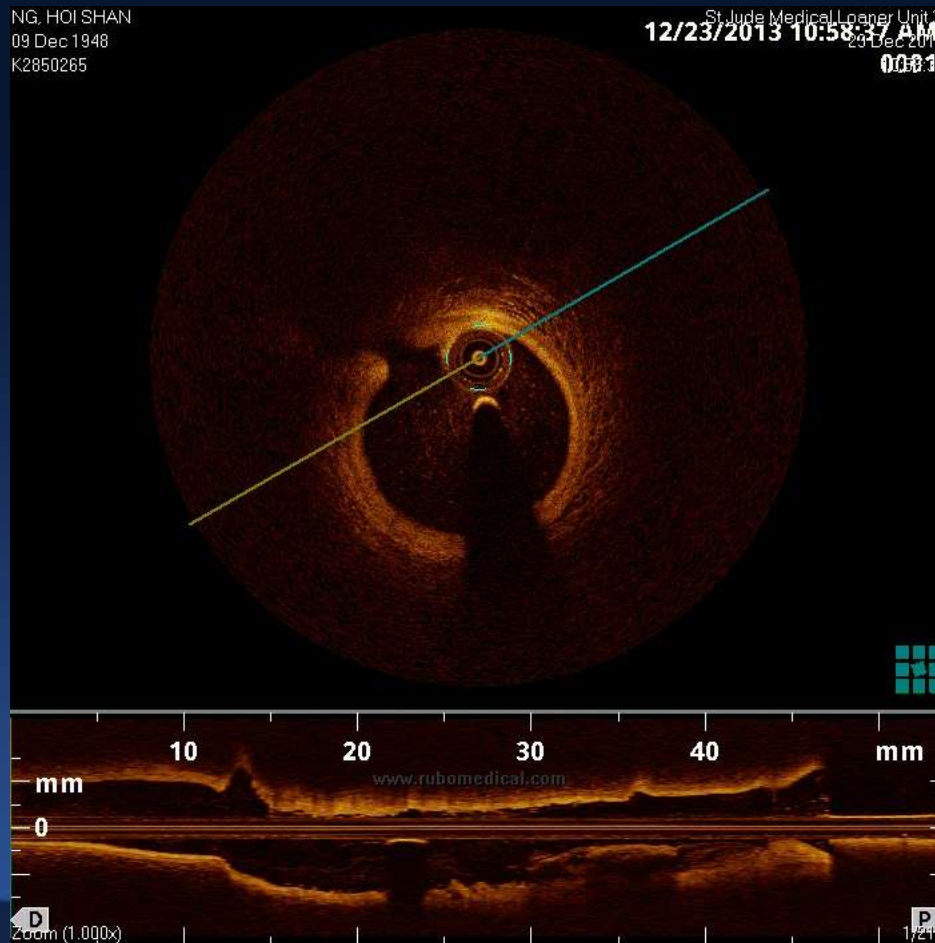


Minor residual
malapposition



Supplementary OCT images

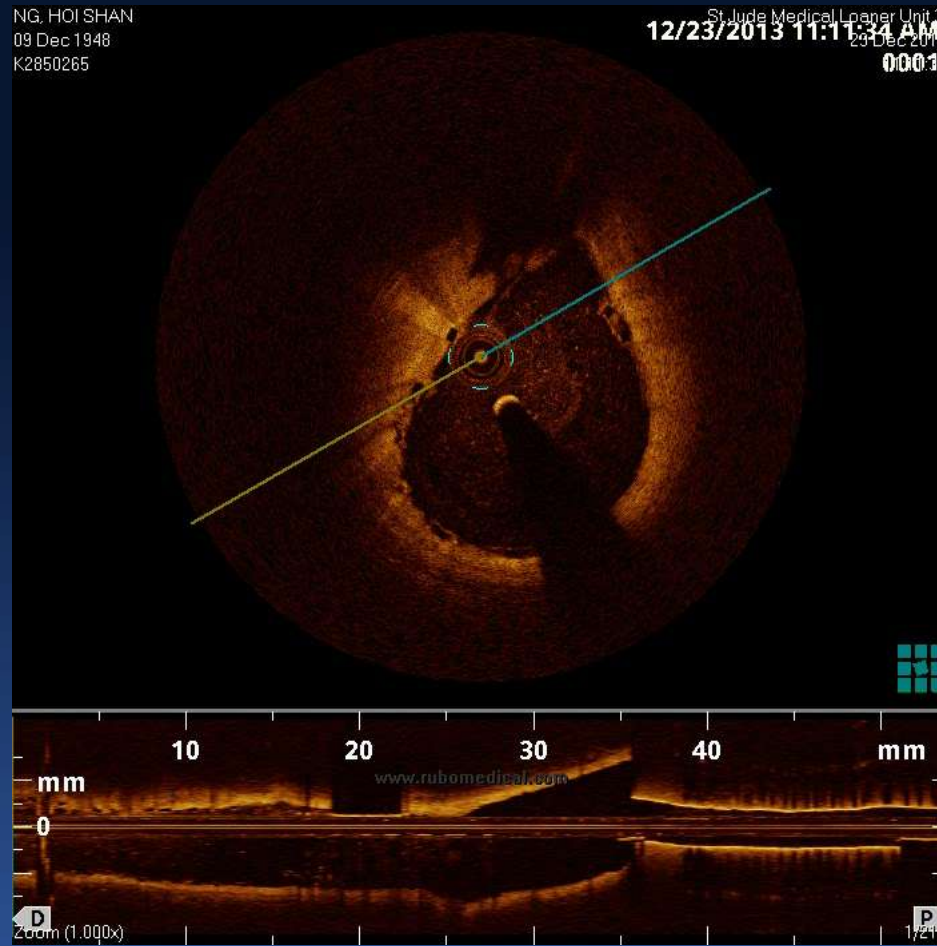Plaque prolapse



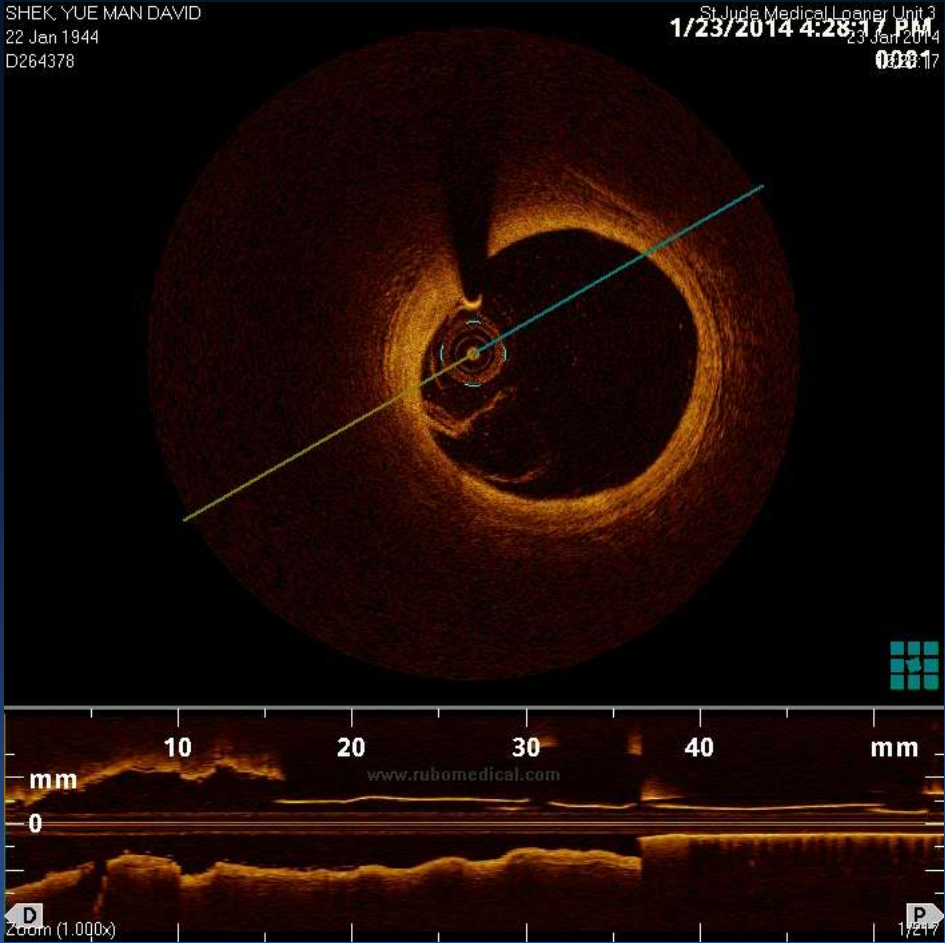
How to treat?

- **Put in another BVS?**
- **Put in another DES/BMS/EPC-coated stent?**
- **Further high pressure inflation?**
- **Leave it alone?**

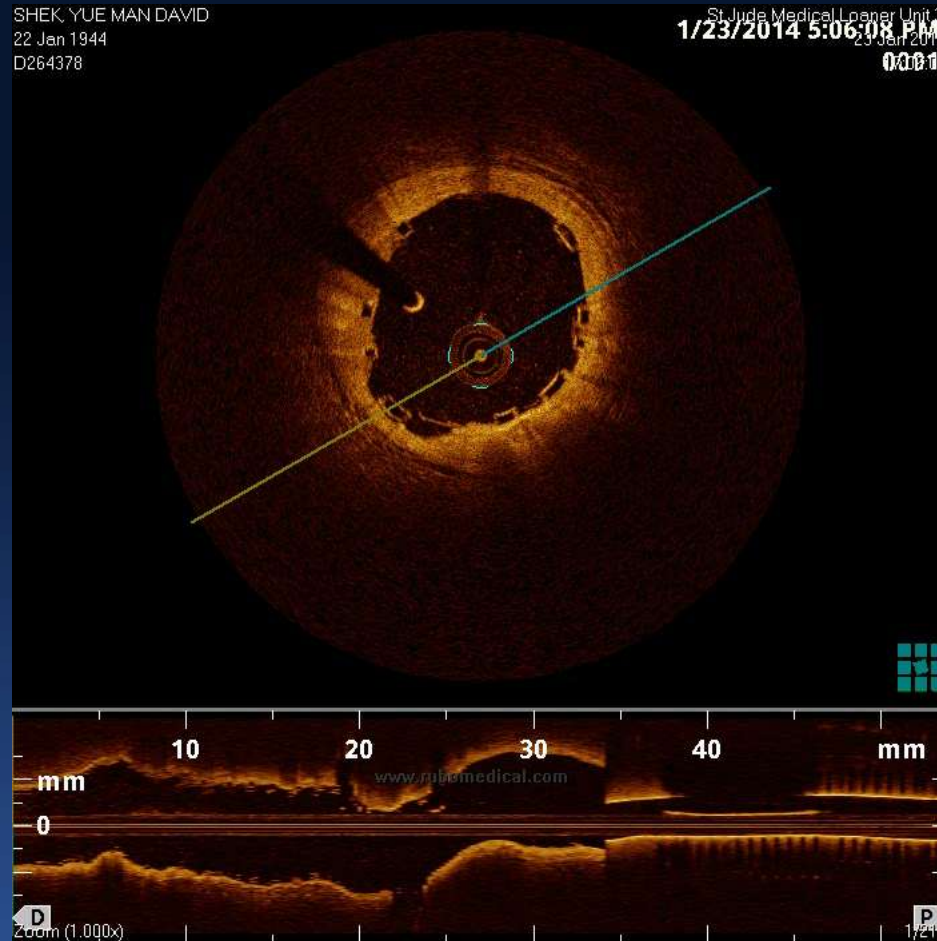
OCT after further dilation with high pressure



Edge tear and under-expansion in a calcified lesion



OCT after second BVS implant and high pressure inflation with a NC balloon



A decade of stent evolution: from DES to BVS

