Coronary Artery Perforation
Angioplasty Summit – Seoul
April 30, 2005

James R. Margolis, M.D.
Miami International Cardiology Consultants
Miami, Florida USA

Introduction

- In the stent era, coronary artery perforation has become the most serious complication and a leading cause of death in percutaneous coronary intervention.
- Although preventable to a great extent, perforations are inevitable in any high volume center.
- Prompt recognition and treatment of perforations can make the difference between benign and fatal outcomes.
- The incidence of coronary artery perforation varies with the complexity of disease under treatment and with the aggressiveness of individual operators.
  - An operator who never experiences a perforation is probably under-dilating lesions and under-deploying stents.
  - Reported incidence of perforation varies from 0.2-0.6%. It is much higher when atheroablative devices are used (1-3).
- Although there is no good series reporting the effect of stenting on the incidence of perforation, routine stenting most likely increases the perforation rate.

MIAMI INTERNATIONAL CARDIOLOGY CONSULTANTS, INC.

Classification of Ellis et al*

- Type I: Extra-luminal crater without extravasation (this might also be termed a pseudoaneurysm)
- Type II: Pericardial or myocardial blush without contrast jet extravasation
- Type III: Extravasation through a ≥ 1 mm perforation.
- This classification correlates with prognosis.
- A fourth category is designated cavity spilling, in which the perforation empties into an anatomic cavity – RV, LV, Coronary Sinus, etc.

**Circulation* 90:2725-2730, 1994

MIAMI INTERNATIONAL CARDIOLOGY CONSULTANTS, INC.

Type I Perforation

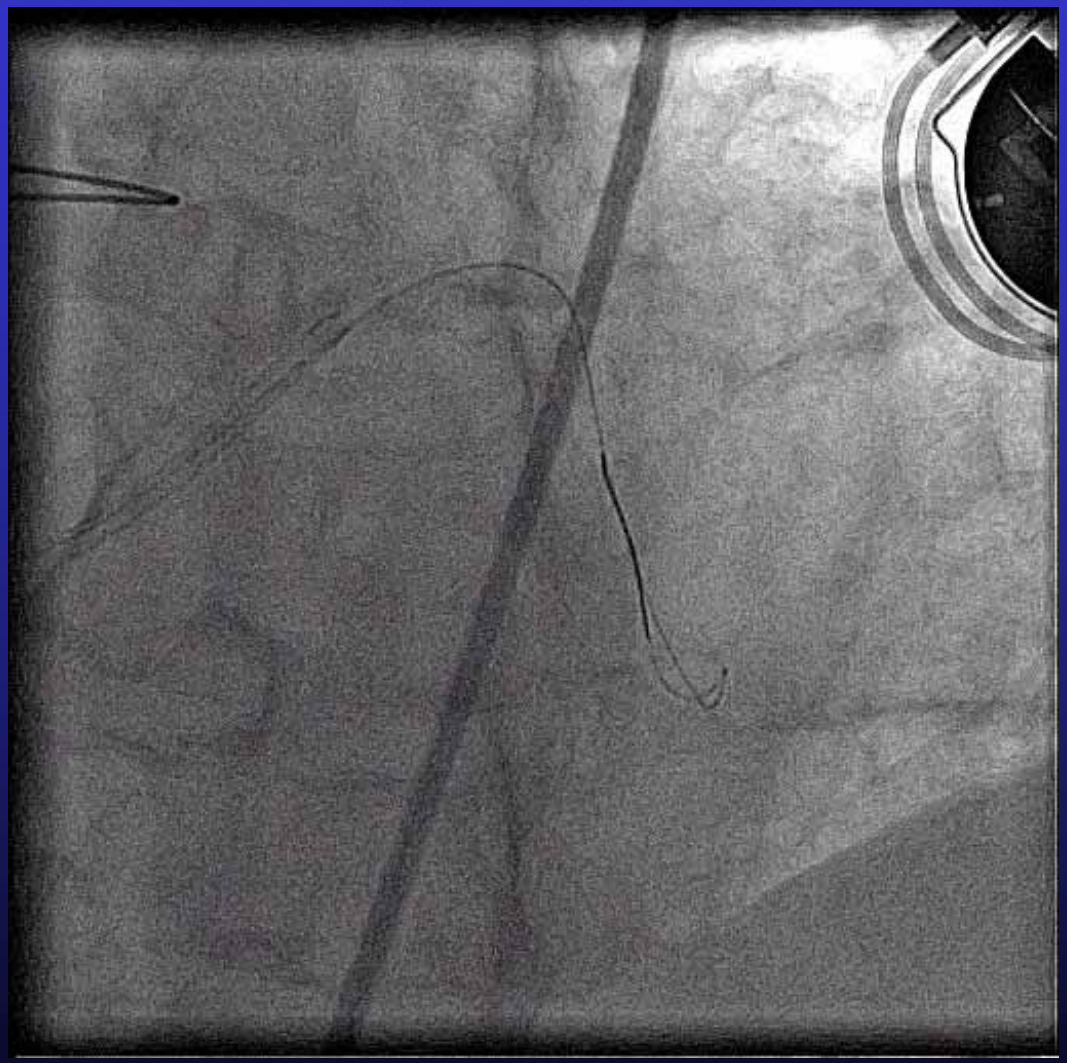

MIAMI INTERNATIONAL CARDIOLOGY CONSULTANTS, INC.

Type II Perforation

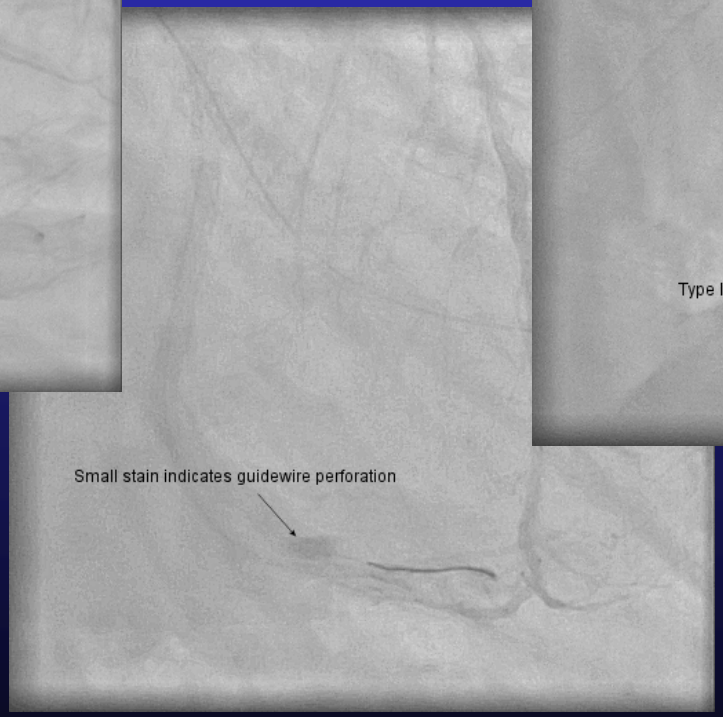

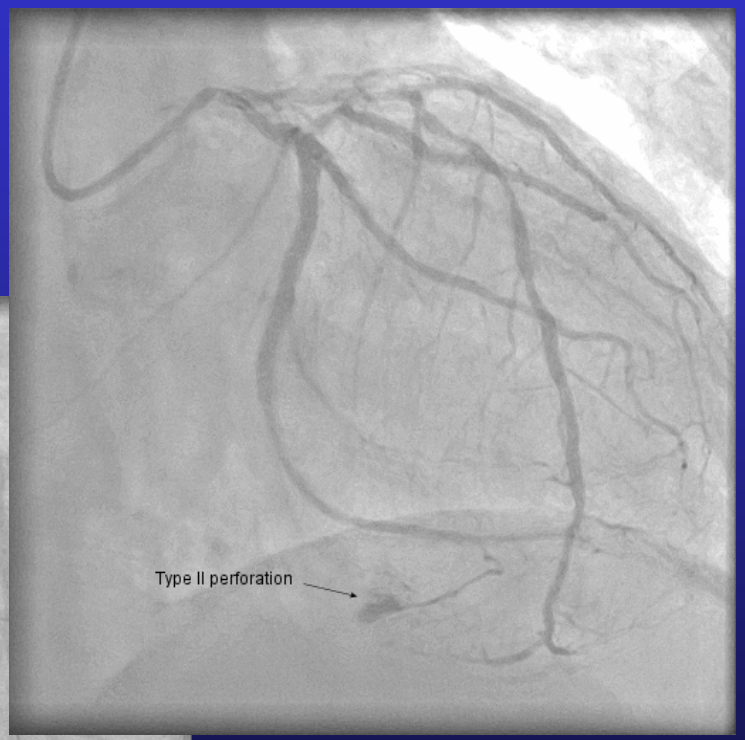

MIAMI INTERNATIONAL CARDIOLOGY CONSULTANTS, INC.

Type III Perforation

MIAMI INTERNATIONAL CARDIOLOGY CONSULTANTS, INC.

Perforation Into Anatomic Cavity

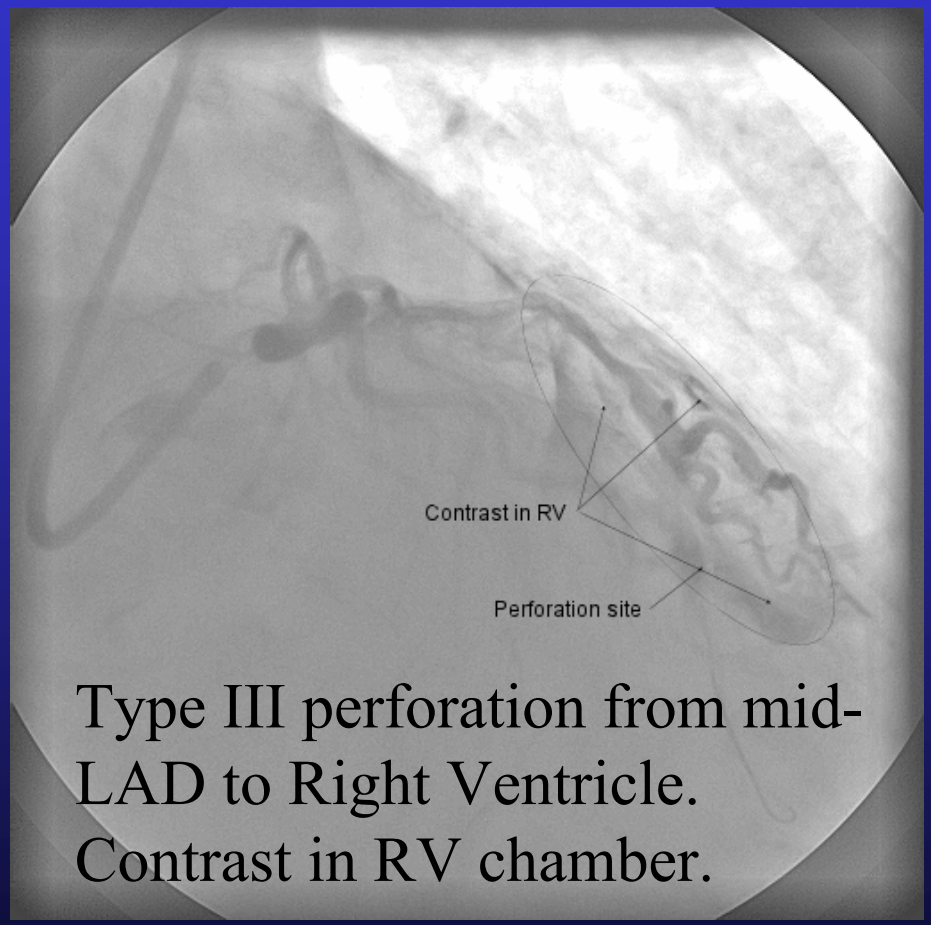

Type III perforation from mid-LAD to Right Ventricle. Contrast in RV chamber.

Contrast seen in RV outflow track.

MIAMI INTERNATIONAL CARDIOLOGY CONSULTANTS, INC.

Alternative Classification

- By size
  - Small perforations
  - Large perforations
- By location
  - Native arteries
  - Vein grafts
  - Proximal arteries
  - Distal arteries
- Involving bifurcations
- Small branches
- By cause
  - Balloons
  - Stents
  - Devices
  - Guidewires
- Perforations caused during treatment of CTO's

MIAMI INTERNATIONAL CARDIOLOGY CONSULTANTS, INC.

High Risk Situations

- Lesions on bends
- Bifurcation lesions
- Lesions in branches and distal vessels
- Acute margin lesions at RV branch
- Ostial RCA
- Calcified vessels
- Vein Grafts
- Eccentric lesions
- Guidewire Perforations

MIAMI INTERNATIONAL CARDIOLOGY CONSULTANTS, INC.

Eccentric Lesions Are More Likely to Perforate

- IVUS image is maybe predictable…???

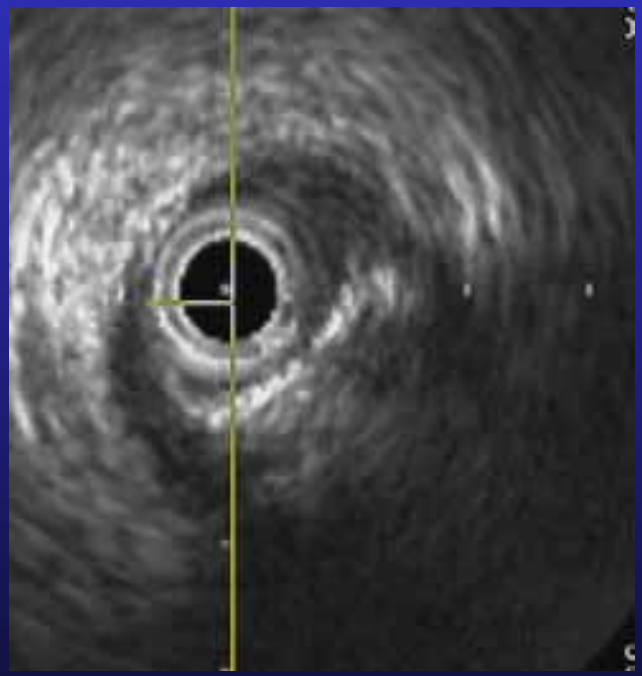

Normal wall is overstretched and ruptures



Courtesy S. Sumitsuji

MIAMI INTERNATIONAL CARDIOLOGY CONSULTANTS, INC.

Acute Margin Perforation Solved With Jo-Stent

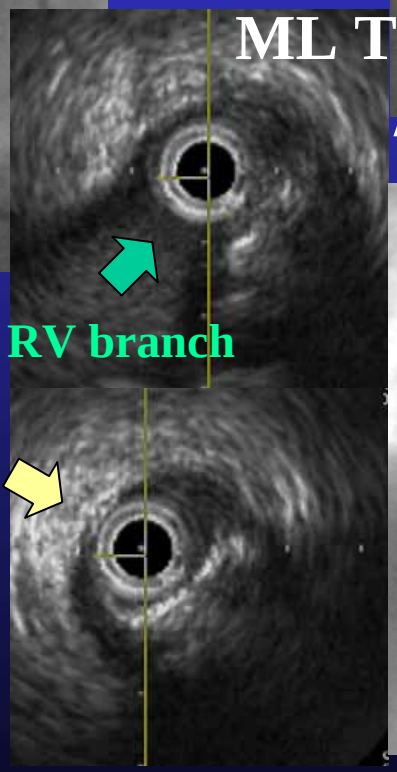

ML Tristar 4.0*23 /12atm

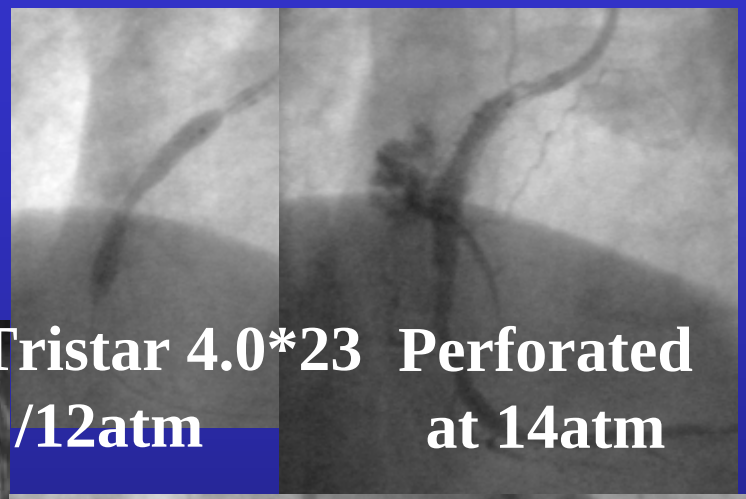

Perforated at 14atm

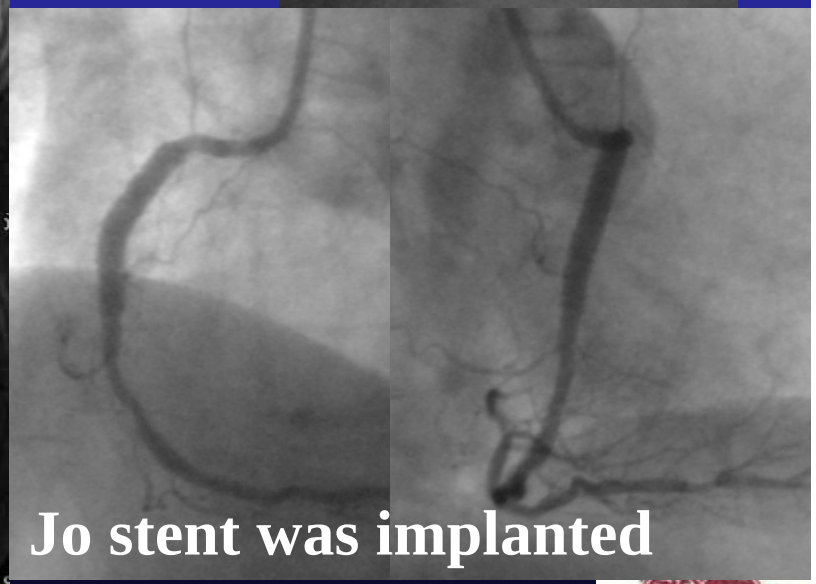

Jo stent was implanted

Courtesy S. Sumitsuji

Predictable factor - Stent Artery Ratio -

	Number	Perforation	Relative risk
<1.0	82	1	**.867**
1.0≤ <1.25	569	8	**1.000**
1.25≤ <1.5	276	10	**2.577**
1.5≤ <1.75	60	3	**3.556**
1.75≤	24	3	**8.891**

33% of perforation was occurred in Pt of SA ratio < 1.25.

MIAMI INTERNATIONAL CARDIOLOGY CONSULTANTS, INC.

Predictable IVUS Image Patterns for Perforation

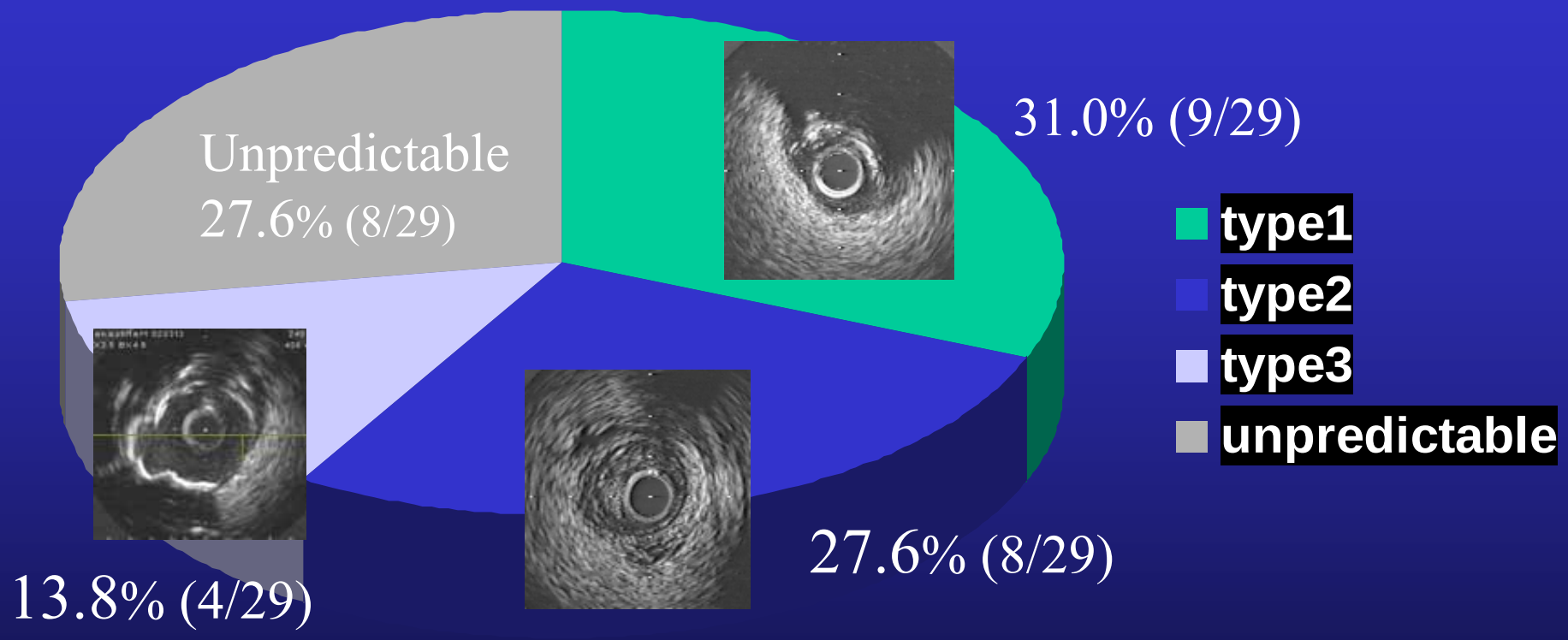

72.4% (21/29) of coronary perforation with stenting might be predicted by IVUS findings.

Courtesy S. Sumitsuji

MIAMI INTERNATIONAL CARDIOLOGY CONSULTANTS, INC.

Type II Perforation Caused by Cutting Balloon on Bend

MIAMI INTERNATIONAL CARDIOLOGY CONSULTANTS, INC.

Type II Perforation Caused by Cutting Balloon on Bend - IVUS

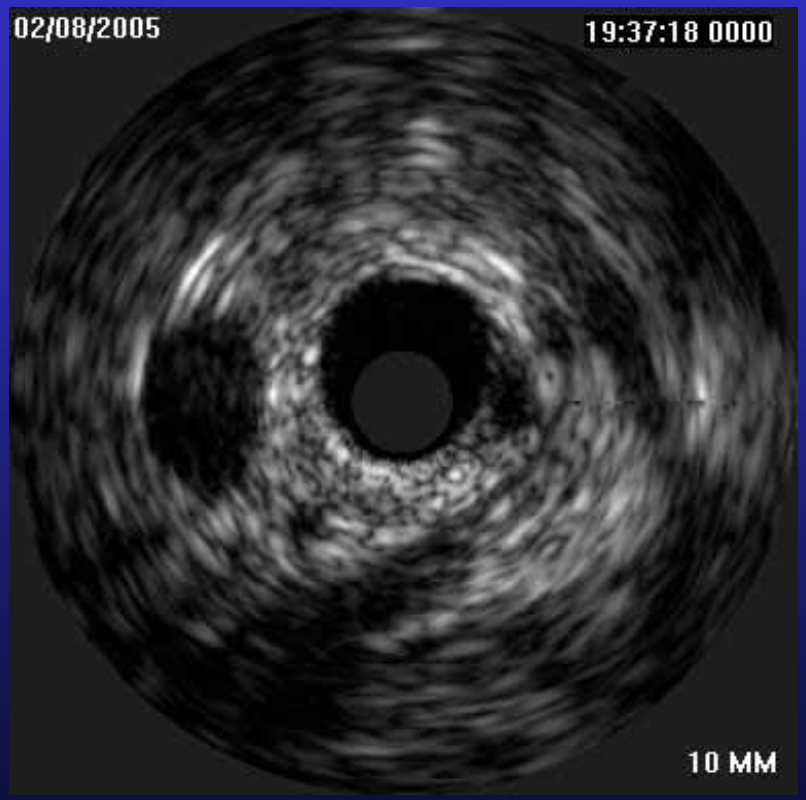

MIAMI INTERNATIONAL CARDIOLOGY CONSULTANTS, INC.

Role of Anticoagulation

- Heparin
- Low Molecular Weight Heparin
- Direct Thrombin Inhibition
- Thienopyridines
- Group IIb/IIIa Inhibition

Role of Devices

- Balloons
- Stents
- Rotablator
- Excimer Laser
- Directional Coronary Atherectomy (DCA)
- Cutting Balloon
- Devices on Bends and At Bifurcations

Type I Perforation Caused by Rotablator

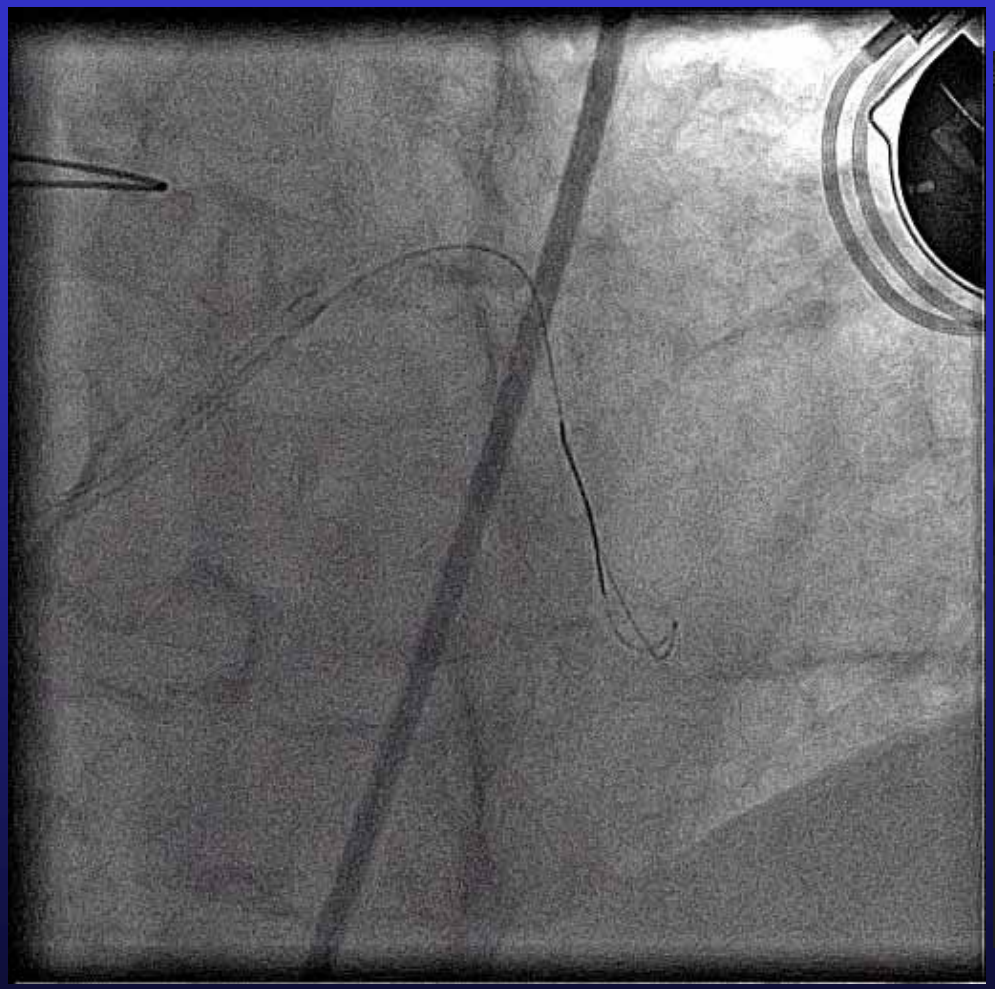

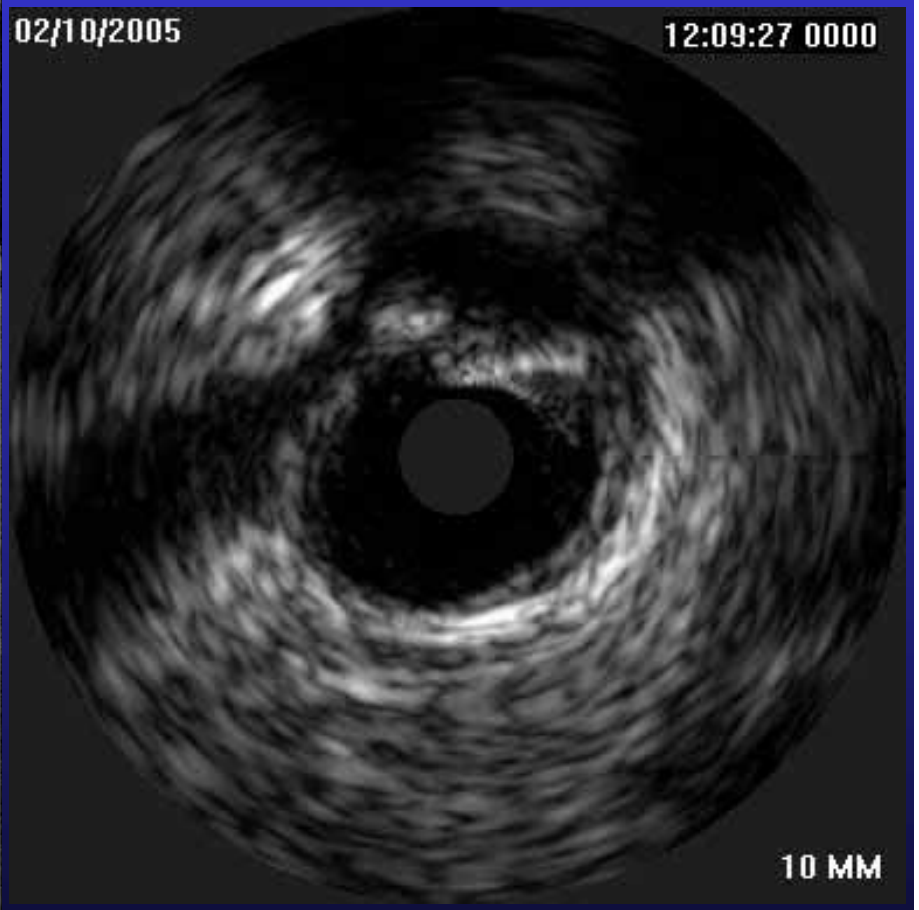

MIAMI INTERNATIONAL CARDIOLOGY CONSULTANTS, INC.

Role of Stenting

- Overaggressive stenting is an increasingly common cause of perforation.
- DO NOT stent a perforation caused by a balloon.
  - Bare stents rarely solve the problem.
  - They usually make it worse.
- Covered stents have revolutionized the treatment of perforation.
- Drawbacks of covered stents are:
  - Require large bore guiding catheters
  - Difficult to deploy
  - High restenosis rate

MIAMI INTERNATIONAL CARDIOLOGY CONSULTANTS, INC.

Prevention

- Most perforations are preventable.
- Operators must be constantly cognizant of high-risk situations.
- Properly prepare arteries prior to stenting.
- If an artery cannot be properly prepared, stents should not be used.
- Avoid over-sizing.
  - In high-risk situations, devices, balloons and stents should be slightly undersized.
- Routine IVUS use is integral to each of these disciplines.
- Guidewire perforations are best prevented by:
  - using hydrophilic wires only when necessary.
  - exchanging these wires for conventional wires whenever possible.
  - being constantly aware of the potential for guidewire perforation in long complex cases.

MIAMI INTERNATIONAL CARDIOLOGY CONSULTANTS, INC.

Management - I

- Coronary perforation is an emergency.
  - Mortality in type III perforations (large perforations with a jet of contrast) is 19%.
  - When pericardial tamponade occurs, mortality is 42%.
- Appropriate action in the first minute can prevent the occurrence of tamponade.
- Balloons are the single most important piece of equipment for the emergency management of perforation.
  - Balloons are used to temporarily seal the hole while other more definitive measures are prepared.
  - Even in patients who become abruptly hypotensive, sealing the hole will frequently stabilize blood pressure without concomitant pericardiocentesis or fluid administration.

MIAMI INTERNATIONAL CARDIOLOGY CONSULTANTS, INC.

Management - II

- Pericardiocentesis is not infrequently necessary to stabilize blood pressure and preserve cardiac output.
  - Materials for pericardiocentesis must be immediately available.
- Reversal of anticoagulation is a mainstay of the treatment of perforation.
  - Sometimes this is the only necessary treatment.
  - Satisfactory reversal of anticoagulation is best determined by return of ACT to normal.
- Covered stents are the definitive treatment for coronary artery perforation.

MIAMI INTERNATIONAL CARDIOLOGY CONSULTANTS, INC.

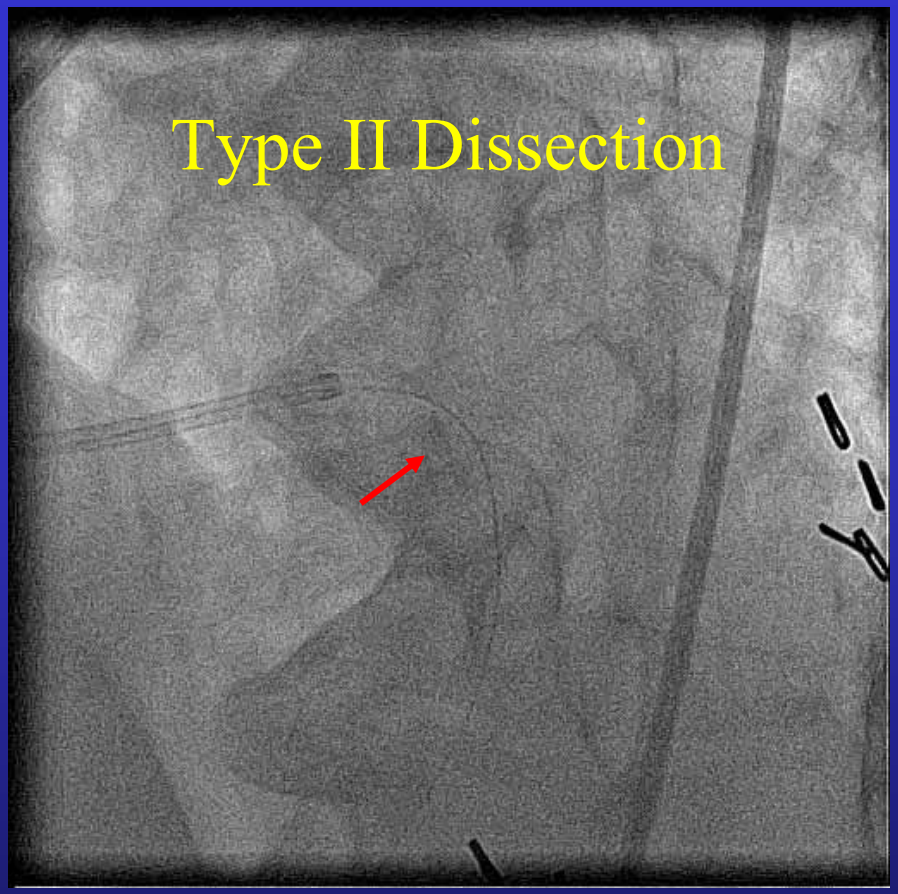

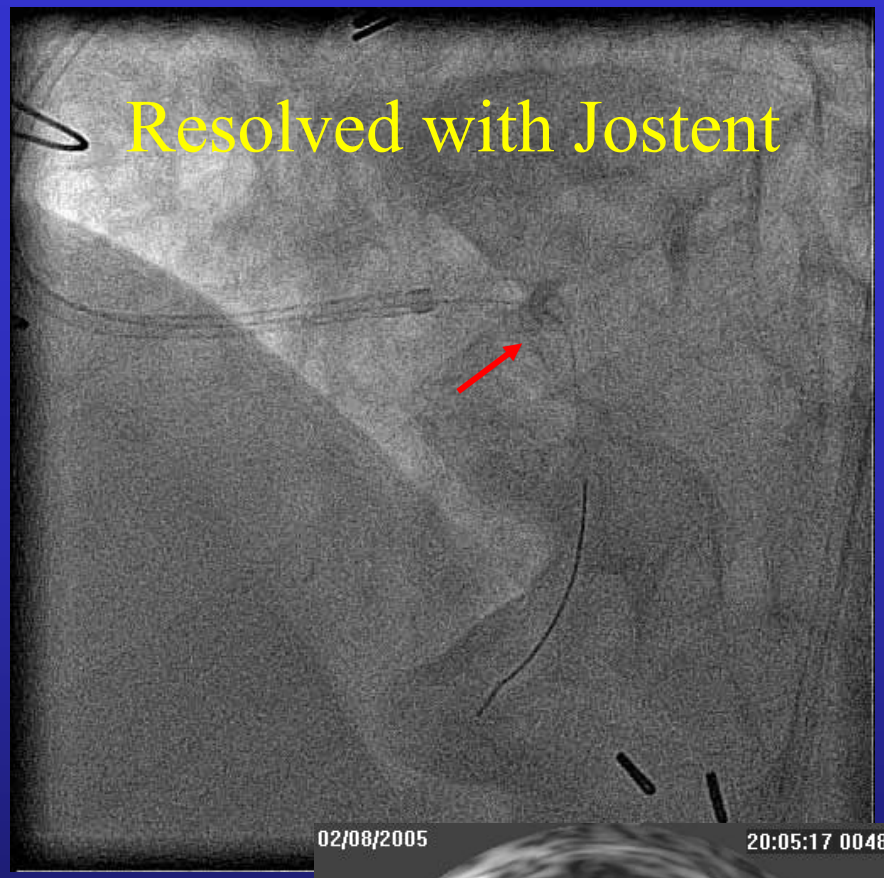

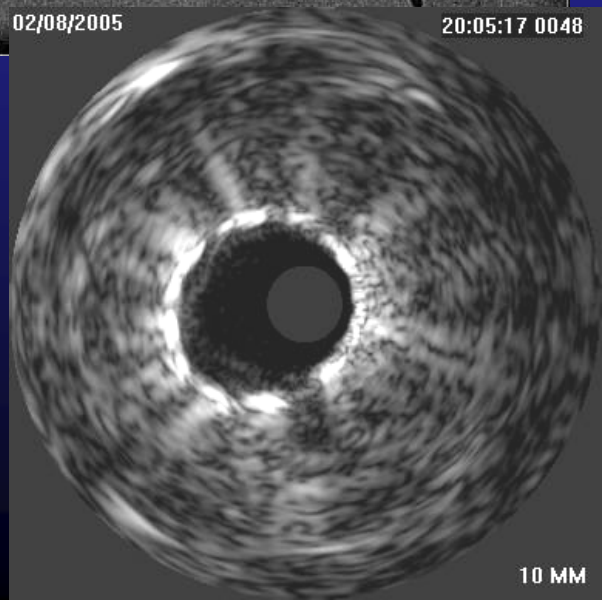

Covered Stents

Role of Surgery

- Some coronary perforations cannot be solved in the cath lab.
- Sometimes it is better to stabilize the patient with balloon tamponade of the perforation with or without pericardiocentesis, and then take the patient to surgery.
- It is essential that the patient not be taken to surgery while still actively bleeding into the pericardium.
- Surgical mortality is high in these very sick patients – 18% in one large series.
- All medical efforts to solve the problem should be exhausted before sending a patient to surgery.
- Exceptions to this caveat:
  - Bifurcation lesions where covered stenting will sacrifice one or more large side branches
  - Perforations that involve the aorta.

MIAMI INTERNATIONAL CARDIOLOGY CONSULTANTS, INC.

Distal Injection of Thrombin Can Solve Guidewire Perforations

Type II leak resumes within few minutes post prolonged balloon inflation.

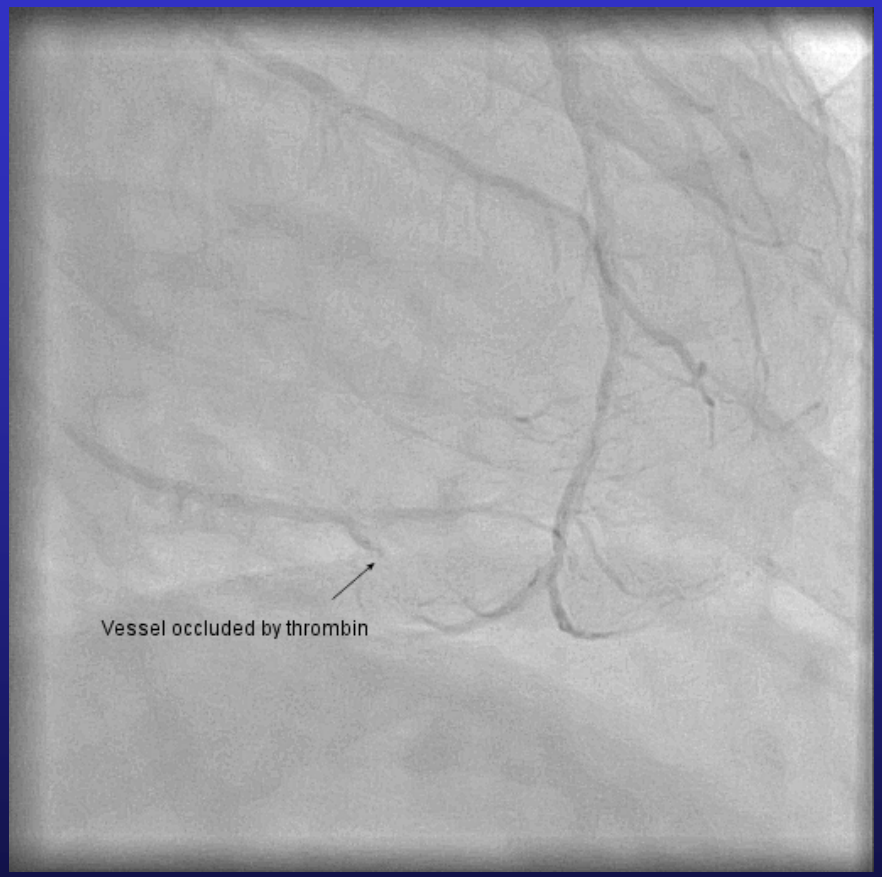

Post thrombin perforation is sealed without interrupting flow to other branches.

MIAMI INTERNATIONAL CARDIOLOGY CONSULTANTS, INC.

Treatment Algorithm

- Recognize perforation immediately.
  - Do not ignore small perforations.
- Stay cool.
- Do not lose guidewire position.
- Tamponade leak with a balloon.
- Reverse anticoagulation.
- Solve the problem.
  - Prolonged balloon inflation
  - Covered stent
  - Coils
  - Thrombin Injection
  - Surgery

MIAMI INTERNATIONAL CARDIOLOGY CONSULTANTS, INC.

Summary

- Best treatment of perforations is prevention.
  - Recognize high risk anatomy.
  - Do not oversize balloons and stents.
  - Be particularly cautious with eccentric lesions
  - Use devices cautiously
  - Assess lesions with IVUS before treating.
- Know how to recognize and treat perforation when it occurs.
  - Never lose wire position.
  - Tamponade perforation with a balloon while you decide what next to do.
  - Stay Cool.

MIAMI INTERNATIONAL CARDIOLOGY CONSULTANTS, INC.