

YARON ALMAGOR, MD

Director, Interventional Cardiology



Shaare Zedek Medical Center

Jerusalem, Israel

TCTAP, Seoul, April 2015

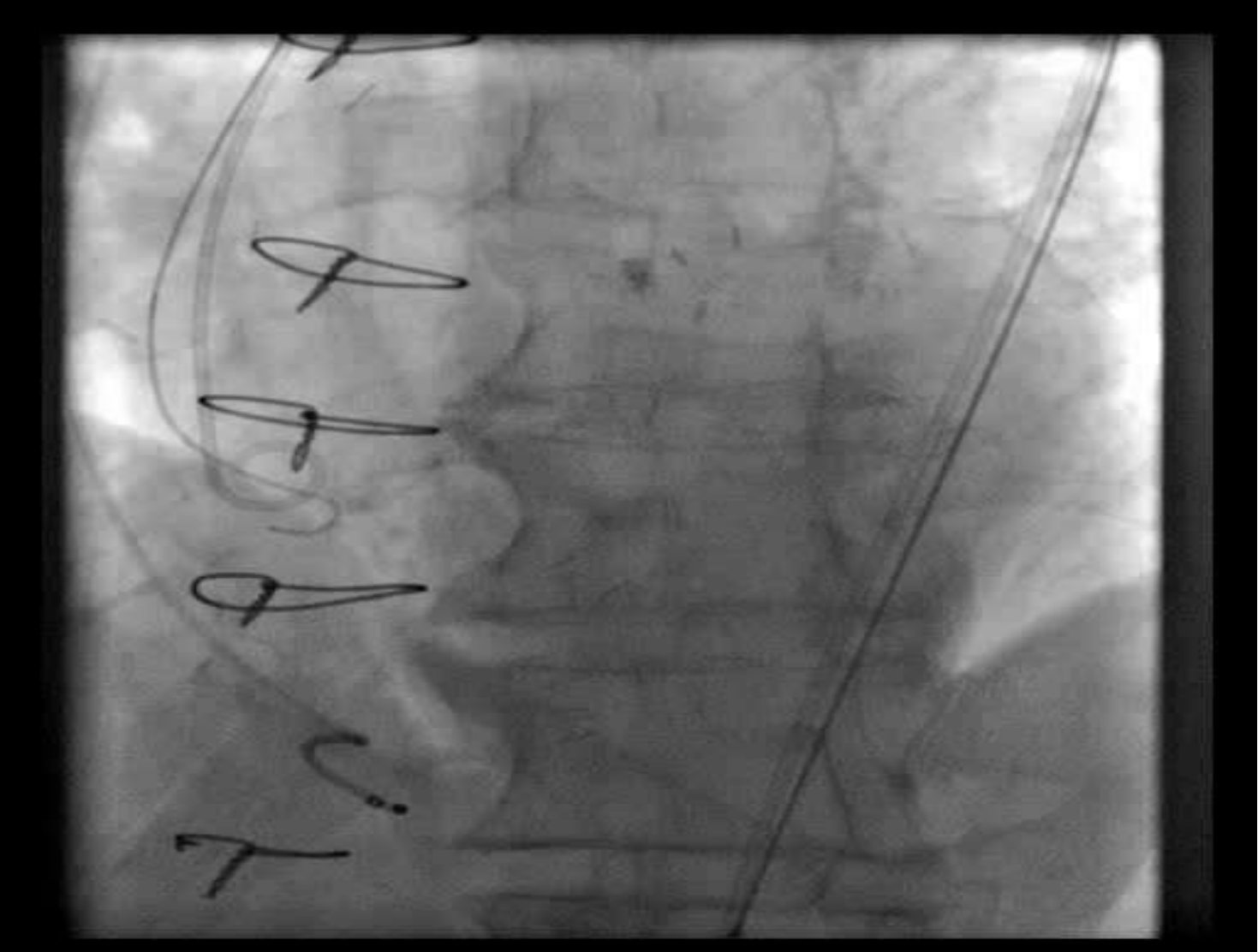
How a Nightmare During TAVI Resulted in Life-Saving for the Patient

Patient Demographics:

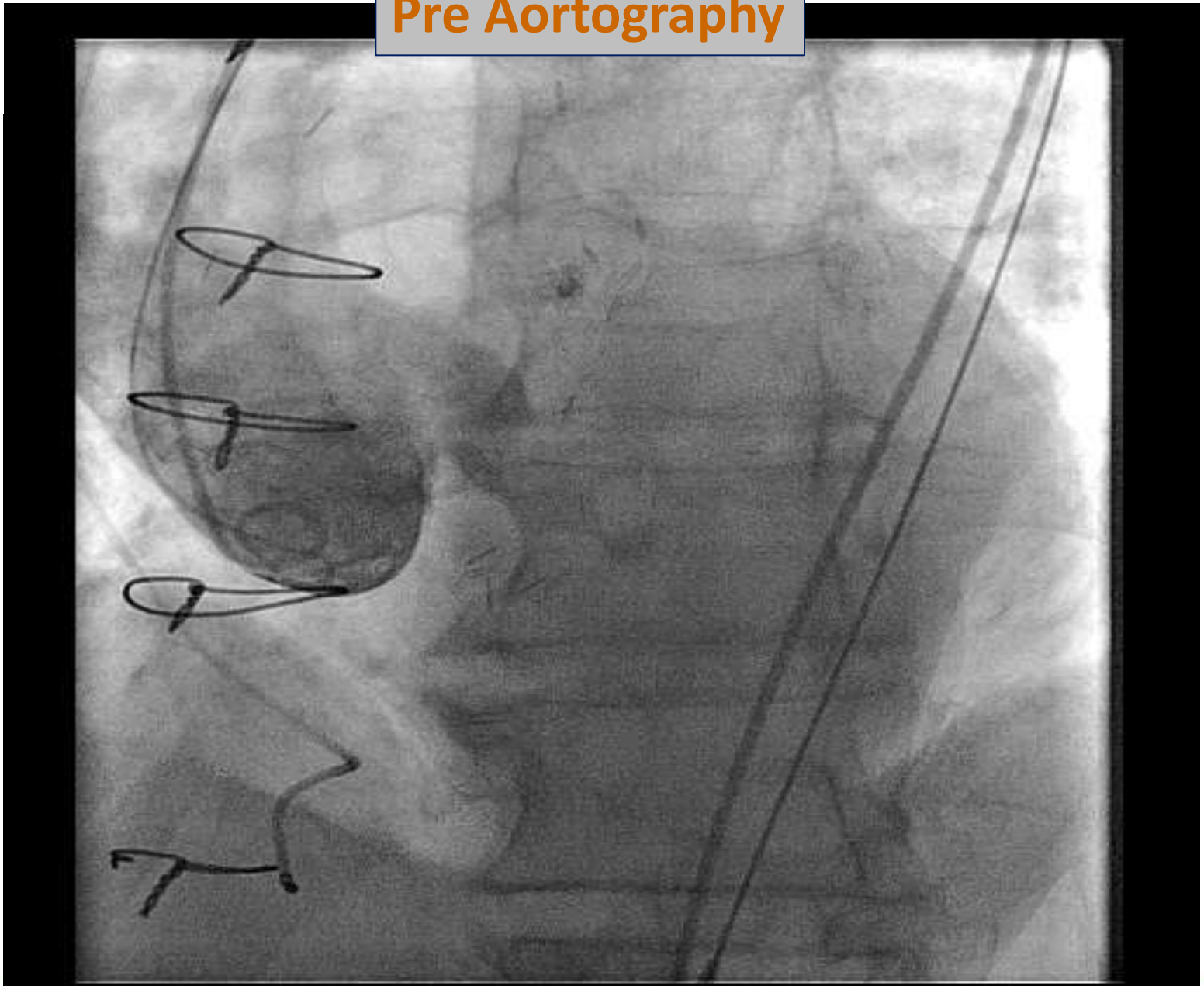
- ♥ Male, 78y
- ♥ Severe Aortic Stenosis
- ♥ S/P CABG 2003
- ♥ Congestive Heart Failure
- ♥ Hypertension
- ♥ Hypercholesterolemia
- ♥ Smoker
- ♥ LV Moderately impaired
- ♥ EuroScore 28

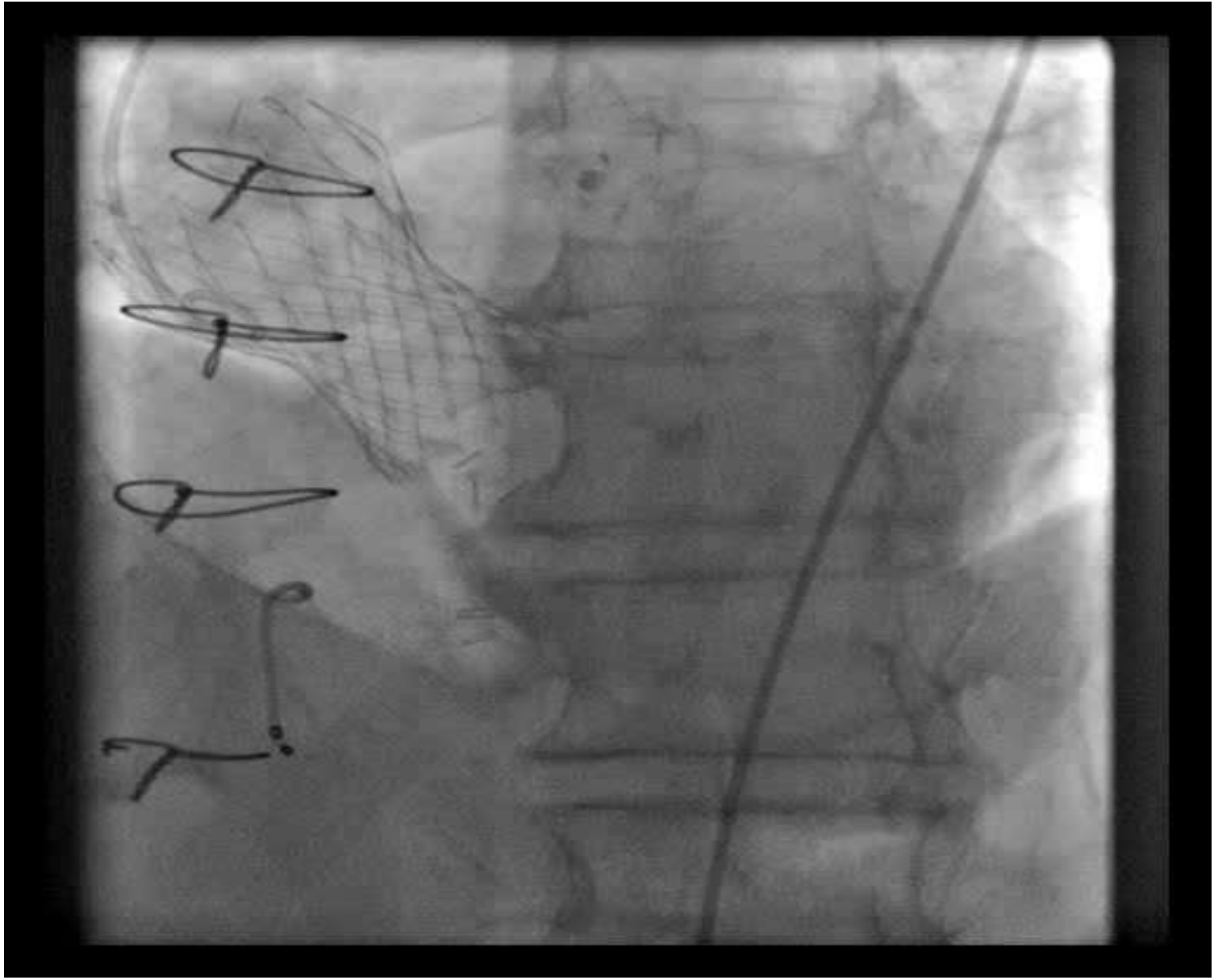
Procedure:

- ♥ Annulus (Hinge point): 27mm
- ♥ TF implantation of 31mm CoreValve resulted in acute severe paravalvular AI
- ♥ Patient went into cardiogenic shock
- ♥ Post deployment balloon valvuloplasty resulted in...

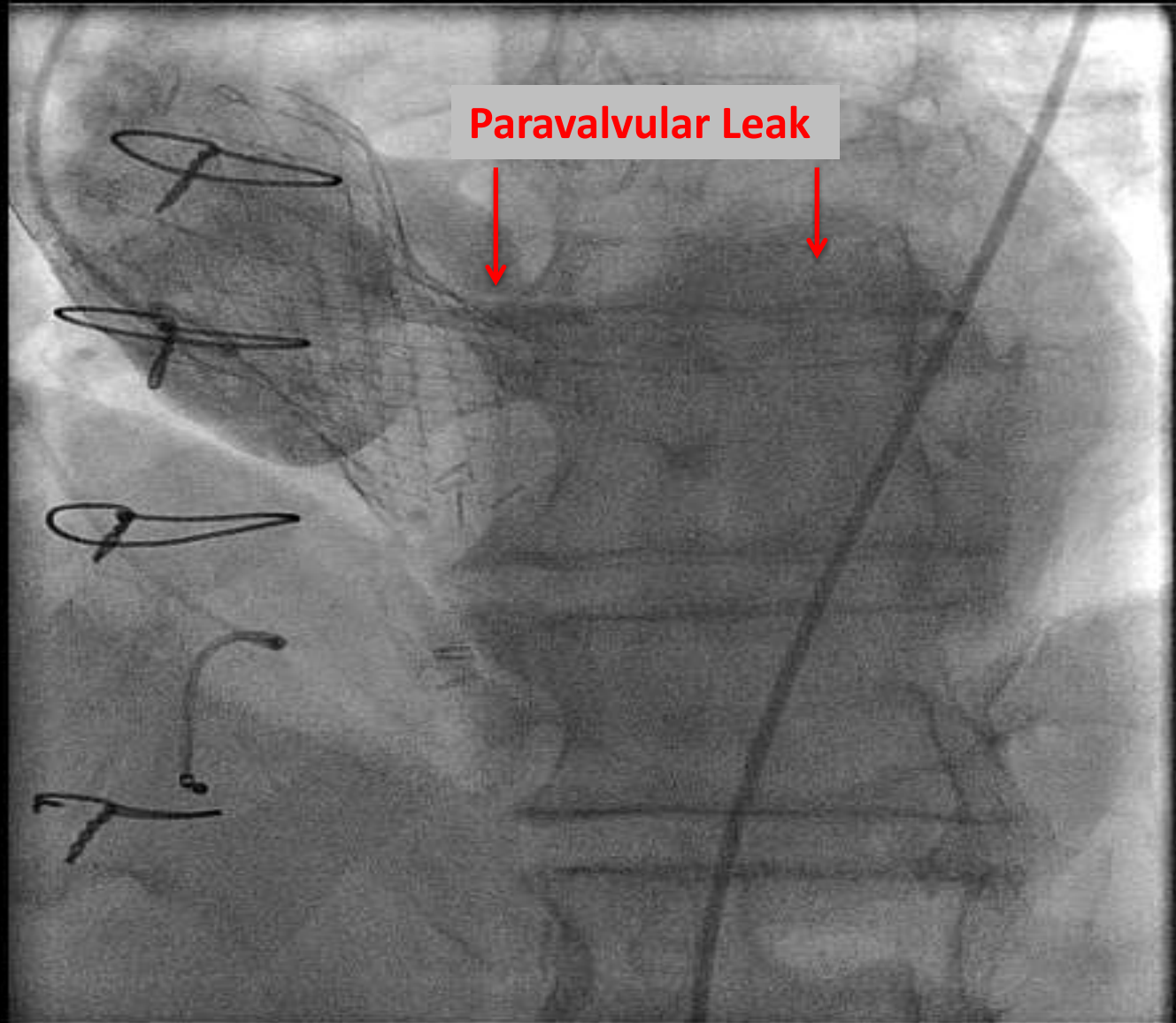


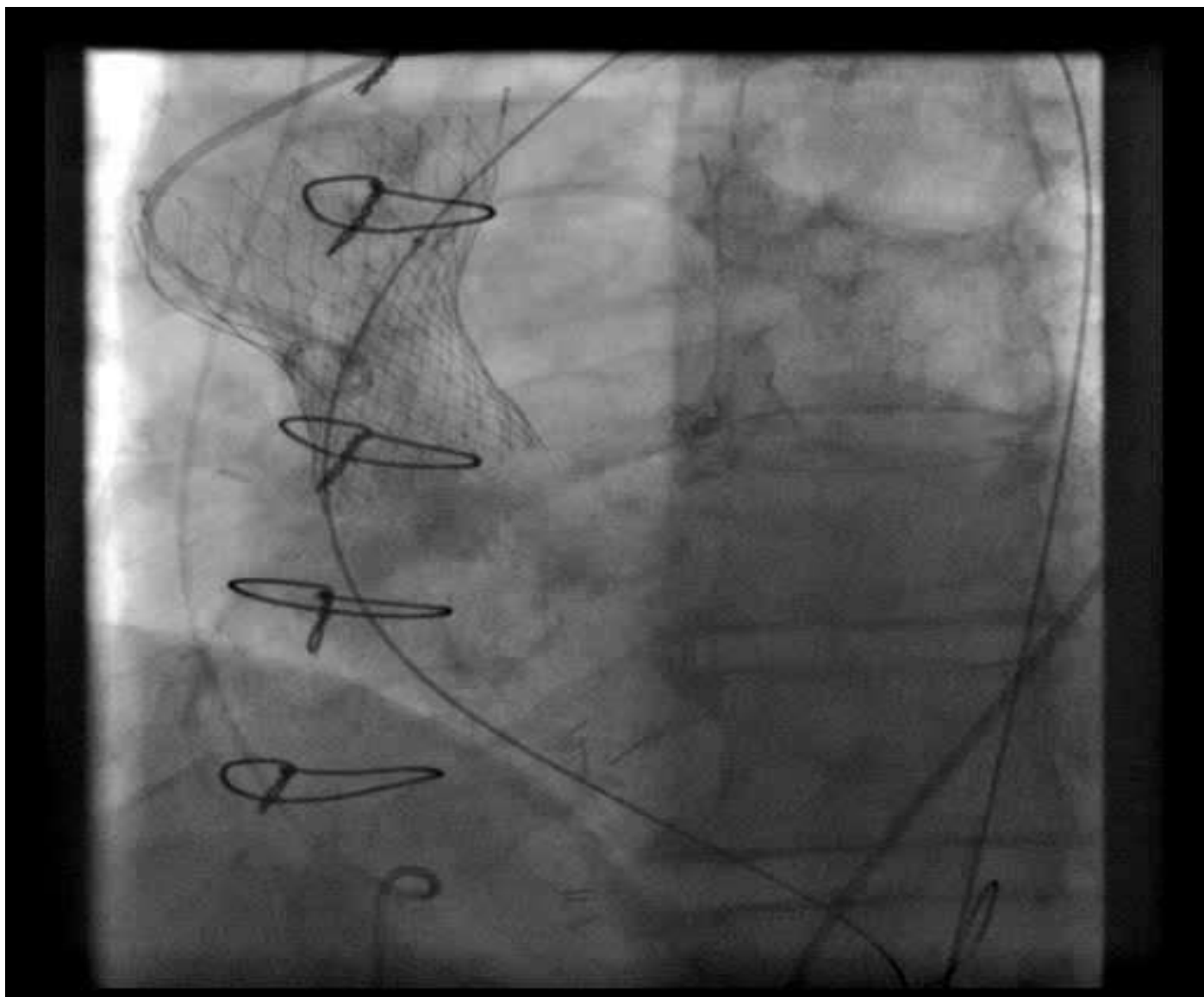
Pre Aortography



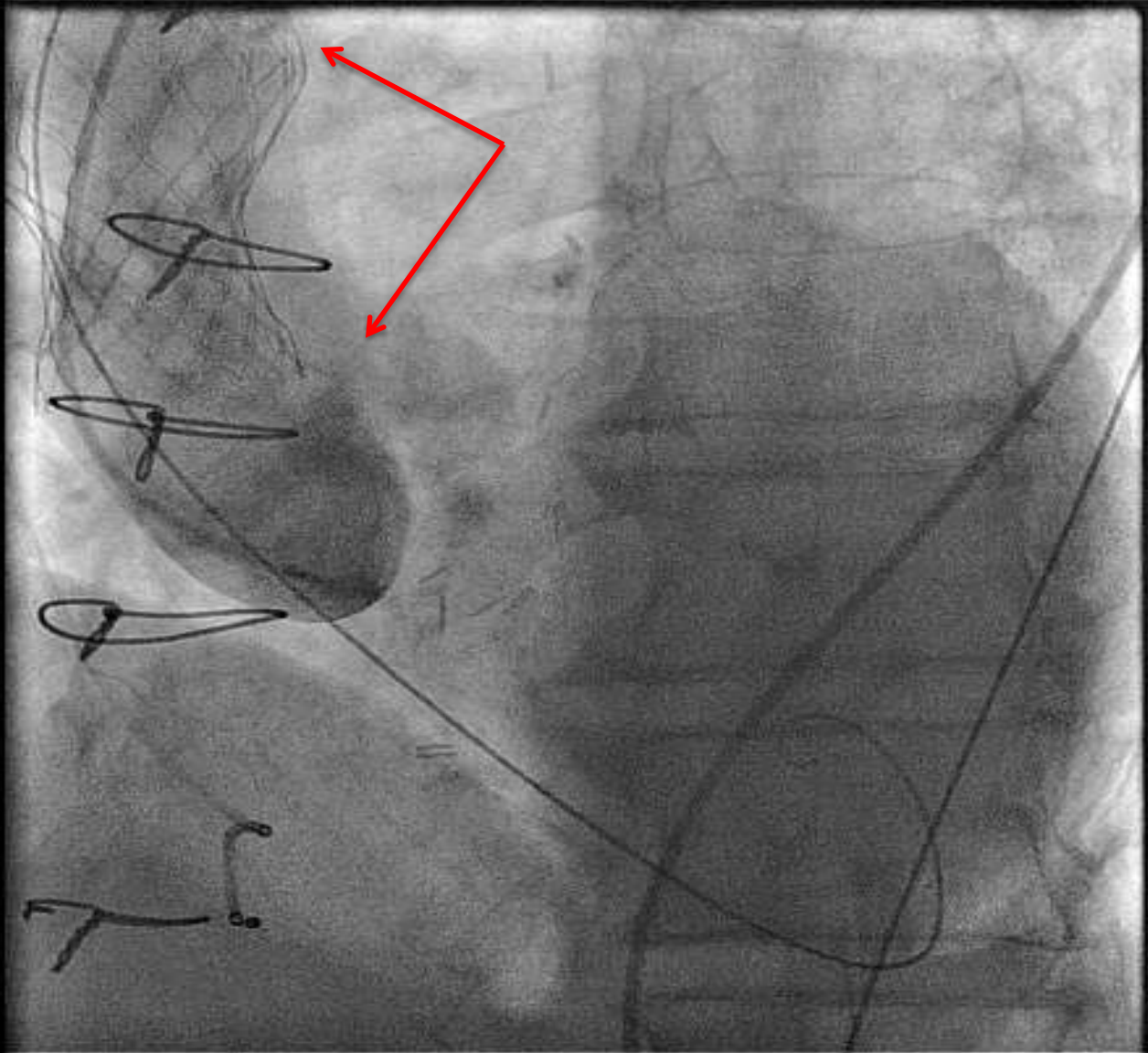


Post Deployment

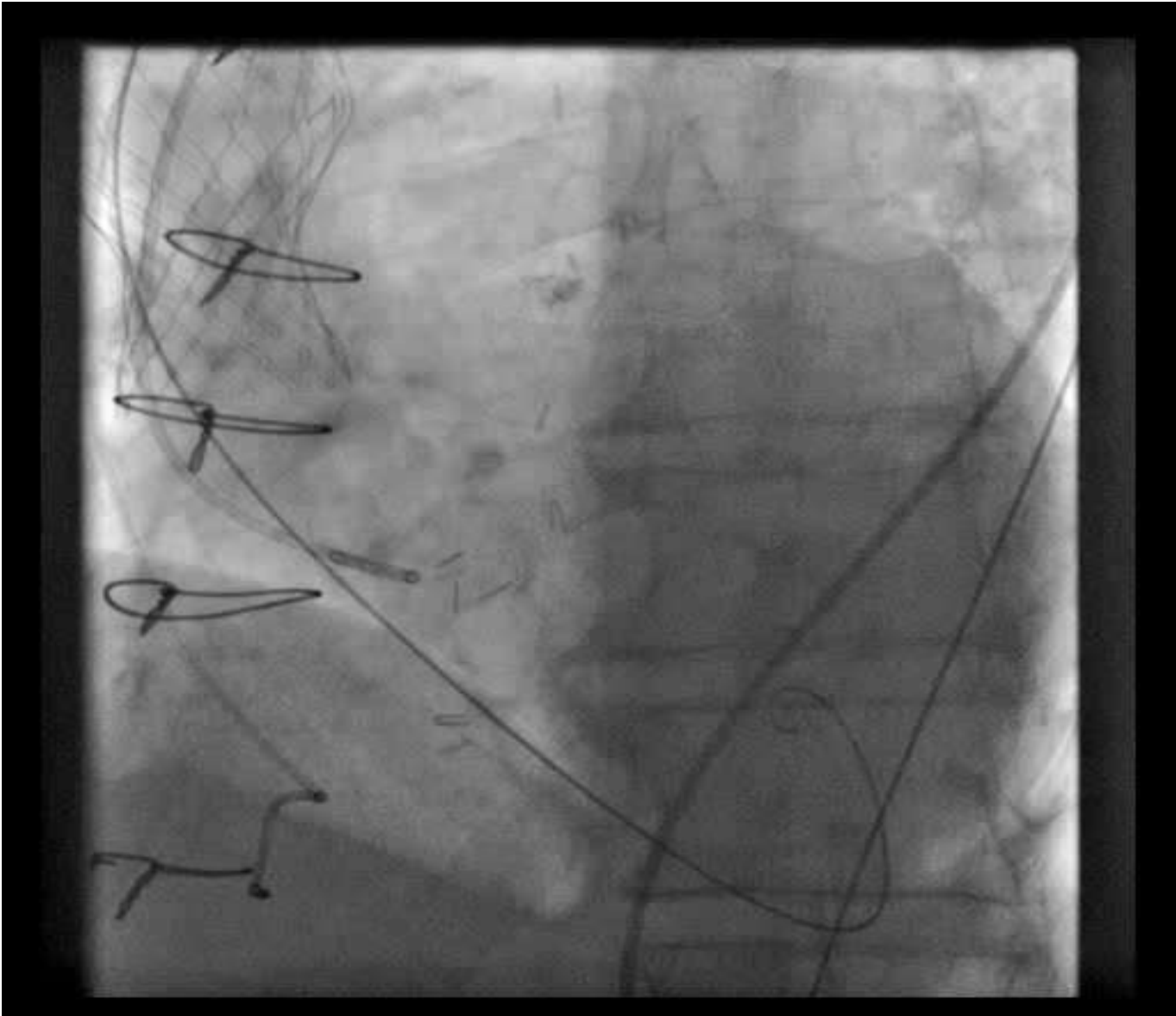



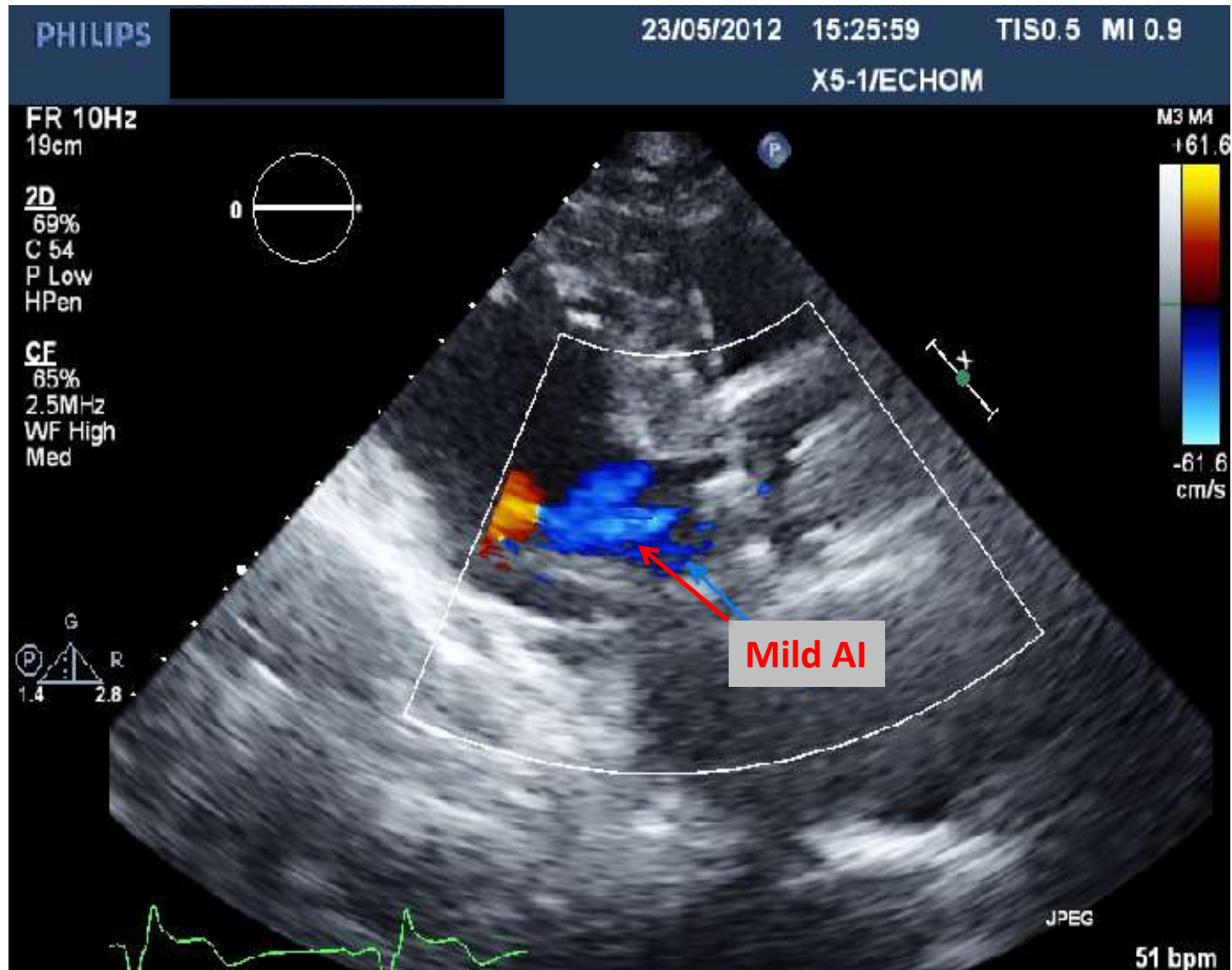
Valve Dislodgement



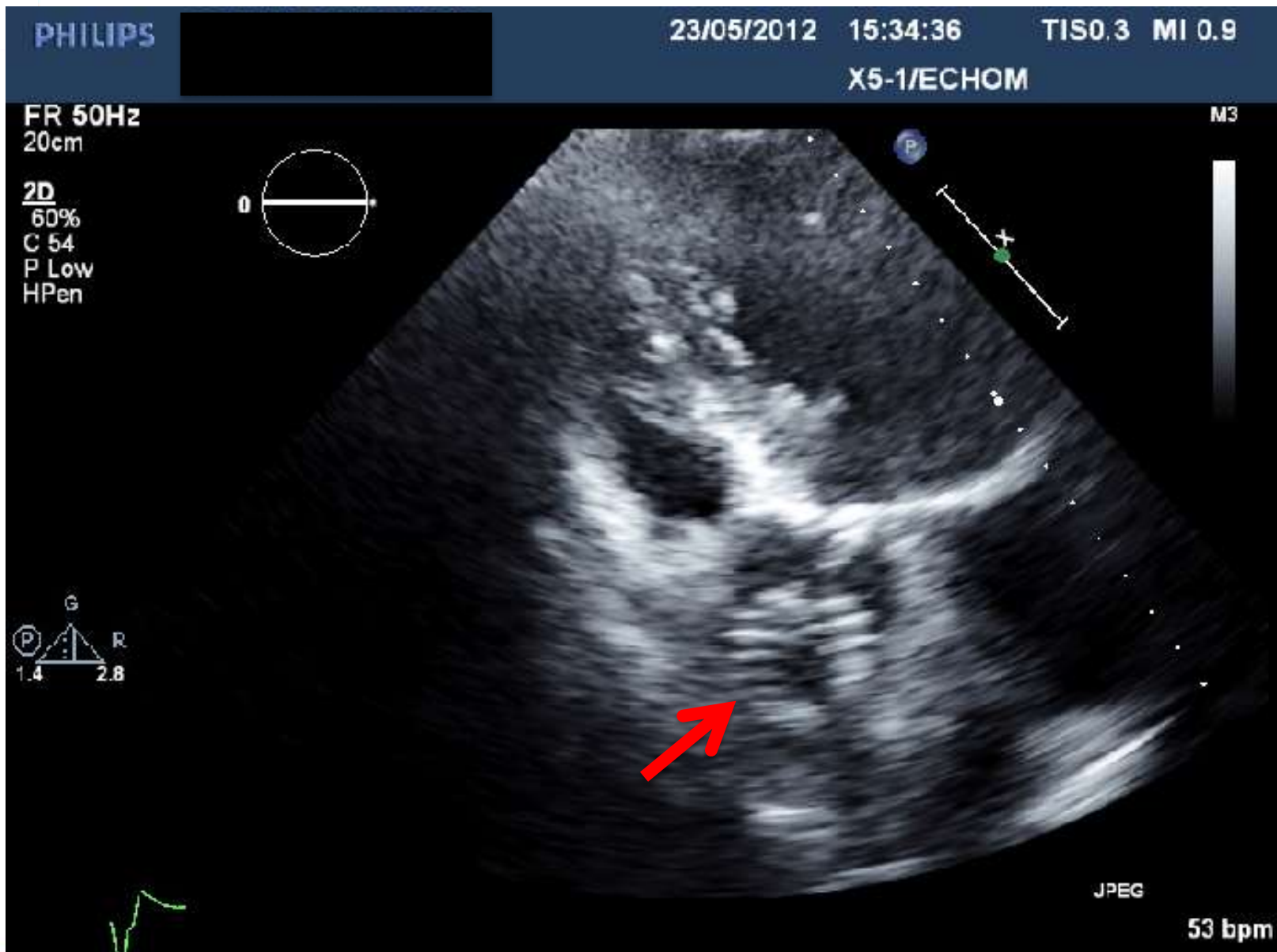
- ♥ CoreValve dislodgement into ascending aorta, which produced immediate clinical improvement and resolution of acute paravalvular leak
- ♥ Hemodynamic measurements post-procedure: no gradient across the valve, mild AI
- ♥ Patient discharged on Day 3 in stable cardiac condition



Echocardiography Post Procedure



CoreValve in Ascending Aorta



6 Month Follow-Up

♥ Stable clinical condition

♥ Echo = moderate AS