



TCTAP 2014, Korea

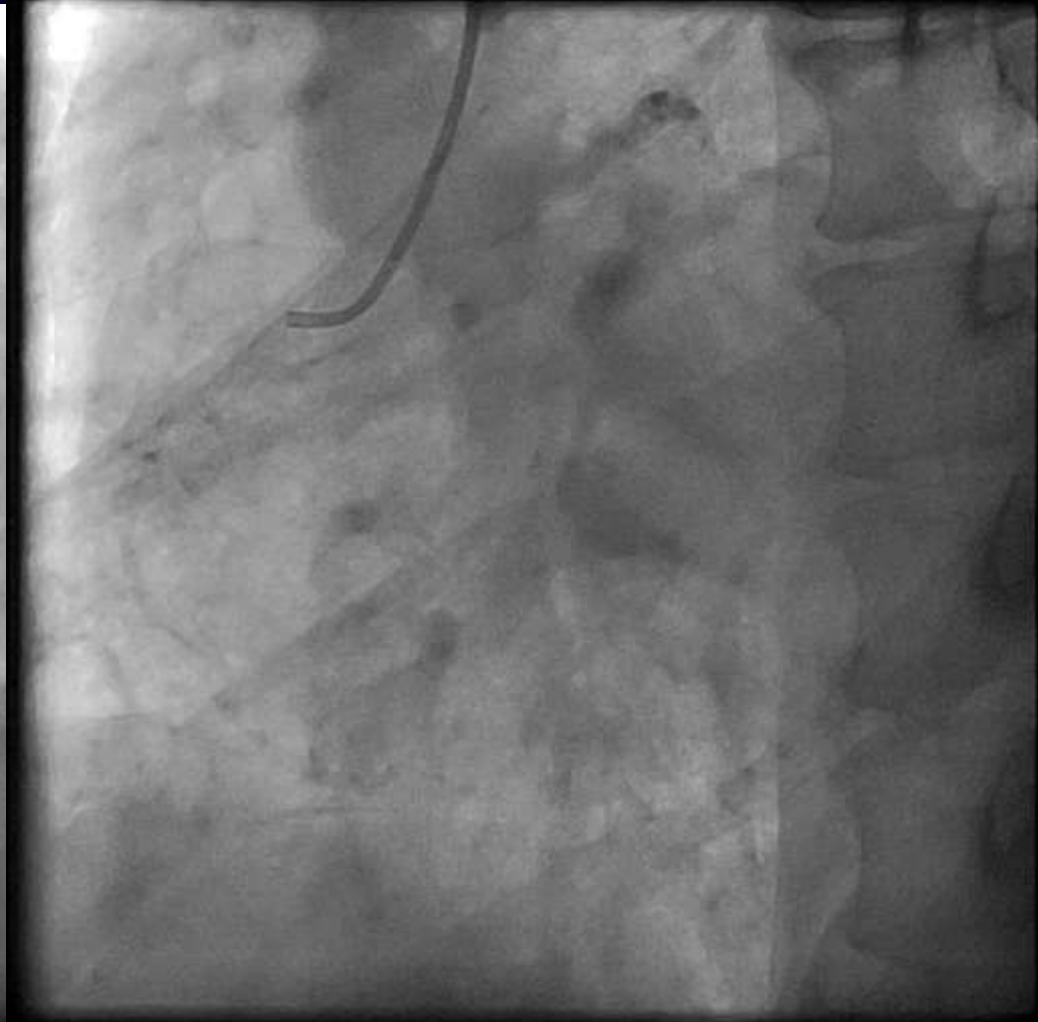
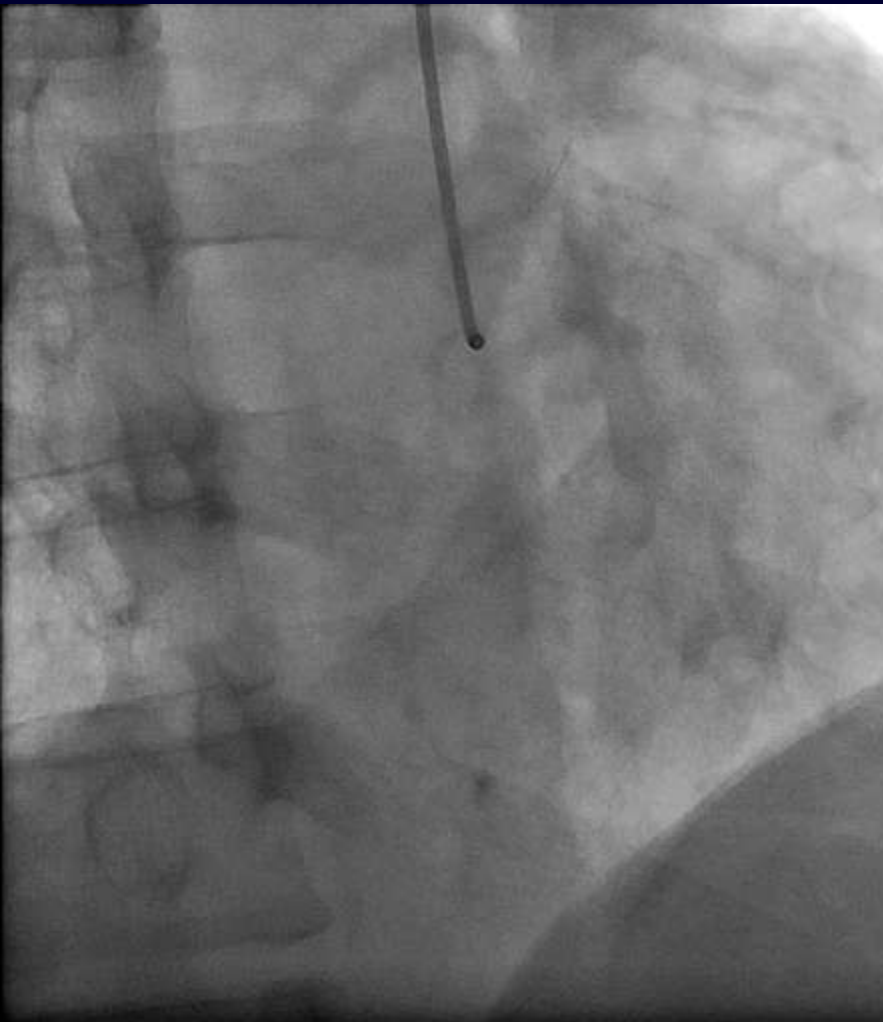
# **“I Did IT, My Friend Fixed It”**

***Wasan Udayachalerm, MD, FAPSC***

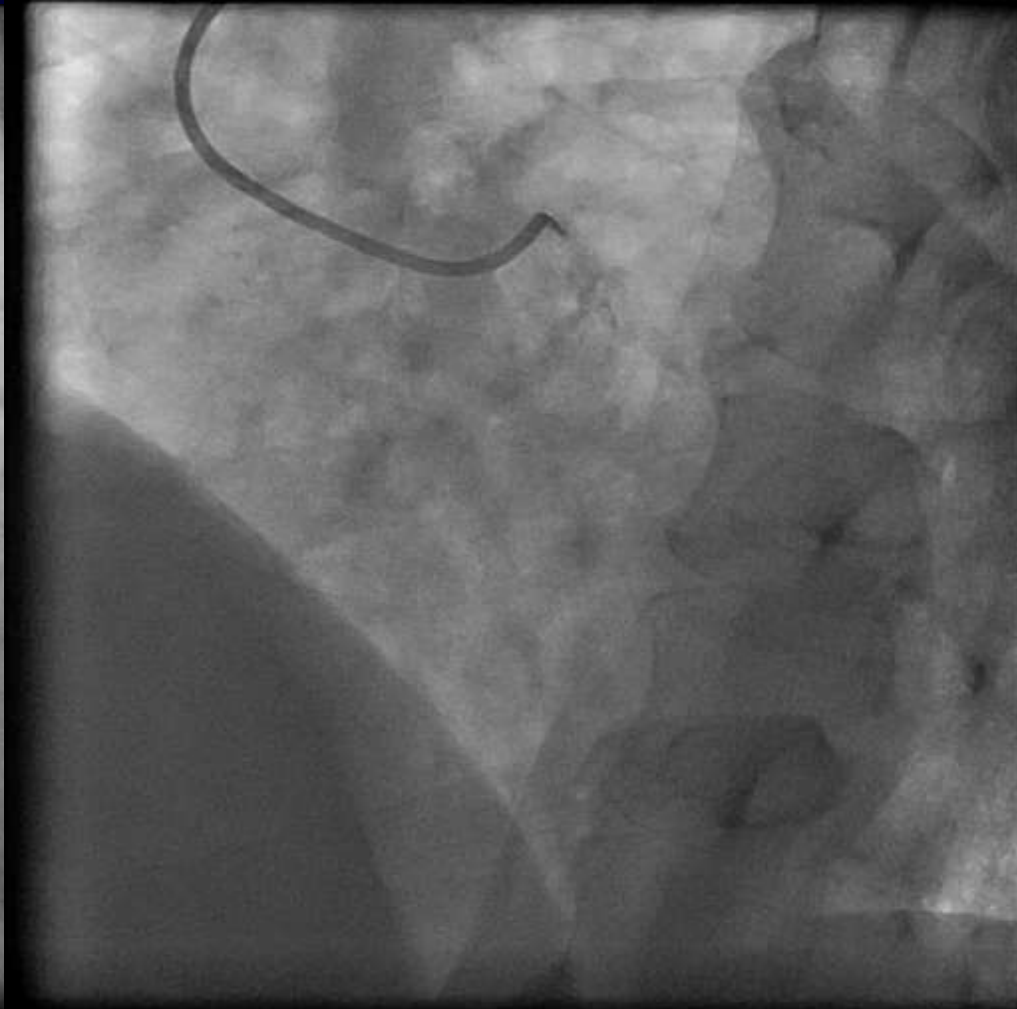
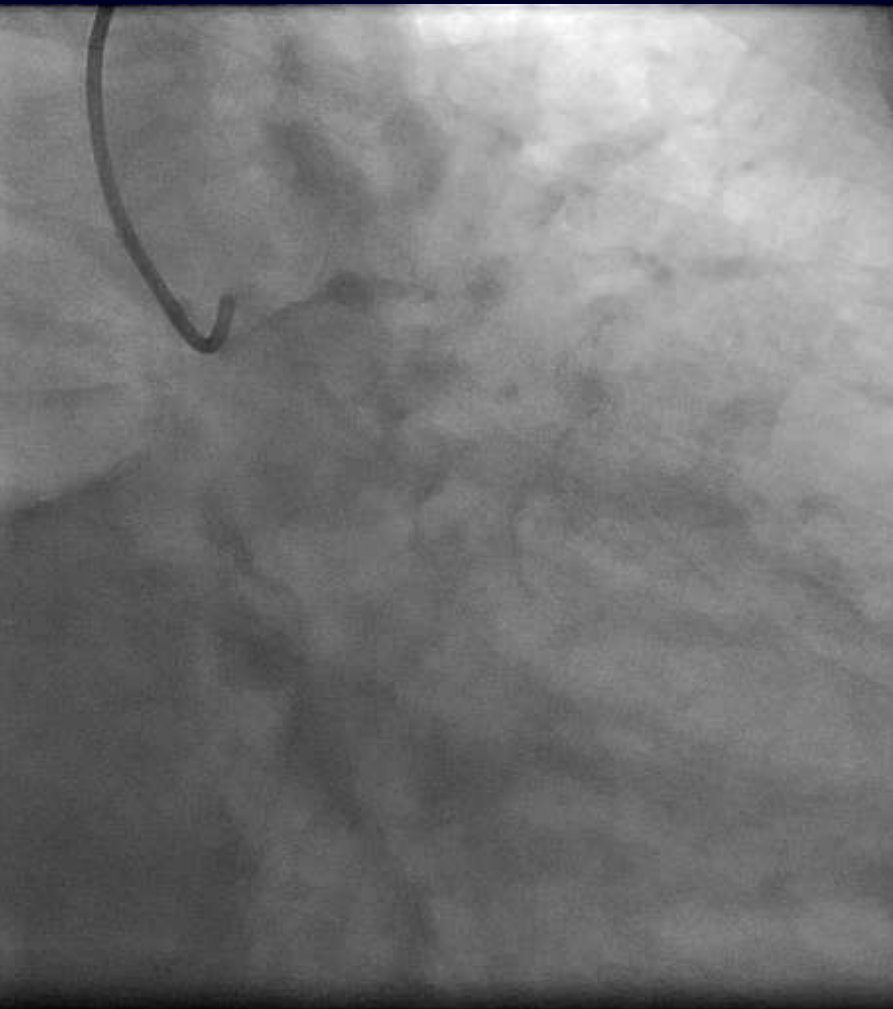**Cardiac center**

**King Chulalongkorn Memorial Hospital**

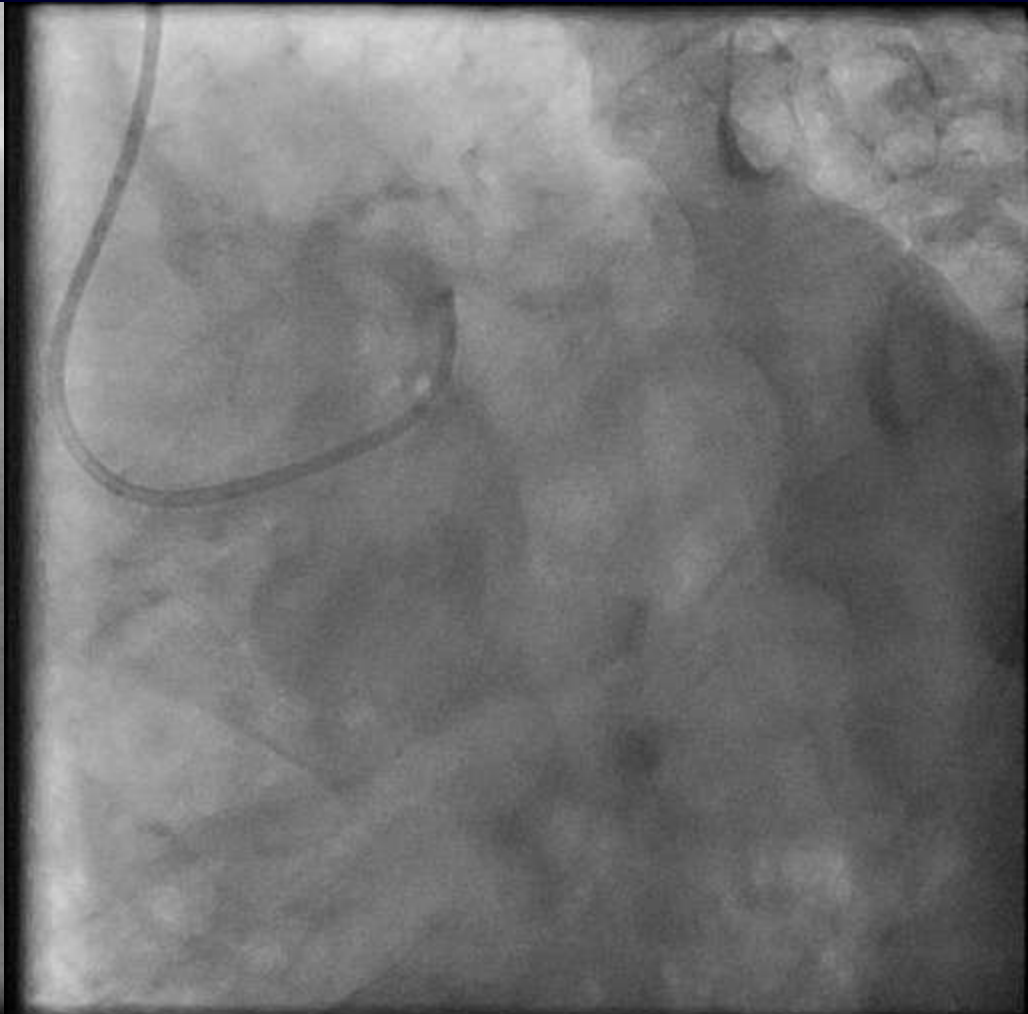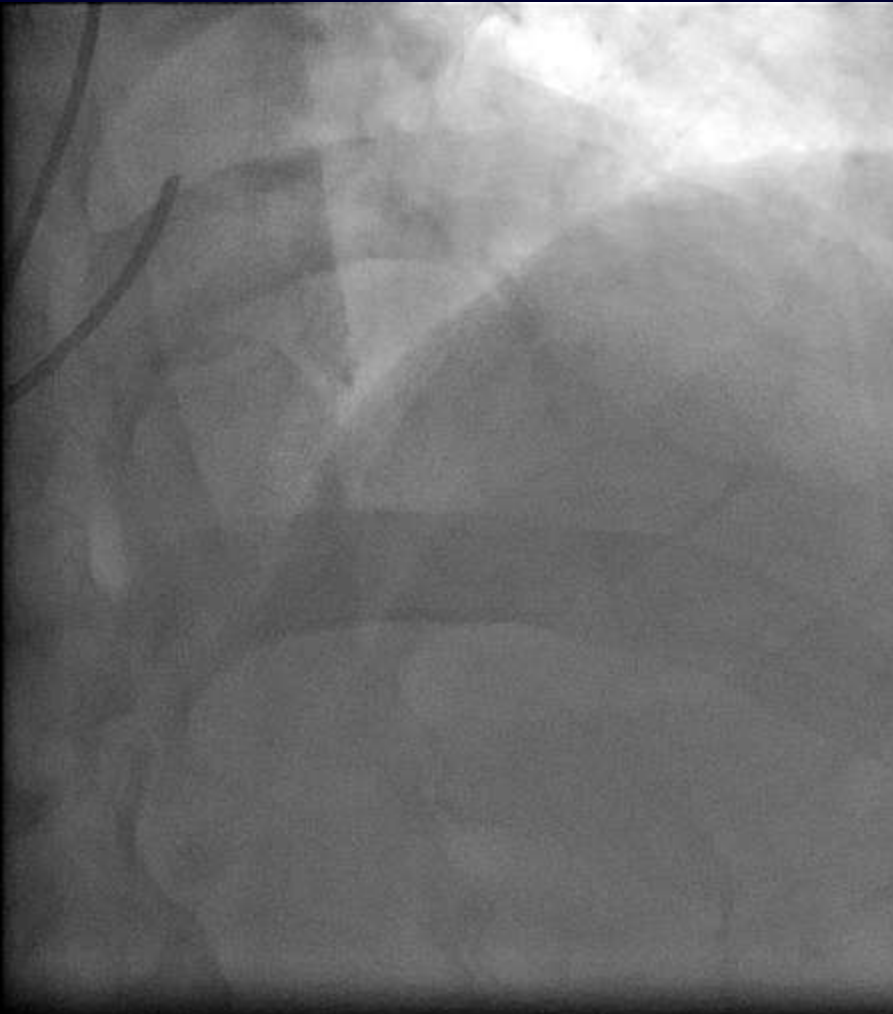
**A 50 y/o singaporean male, with HTN & DLP presented with angina and positive EST at low work load**



# LCA



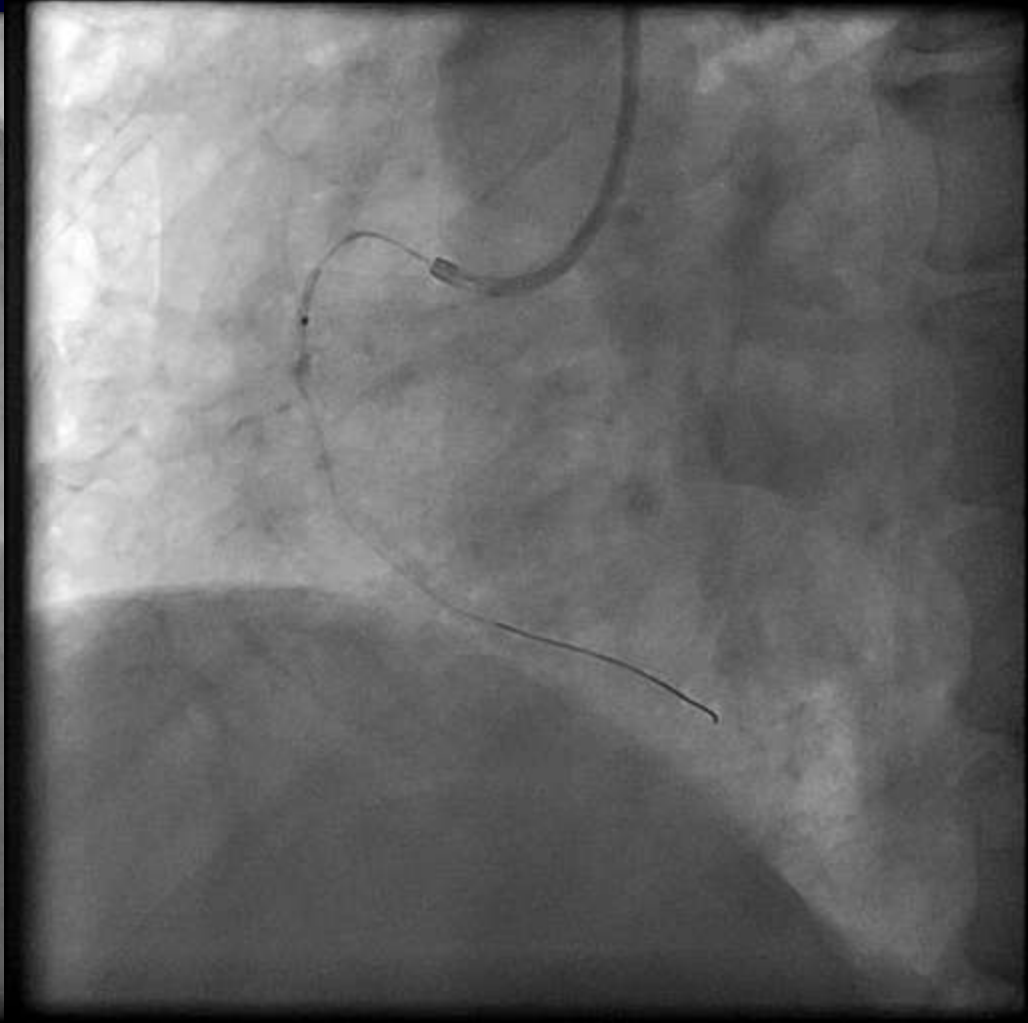
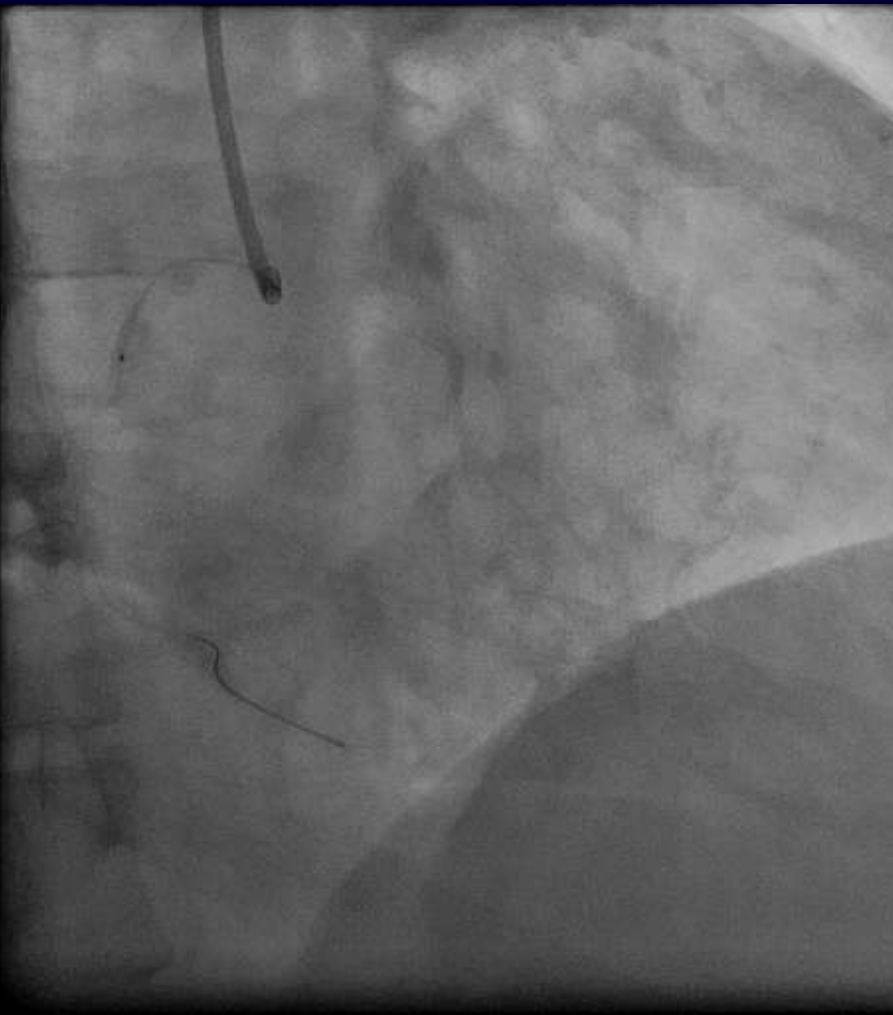
# LCA



# What is your choice for treating this patient?

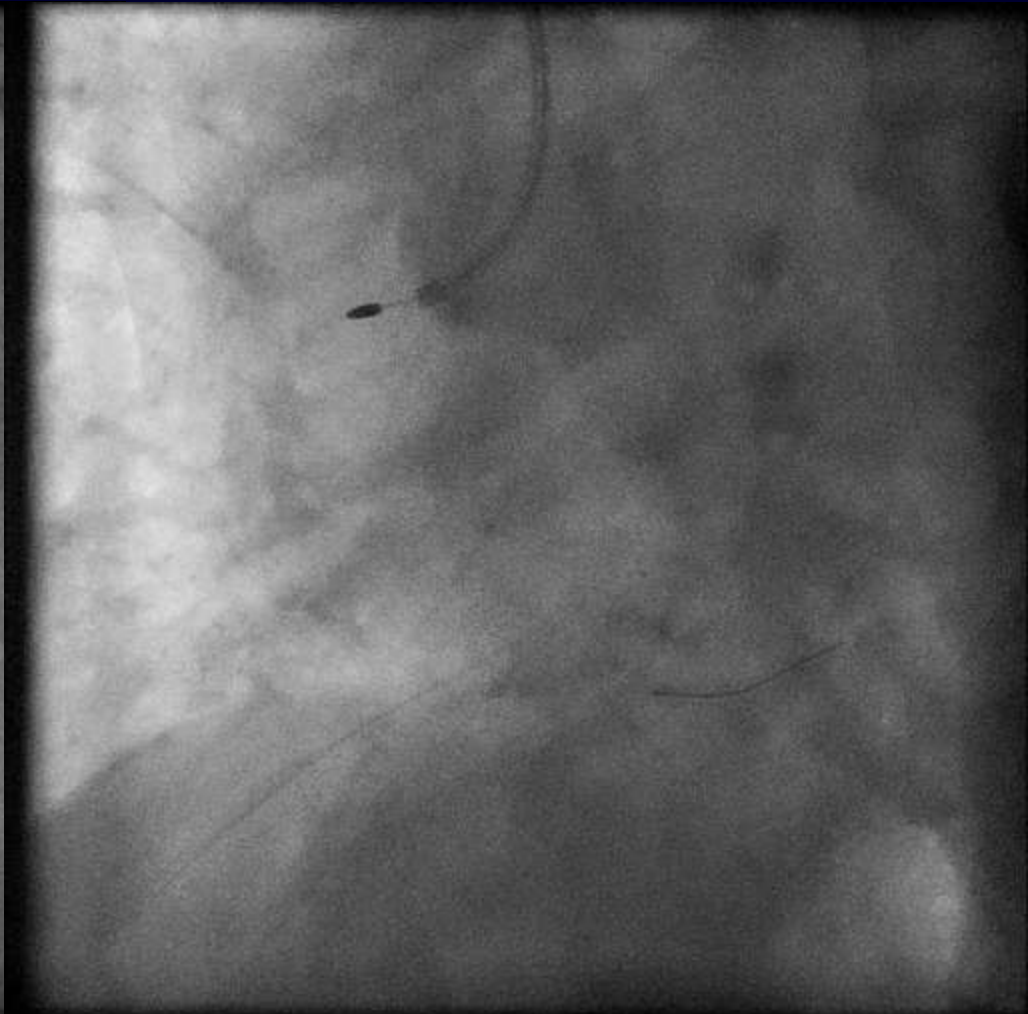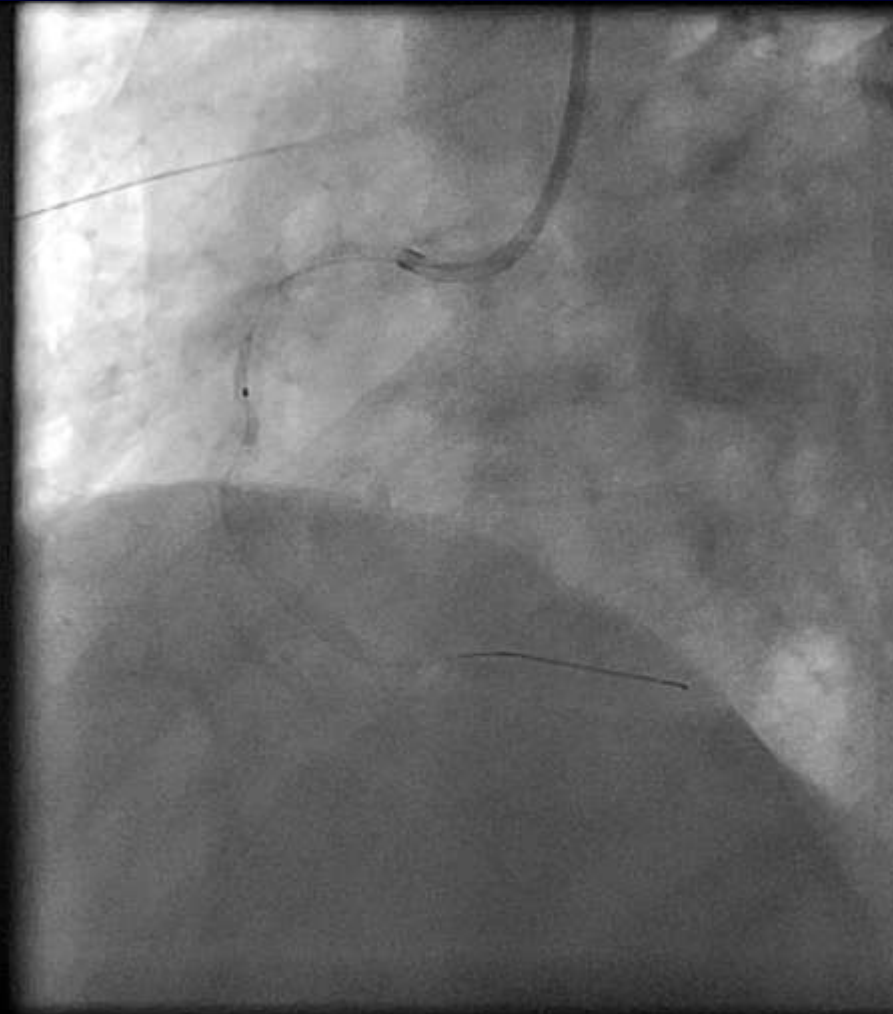
- A. CABG
- B. PCI in all 3 vessels
- C. Aggressive medical treatment
- D. Hybrid procedure
- E. Send to another operator

# RCA PCI

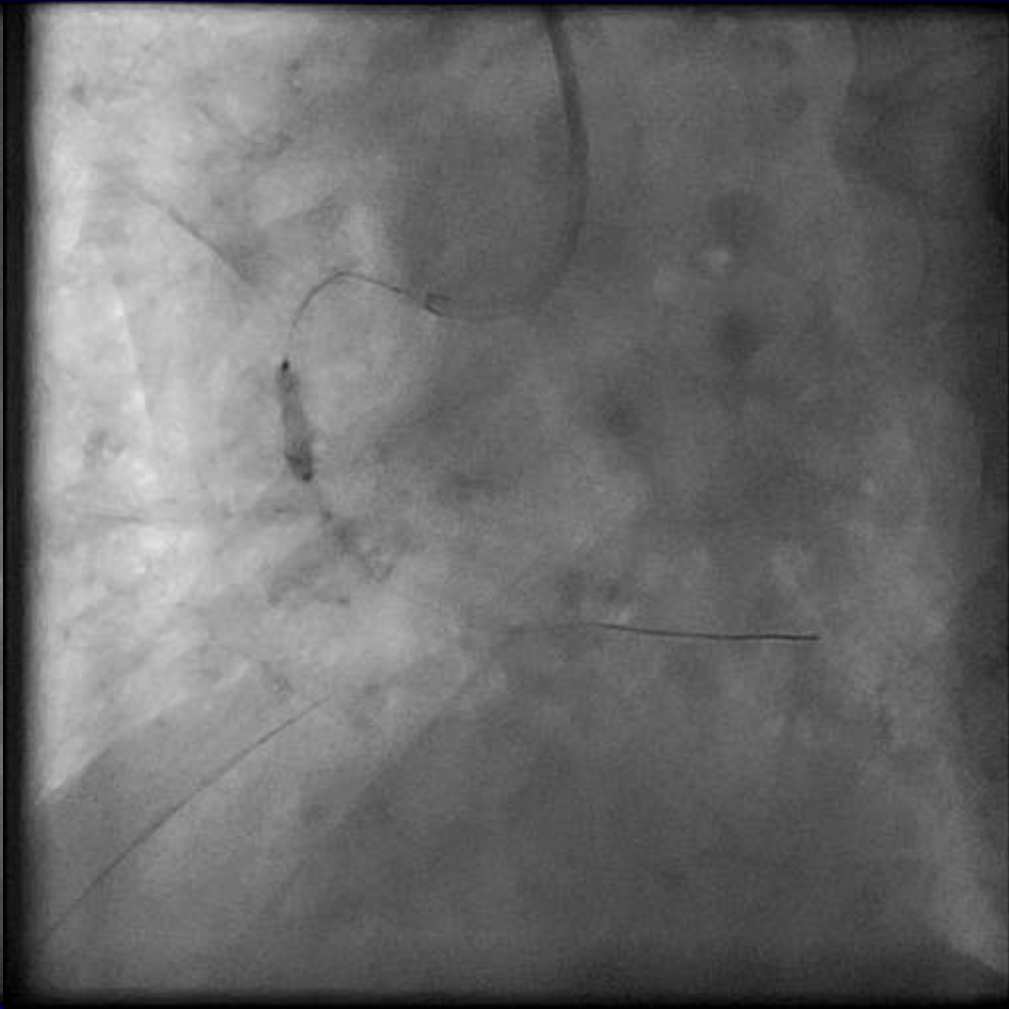
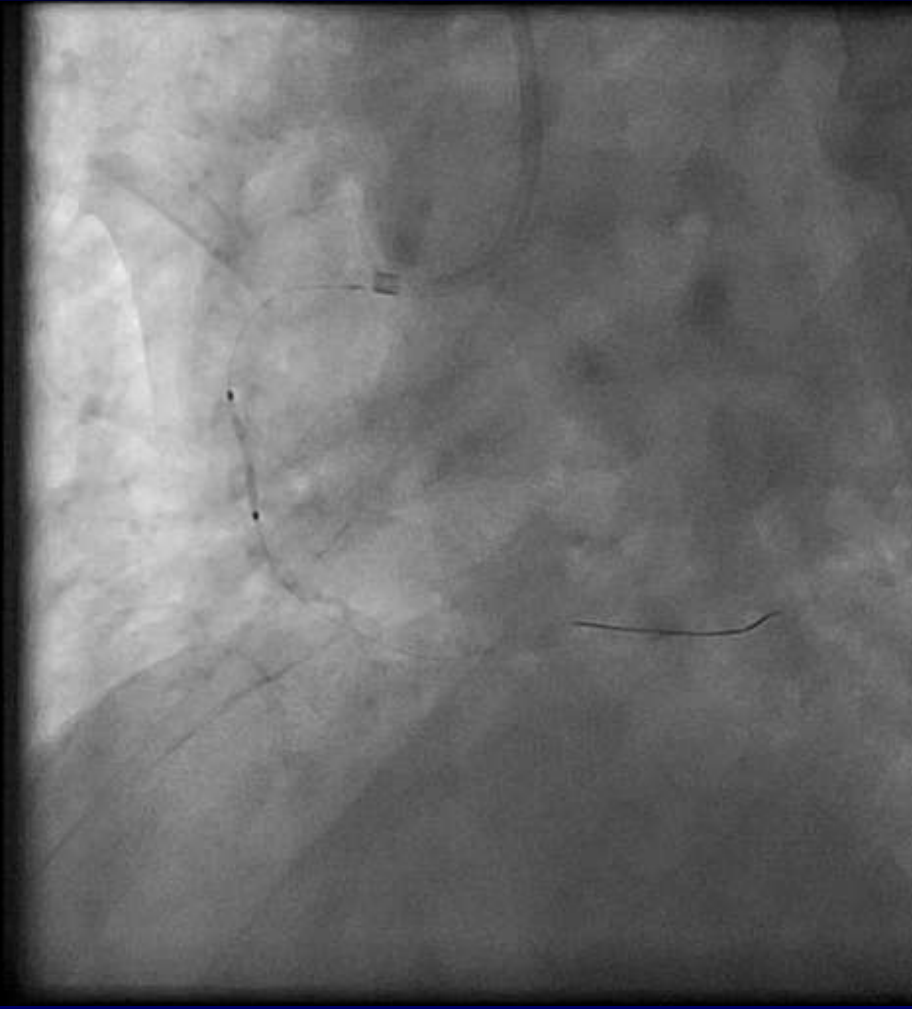




# Rotablator couldn't pass!!

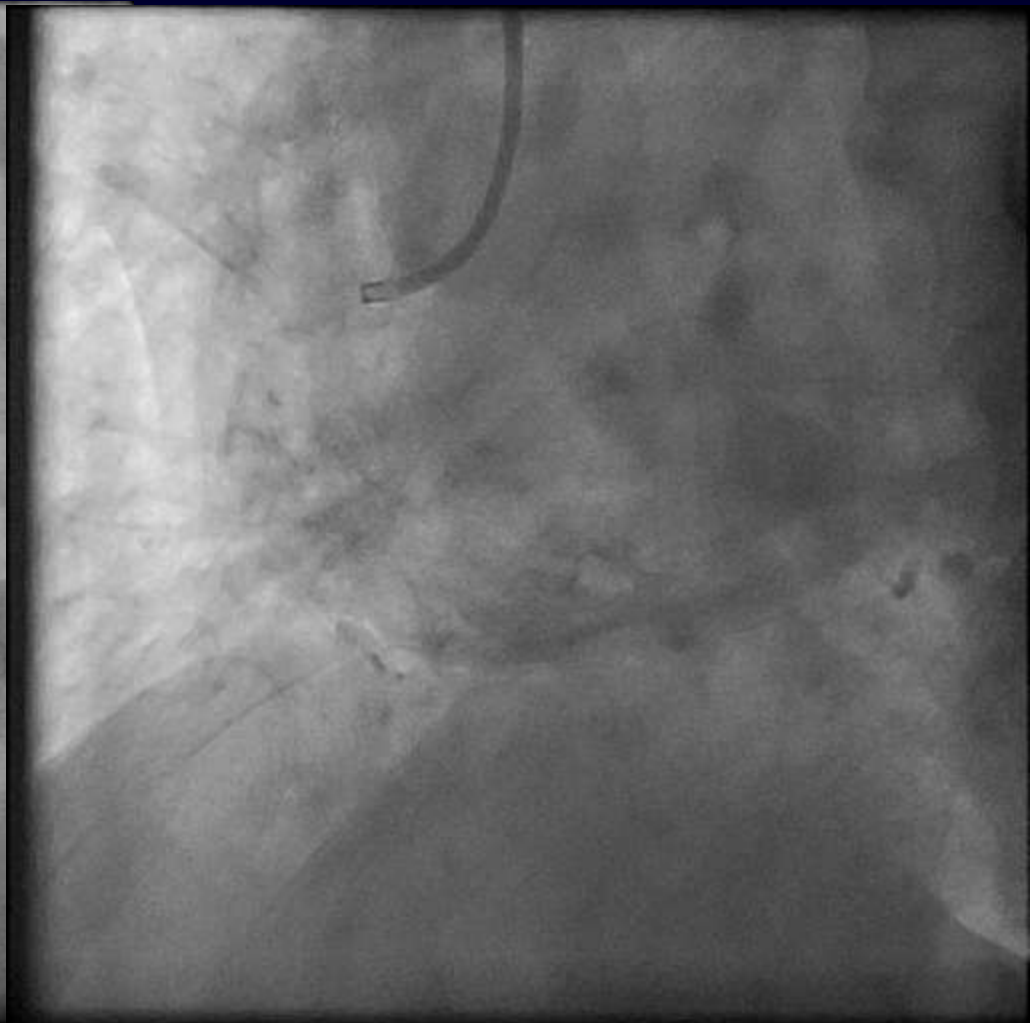
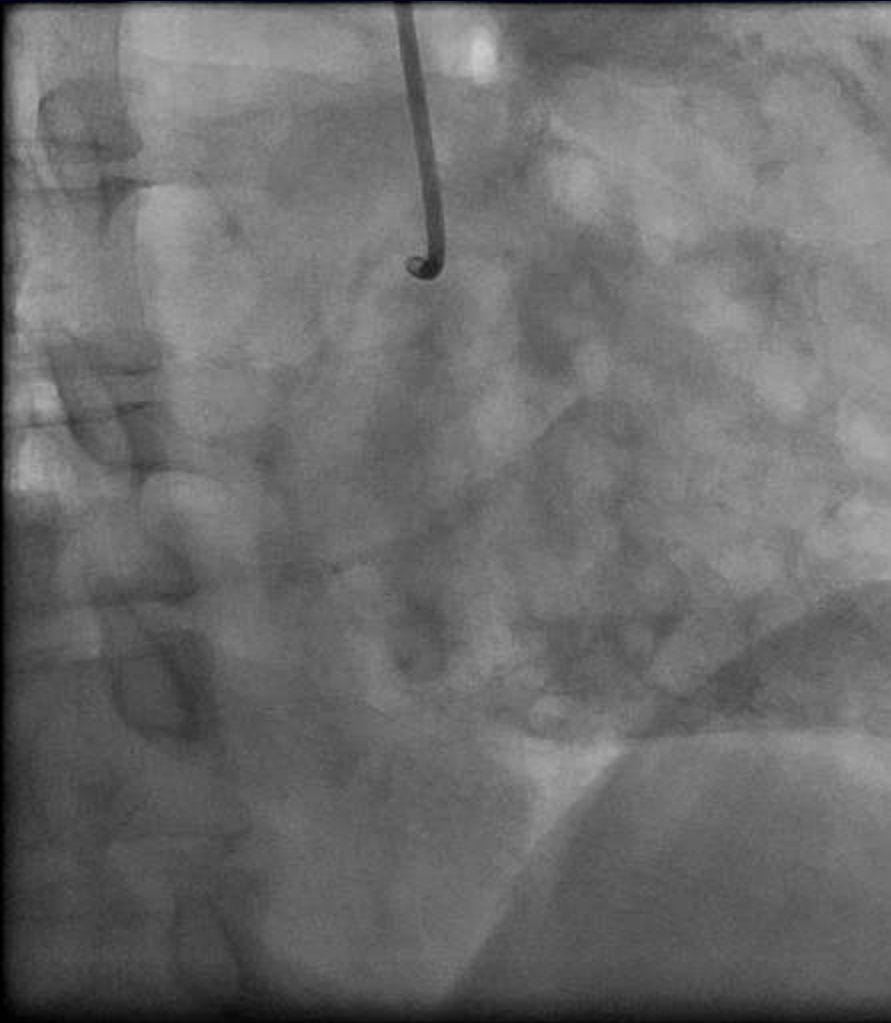


# Finally pass the lesion in RCA

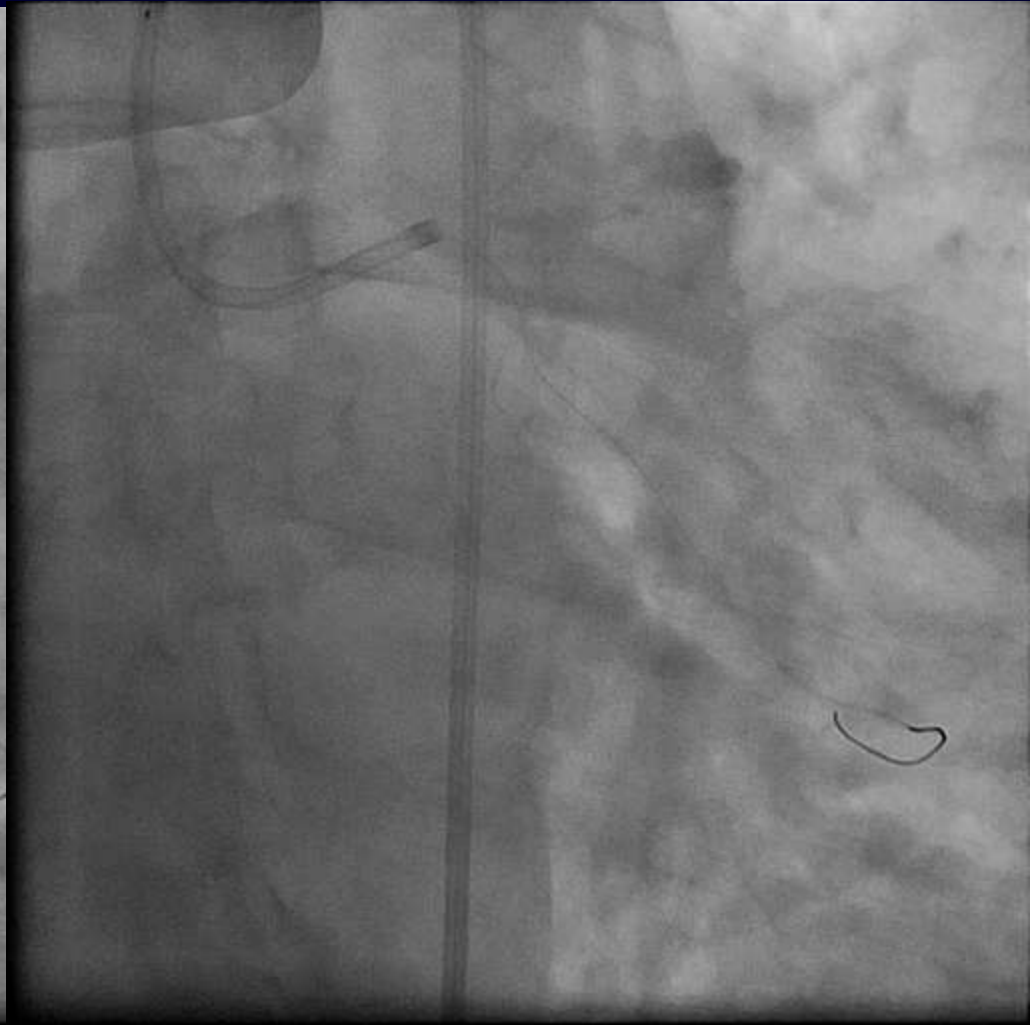
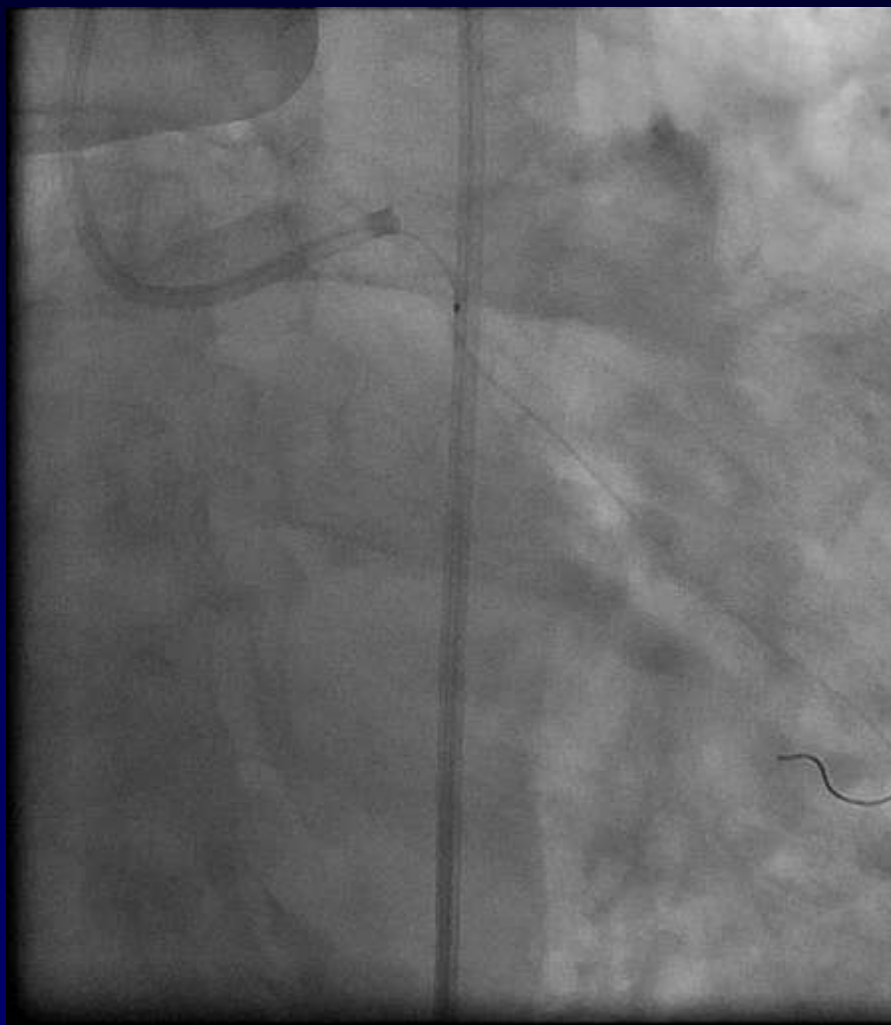




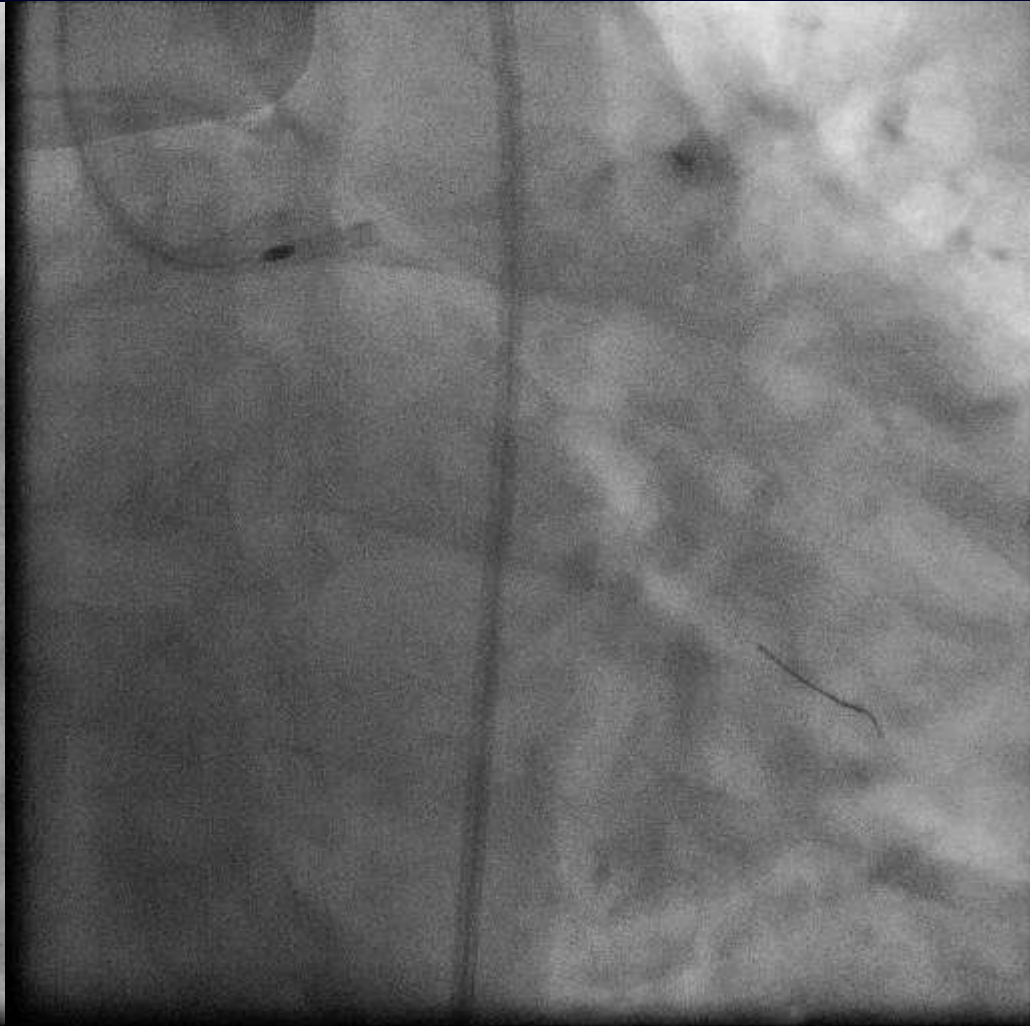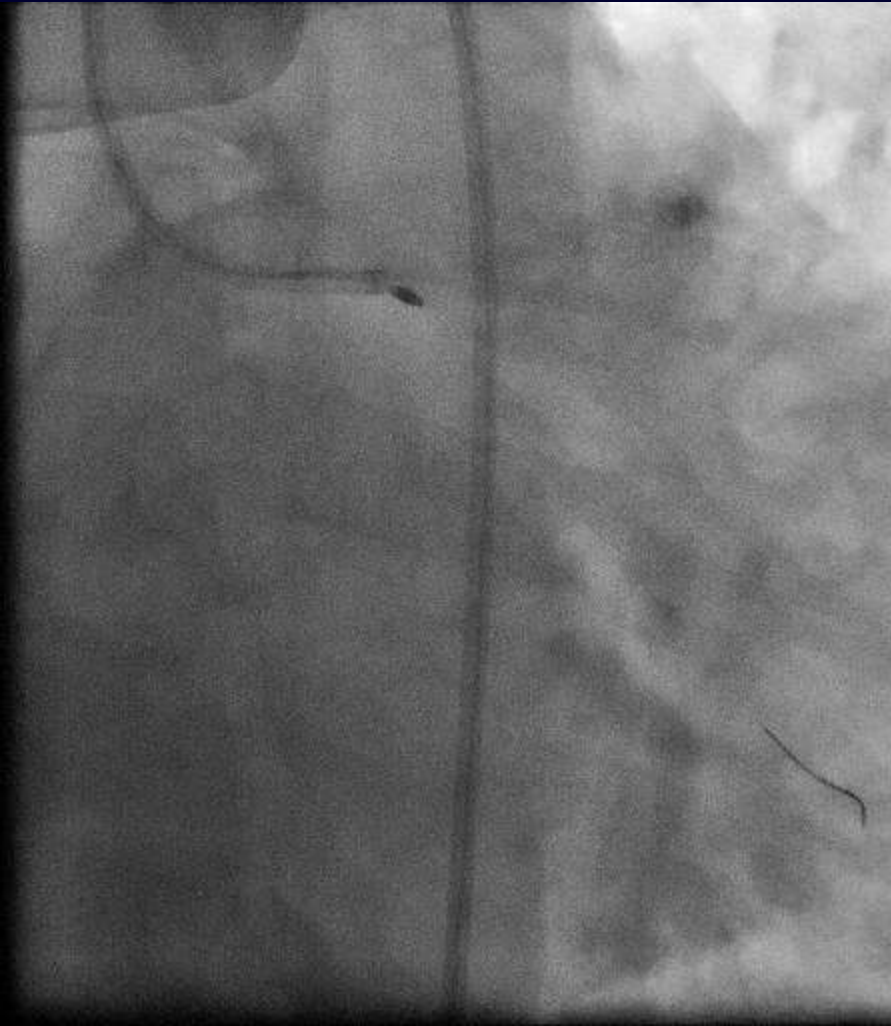
# Final results in RCA



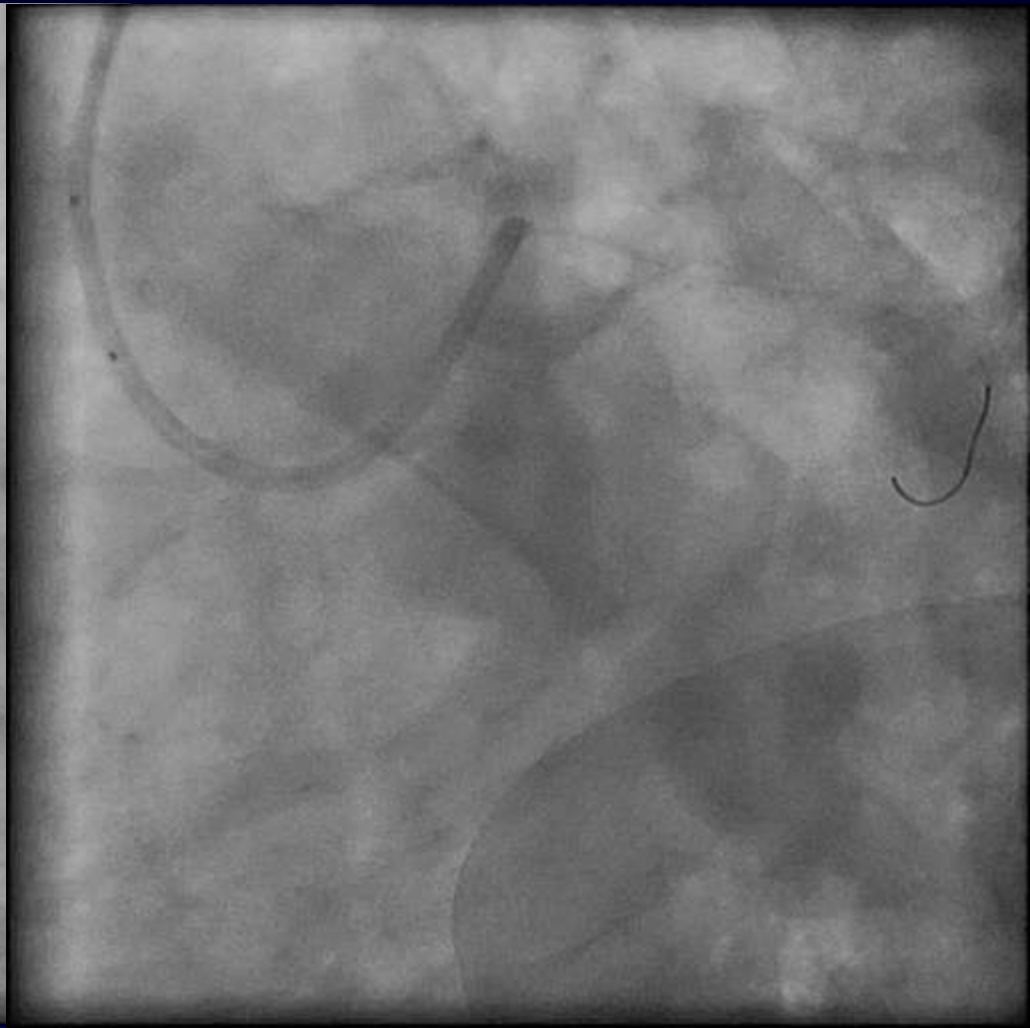
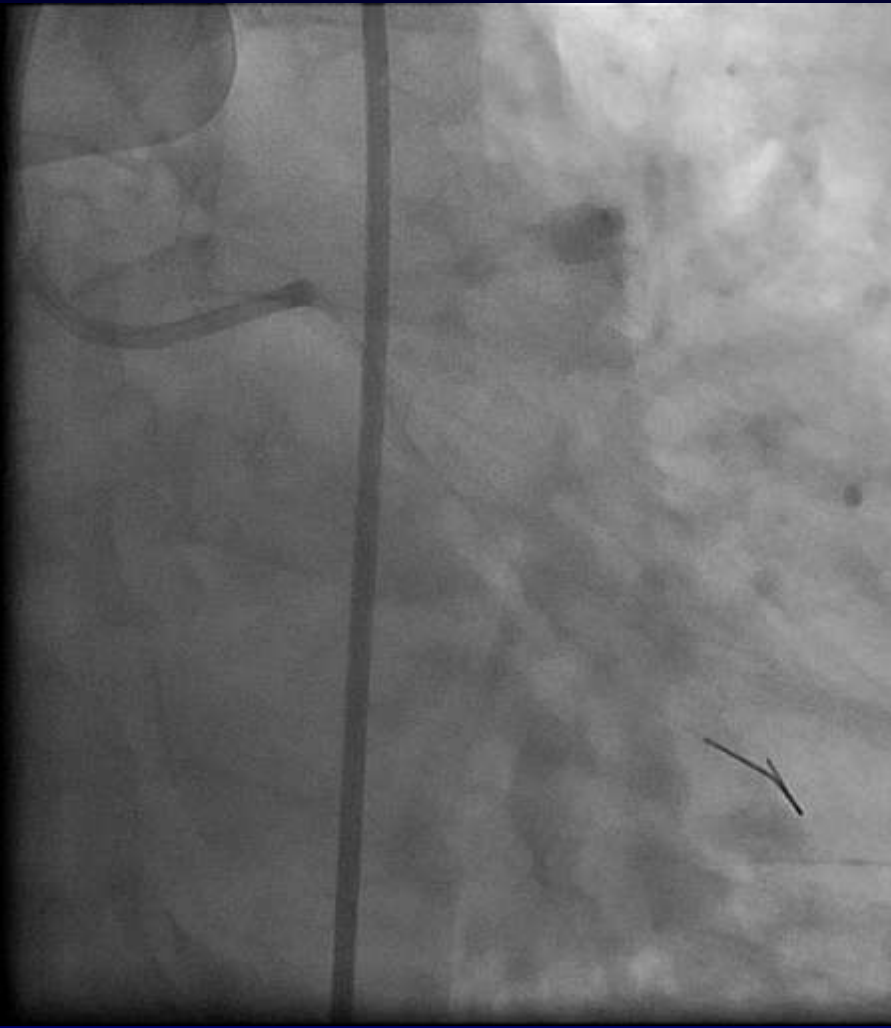# Staging for LCA PCI



# Rotablator in LCx



# Final results in LCx



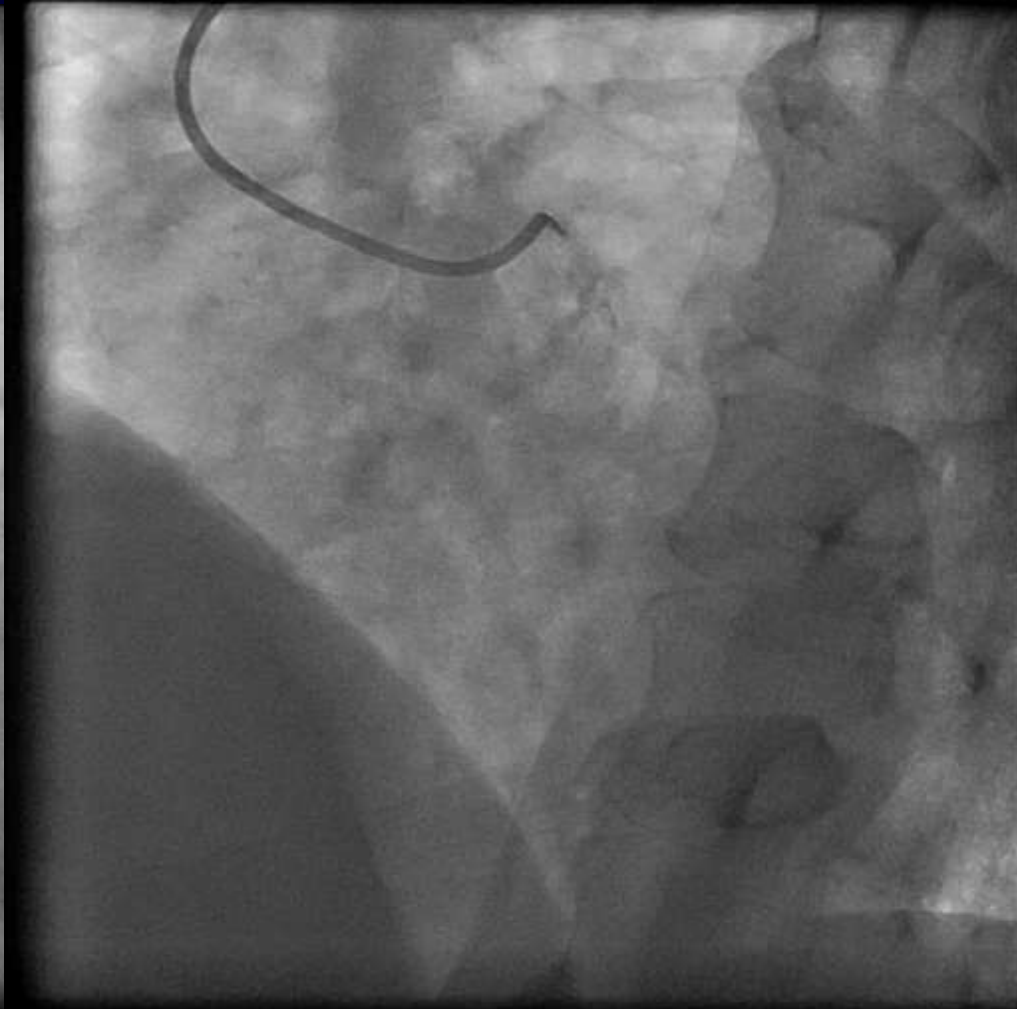
# **The Lcx was not that difficult!!**

## **What will you do for LAD?**

- A. LIMA graft to LAD
- B. PCI in LAD ( rotablator?)
- C. Aggressive medical treatment
- D. Others

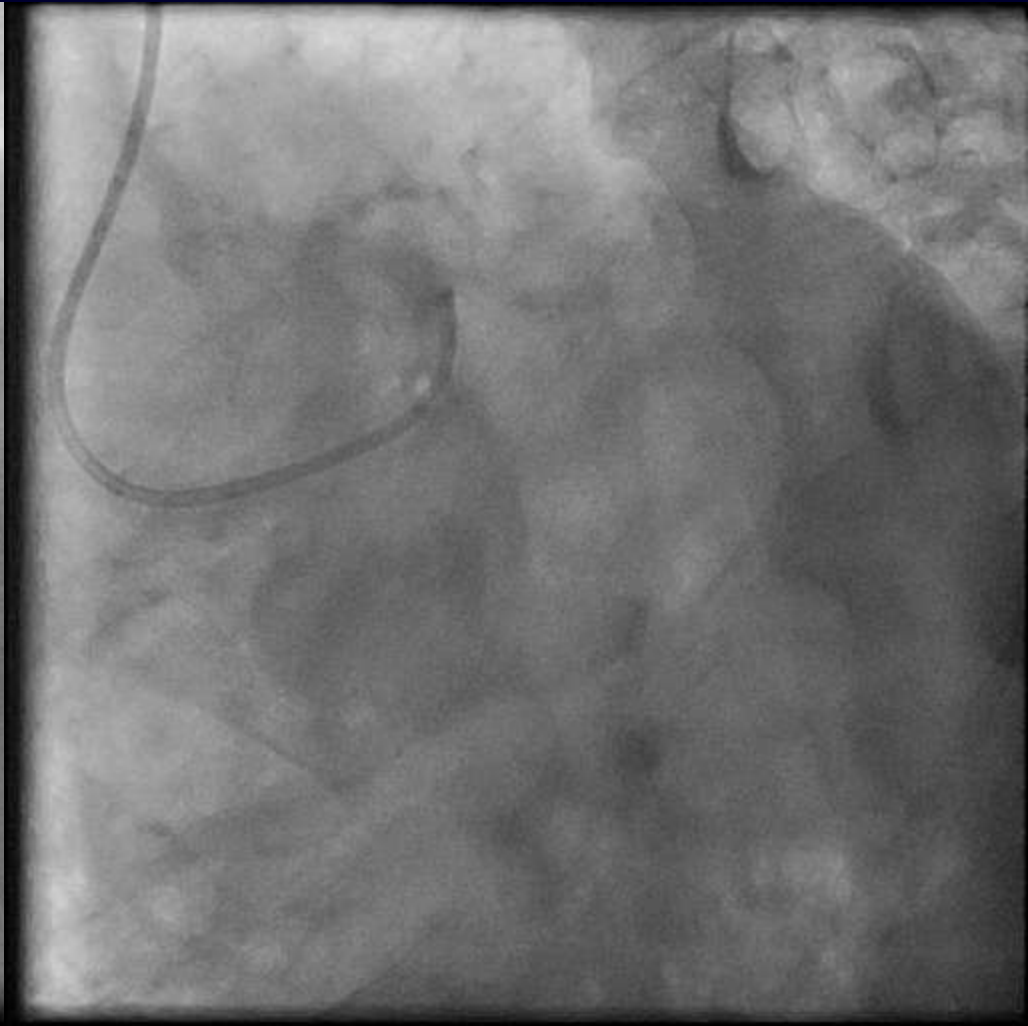
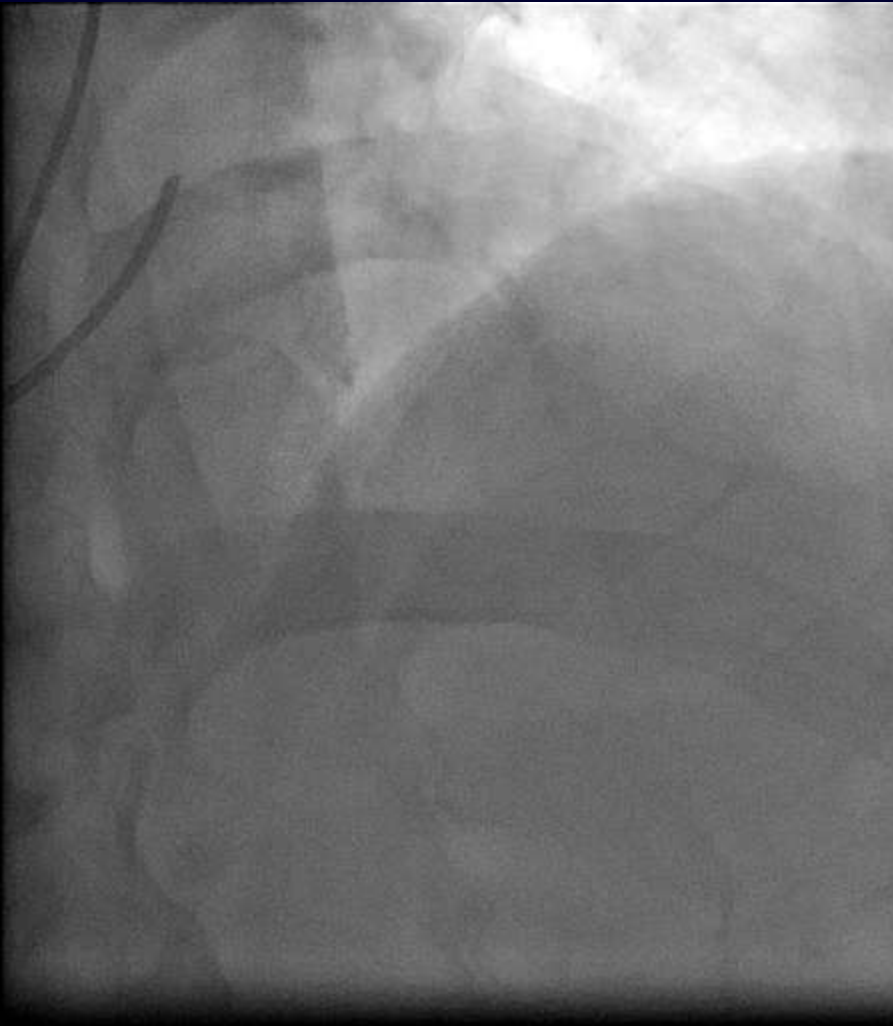

# LCA

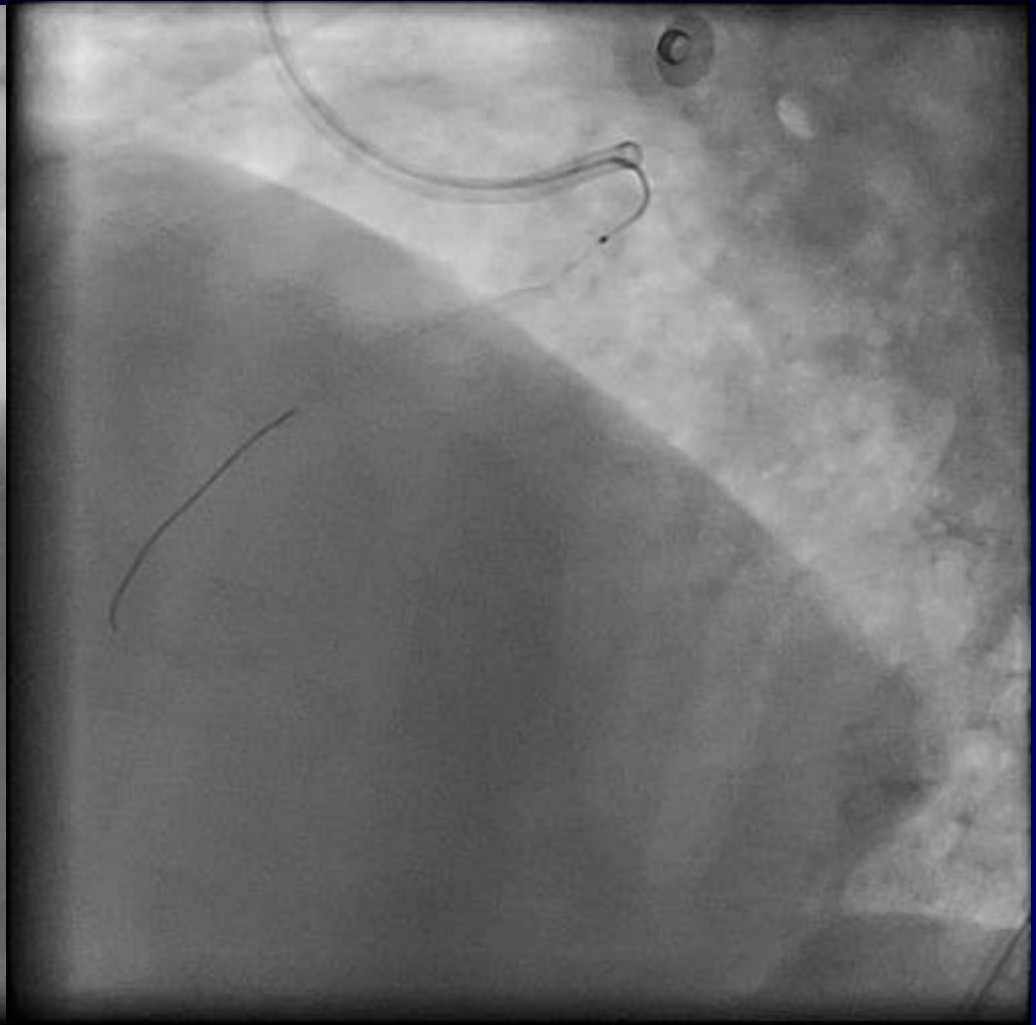
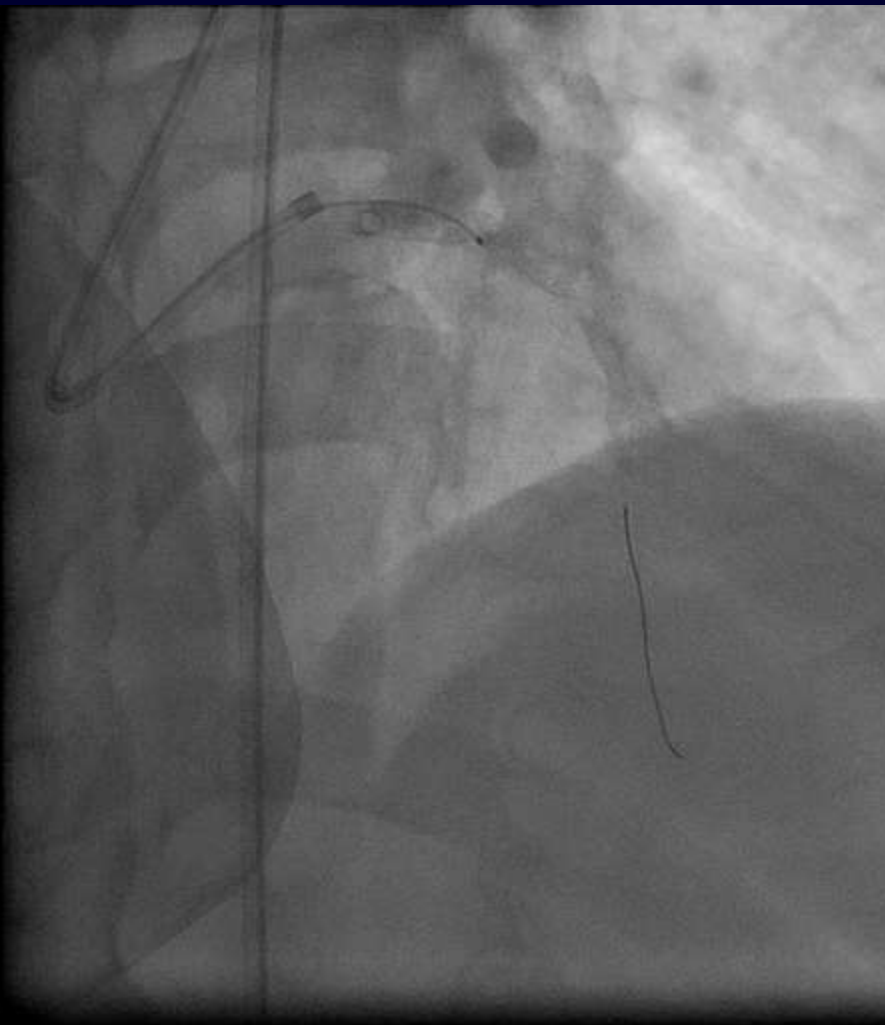




# LCA



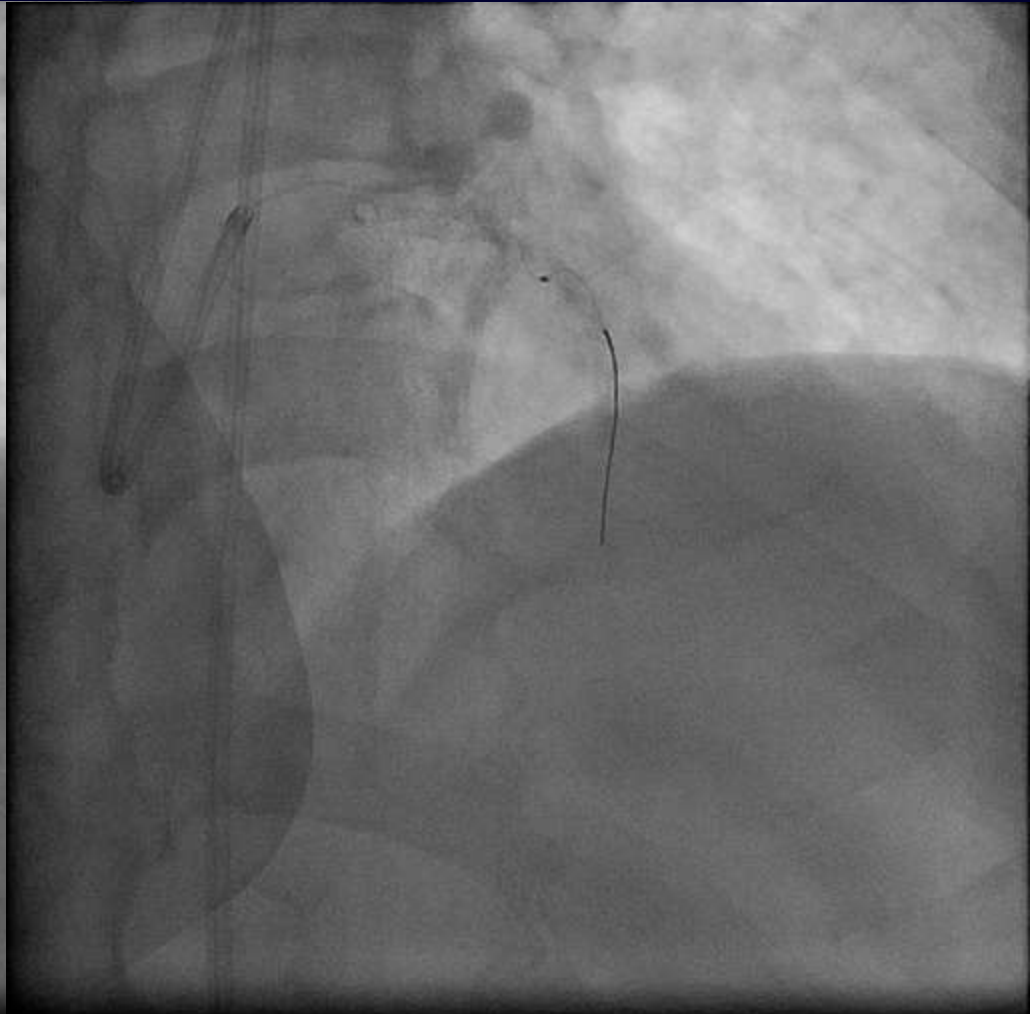
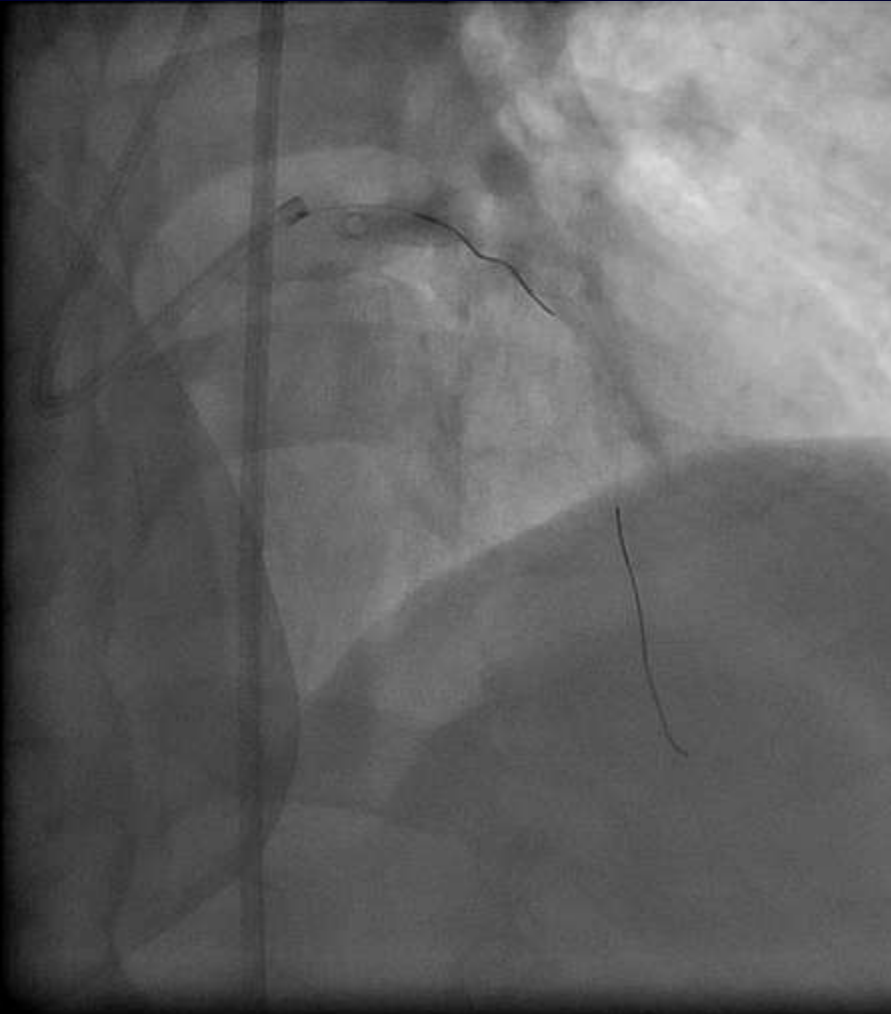
# Wiring LAD



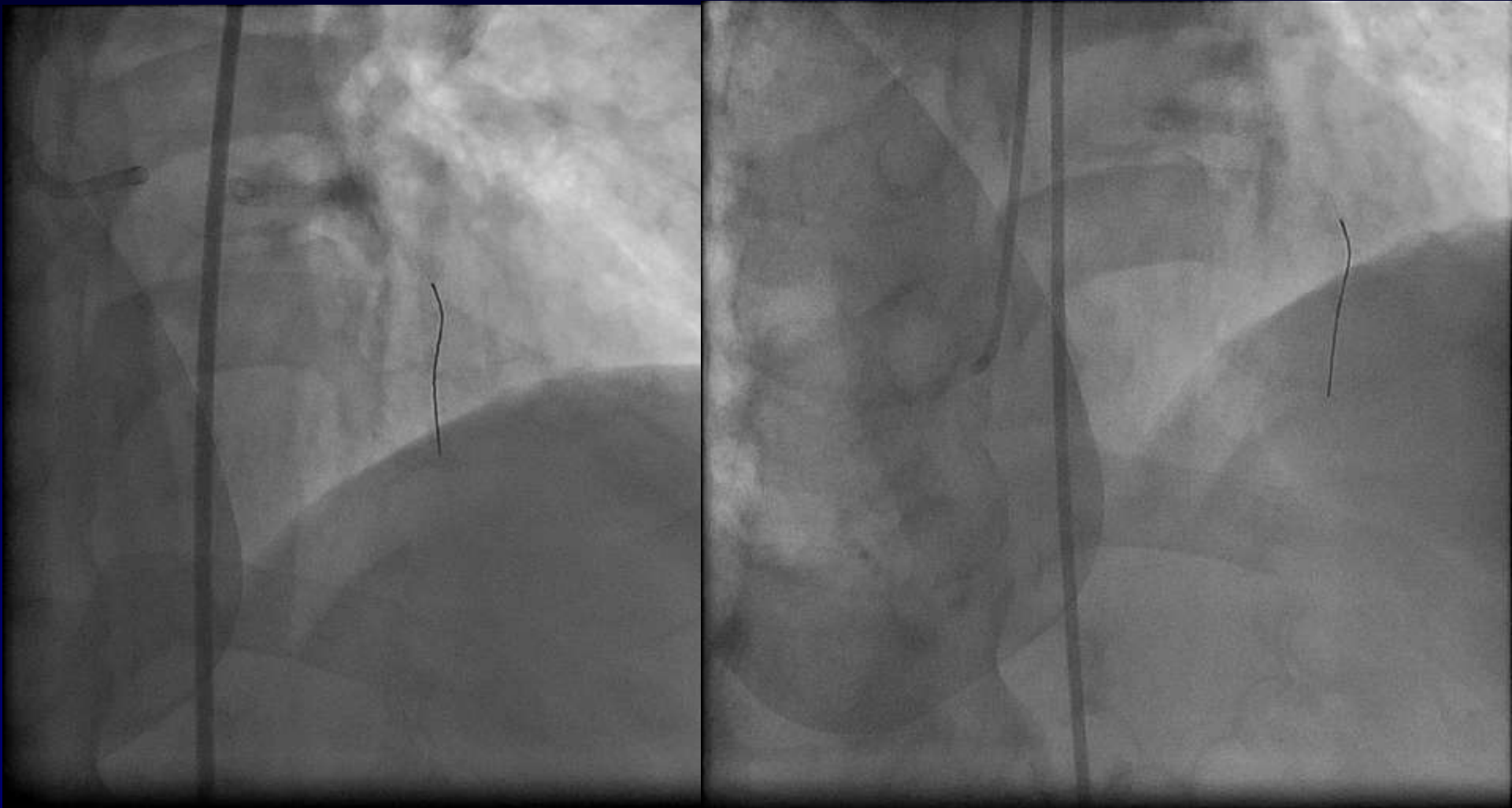
# **The LAD wire couldn't progress!! What will you do for LAD?**

- A. Remove the wire
- B. Try small balloon
- C. Exchange to rotator wire
- D. Others

# Couldn't remove the wire!!



# Final results



# What will you do next?

1. CABG
2. Try PCI again with Laser
3. Refer for PCI
4. Others



# Last Choice..



© KURT JONES 2003